

Pediatric optic ner-glioma: A case study

Prasuna Jelly^{1,*}, SK Mohana Sundari²

¹AIIMS, Rishikesh, Uttarakhand, ²AIIMS, Jodhpur, Rajasthan

*Corresponding Author:

Email: prasunajelly@gmail.com

Abstract

An **optic nerve glioma** is a type of brain tumor. There are multiple kinds with brain tumors and glioma's account for approximately one-third of brain tumors. They are **typically named after the kind** of cells they affect. It is a rare kind of cancer, they are considered low-grade and do not grow as quickly as other types of brain tumors. They are found in the optic chiasm, where the optic nerves cross or **surround** the optic nerves. They are also referred to as optic glioma or juvenile pilocytic astrocytoma. It is rarely found in individuals over the age of 20. It has also been associated with the genetic disorder neurofibromatosis Type 1, or NF1. Evidence suggests that adult malignant gliomas (glioblastoma) are rare & almost always occur in adult males with a very poor prognosis & almost certain death within one year. Optic-nerve gliomas comprise about 1% of all intracranial tumors and Optic nerve glioma is a slow-growing tumours, which typically affects children. 30% of patients have associated neurofibromatosis type 1 & those have better prognosis. However, optic nerve glioma of children is discussed in this article.

Keywords: Optic nerve glioma, Juvenile pilocytic astrocytoma, Brain tumors, Malignant glioma (glioblastoma) and intracranial tumors.

Access this article online

Website:

www.innovativepublication.com

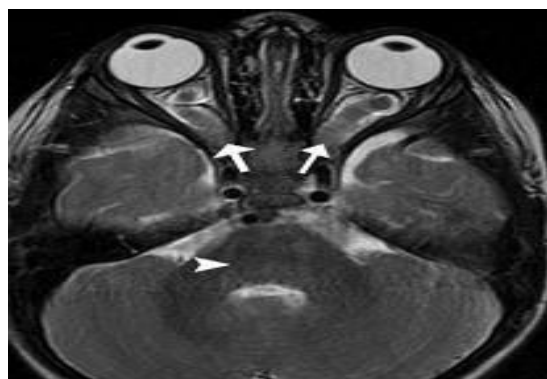
DOI:

10.5958/2455-6793.2016.00022.5

underwent MRI and the child was diagnosed as brain tumor with other supportive investigations. The child underwent craniotomy and excision on 3rd march 2016 and the tumor was removed and culture was sent for histopathological examination. The incision was made from frontal area till the right ear, 13 sutures was made to close the incision. Based on the report of histopathological examination the diagnosis was conformed as **Optic Nerve Glioma**. Postoperatively the child's general condition was fair and was complaining of diarrhea and head ache.

Introduction

A 7½ year old male child was admitted in the Peadiatric surgical ward on 12/02/2016 with the complaints of diminished vision from past 6 months and moderate to severe frontal head ache with one episode of vomiting. The child was apparently normal before 6 months, and his visual alteration was reported by his school teacher that he is unable to read words on blackboard. He went for routine eye checkup and suggested for improving diet and no other treatment measures were used. The symptoms progress and the child vision worsen with which he started banging on walls and doors. Due to progressive diminishing of vision made his parents to take him to ophthalmologic checkup twice and he was referred to tertiary care centre. Therefore the client came to AIIMS OPD with the above complaints for further treatment. There he

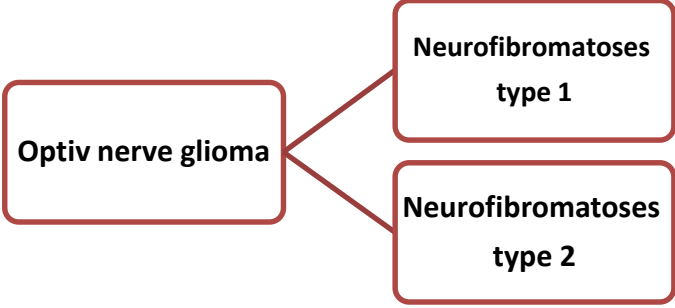
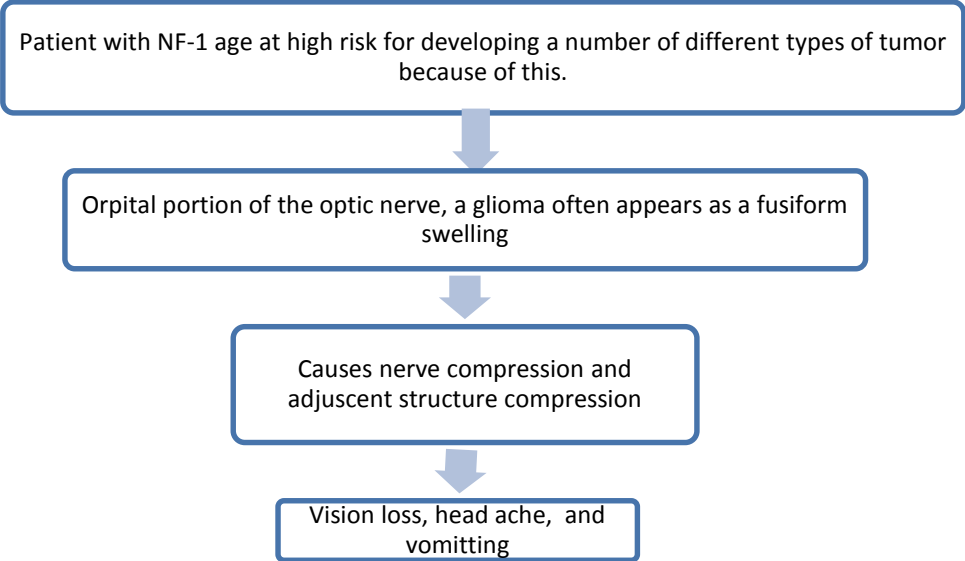



Back Ground: Optic Glioma

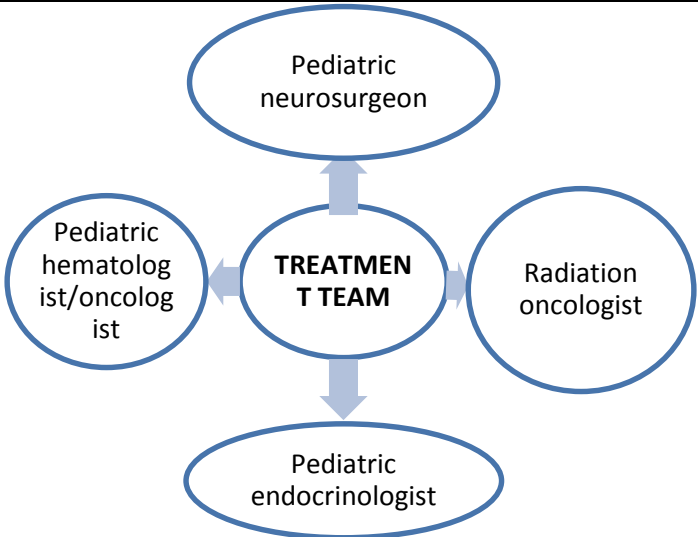
According to Literature

Definition: An optic nerve glioma (also called an optic pathway glioma) is a slow-growing brain tumor that arises in or around the optic nerve, which connects the eye to the brain. As the tumor progresses, it presses on the optic nerve, causing a child's vision to worsen. Blindness can occur, but only in about 5 percent of cases. The tumor sometimes produces additional symptoms as it grows. A low-grade form of this neoplasm, benign optic glioma, occurs most often in pediatric patients. While these are serious tumors, they have a high cure rate.

Patient Presentation

<p>Incidence:</p> <ul style="list-style-type: none"> • Peak incidence occurs in individuals aged 6-7years. • Prevalence of 15% (range, 1.5–24%) • benign optic glioma occur almost in children, better prognosis • Aggressive glioma occurs almost in adult, poor prognosis. • Genetic disorder neurofibromatosis Type 1, or NF1is commonest type in children. 	<p>Age 7 ½ years Sex: male Race: Asian</p>
<div style="text-align: center;">  </div> <p>Types</p>	<p>The child’s condition was classified as Neuro-fibromatoses type 1 after numerous diagnostics procedures.</p>
<p>Causes: Exact cause is Unknown Chromosomal abnormalities / hereditary genetic disorder, Environmental or infectious causes can predispose.</p>	<p>Similar to the literature information, present case also did not depict any causative factor.</p>
<p>Pathology:</p> <div style="border: 1px solid blue; padding: 5px; margin-bottom: 10px;"> <p>The NF-1 product, neurofibromin has GTPase-activating protein domain with the Ras protein, which is crucial in regulating signal transduction and cell proliferation and differentiation.</p> </div> <div style="text-align: center;">  </div>	
<p>Clinical manifestations</p> <ul style="list-style-type: none"> • Headache: due to increased intracranial pressure or hydrocephalus. • Nausea and Vomiting: Classic projectile vomiting (frequently without nausea) • Vision loss <ul style="list-style-type: none"> ○ Children are frequently unaware of significant vision loss; nevertheless, this symptom reportedly occurs in 20-60% of pediatric patients with craniopharyngioma at presentation. ○ Anterior extension to the optic chiasm can result in a classic bitemporal hemianopsia, unilateral temporal hemianopsia, papilledema, or unilateral/bilateral decrease in visual acuity. Classically, vision loss starts with a superior temporal field cut. However, the eccentric growth of these tumors can 	<p>Before surgery: Head ache on frontal area Vomiting Partial Vision loss (bitemporal hemianopsia) Unusual eye movement After surgery: Head ache Diarrhea</p>

<p>result in varying patterns and severity of vision loss, including decreased acuity, diplopia, blurred vision, and subjective visual field deficits. Children are frequently inattentive to visual loss, and formal testing may be required.</p> <p>Balance problem</p> <ul style="list-style-type: none"> • Seizures due to Temporal lobe involvement • Hyperactive children with unusual eye movements and even blindness due to extrinsic compression of the hypothalamus. • Endocrine deficiencies leads to short stature, Weight gain, Lethargy, Fatigue, Cold intolerance, Dry skin, Dry brittle hair, Slow teething, Anorexia, Large tongue, Deep voice, Myxedema, Delayed puberty, memory impairment, daytime sleepiness and growth delays 	
<p>Diagnosis:</p> <ul style="list-style-type: none"> • History • Physical examination with neurological exam. • Preoperative intellectual or psychological assessment. • Vision testing • Serum electrolytes levels • Hormonal studies • Skull Radiography • Head CT Scanning • Brain MRI • Cerebral Angiography • Biopsy <p>The child presented with following findings:</p> <p>History: The child natal history was apparently normal</p> <ul style="list-style-type: none"> • General appearance: Oriented, conscious, moderate body built. • GCS score: Eye 4 verbal 5, and motor 6, • Vital signs: stable • Anthropometry: height 154cm, weight 18kg, 1st degree malnutrition (according to Gomez classification). • Growth and development seems to be normal. And child was mild hyperactive and have hurried in speech. • Head to foot: surgery suture was healthy, partial visual acuity. Unusual eye movement, pupillary dilatation, partial optic atrophy. Extra ocular eye movement abnormalities. Slow teething and deep voice, weight loss. • No other abnormal physical finding findings. <p>Investigations:</p> <ul style="list-style-type: none"> • Haematological investigation: Hb: 11.3gm/dl, RBC 4.56mc/cum, TLC 7500cells/cumm, DLC-N 90%,E-01%, L-05%, m-04%, platelet – 3.11 lacks/c/cumm, Hematocrit 34.8%. • Hormonal studies: T3 level is elevated. • MRI: suggestive of possibilities of Craniopharyngiomas. • Histo-pathological examination: suggestive of optic nerve glioma 	
<p>Treatment:</p> <p>A treatment plan must be carefully individualized for each patient. This need consultation and team work.</p>	<p>Management:</p> <p>Child was under continuous observation with possible supportive therapy to the family.</p> <p>Medical management</p> <p>He was on continuous medication till he undergo surgical management.</p> <p>Tab valporate 200mg OD (morning) Tab veona CR 300 mg OD (evening) Tab pantop -20mg OD Tab sporlac 120mg TDS</p> <ul style="list-style-type: none"> • Surgical management <p>Craniotomy and excision was done. Postoperatively the child was doing</p>

 <ul style="list-style-type: none"> • Observation only in presumed optic nerve glioma, particularly with good vision on the involved side; with careful follow up if the radiographic evidence. • Long-term hormone replacement is the primary medical treatment: intranasal vasopressin (desmopressin acetate [DDAVP]), corticosteroids, thyroid hormones, growth hormones, and sex hormones. • Combination chemotherapy using actinomycin D, vincristine, etoposide, bevacizumab and other agents has also been reported to be effective in patients with progressive chiasmal/hypothalamic gliomas to shrink the tumor and stabilize vision. • Radiation therapy as the sole treatment is considered if the tumor cannot be resected (usually chiasmal or optic tract lesions) and if symptoms (particularly neurological) progress or if the tumor is resistant to chemotherapy • Alternative medicine -(acupuncture/acupressure, therapeutic touch, herbal medicine, etc.) to control pain and treatment side effect. • Surgical Care-Surgery is usually not preferred for this type of tumor, but can sometimes relieve symptoms and/or improve vision. Surgical excision in case of rapid intra-orbital tumor growth to isolate the tumor from the optic chiasm and thus prevent chiasmal invasion. The surgeon should use an intracranial approach to obtain tumor-free surgical margins. • Radical surgery • Conservative surgery alone • Conservative surgery with postoperative radiotherapy 	<p>well and had satisfactory general condition. No post-operative radiotherapy was given to the child.</p>
<p>Complications:</p> <ul style="list-style-type: none"> • Hormonal deficiency • Cognitive difficulties, • learning disabilities, and • impairments in growth 	<ul style="list-style-type: none"> • TSH deficiency • Diencephalic syndrome (hyperactive with unusual eye movements)
<p>Prognosis and recurrence</p> <ul style="list-style-type: none"> • Variable • Optic nerve glioma recurrence may take place many years after initial treatment. • It usually recurs in the same place as the original tumor, but can also occur in other parts of the brain or spinal cord. • Local radiation therapy is the usual treatment if the patient has not previously been treated with this modality. 	<p>After one month of hospitalization, the child was discharged with minimal deficit in activities of daily living. The child was progressed positively according to the expectations. Supportive treatment and therapies have been provided. The child</p>

<ul style="list-style-type: none"> • Chemotherapy and radiation therapy are options for patients who have only been treated surgically. • Child with NF-I tend to fare better with respect to growth and visual prognosis. • Most tumor grows slowly or having self-limited growth. • Some tumors are more aggressive, resulting in a rapid increase in isplateral ptosis and visual loss. 	<p>recovered completely and was discharged after one month of surgery. He was advised for regular OPD checkups without fail.</p>
--	--

Special consideration

- Identification of risk factors for exposure to radiation or chemicals that is carcinogenic.
- Identify the signs and symptoms are: headache, vomiting, and decreased vision or double vision.
- Identify any changes in client behaviour.
- Observation of hemiparese or hemiplegia.
- Changes in sensation: hyperesthesia, parasthesia.
- Observation of sensory changes: asteregnosis (not able to feel the sharp edges), agnosia (not able to recognize objects in general), apraxia (not being able to use the tool properly), agraphia (can't write).
- Observation of vital signs and level of consciousness.
- Observation circumstances fluid and electrolyte balance.
- Psychosocial: personality and behavioural changes, difficulty making decisions, anxiety and fear of hospitalization, diagnostic tests and surgical procedures, a change in the role.

7. Hwang J, Cheon J, Wang K. Visual prognosis of optic glioma. Childs Nerv Syst (2008) 24:693–698
8. Wilhelm H. Primary optic nerve tumors. Current Opinion in Neurology 2009,22:11–18.
9. Suraj G “The Short Textbook of Paediatric Nursing” 11th edition, Jaypee publications, 565-566.

Conclusion

Having cancer as a child can be socially and emotionally stressful. You or your child may benefit from counseling or a support group. Being around peers his or her own age can be a big support. The survival rate for optic pathway gliomas is near 90 percent. Older children and those with neurofibromatosis 1 have better outcomes. In fact, two-thirds of children with NF1 experience spontaneous remission of their optic pathway gliomas. Children may suffer a smaller field of vision, which means they do not have peripheral vision. The odds of complete blindness from these tumors, however, are less than 5 percent. As there is chance of recurrence after treatment, follow-up visits with doctor are necessary to check for any side effects and ensure the cancer has not returned.

Reference

1. Nelson, “Textbook of Paediatrics” 10th edition, volume 1, Elsevier publication, 1746,1752.
2. Karin R, Beth B “Paediatric Acute Care” Jones and Bartlett publication, 375, 637.
3. Nanda nursing interventions
4. Jack J Kanski, Brad Bowling. Clinical Ophthalmology: A systemic approach. 7th ed. Elsevier Saunders; 2011.
5. Archar’s “Textbook of Paediatric Nursing” 4th edition, universities press, 534,541,543
6. Orbit, Eyelids and Lacrimal System, Section 7. Basic and Clinical Science Course, AAO, 2011-2012.