

Study of early refractive changes following Nd: YAG capsulotomy for posterior capsule opacification in pseudophakia

Sandhya Ramachandra¹, Fijo Kuriakose^{2,*}

¹Professor & HOD, ²Junior Resident, Dept. of Ophthalmology, Sri Siddhartha University, Karnataka

*Corresponding Author:

Email: fijo669@gmail.com

Abstract

Purpose: To study the effect of capsulotomy size on refraction and best corrected visual acuity (BCVA).

Methods: Thirty five patients were examined pre procedure and 3 days after Nd: YAG capsulotomy. Patients were divided into 3 groups based on post procedure capsulotomy size. Changes in cylindrical error, spherical error & BCVA were compared in 3 groups.

Results: We found a higher hyperopic shift in patients belonging to larger capsulotomy group. In 3 groups the change in cylindrical error was found to be significant in the larger capsulotomy group. The change in BCVA pre & post procedure was also found to be significant among the 3 groups.

Conclusion: Patients who underwent a larger capsulotomy had a higher hyperopic shift and improvement in vision. The cylindrical correction changed significantly depending on the size of the opening created.

Keywords: Nd: YAG laser, Capsule opacification, Posterior capsulotomy, Intraocular lens, Visual acuity and Diopters

Access this article online

Website:

www.innovativepublication.com

DOI:

10.5958/2395-1451.2016.00048.2

Introduction

Posterior capsule opacification (PCO) is a common complication of extracapsular cataract extraction with or without posterior chamber intraocular lens (PC-IOL) implantation⁽¹⁾. Incidence of PCO were 11.8% at 1 year, 20.7% at 3 years, and 28.4% at 5 years after surgery⁽²⁾. PCO can cause a reduction in visual acuity and contrast sensitivity, as well as glare and monocular diplopia⁽³⁻⁶⁾. The proliferation, migration and abnormal differentiation of residual lens epithelial cells and fibers in capsular bag have been implicated in the pathogenesis of PCO⁽⁷⁾. In recent times, the incidence of PCO has shown a significant decline due to the introduction of sharp edge optic intraocular lenses (IOL) and the development of modern phacoemulsification technique⁽⁷⁻⁹⁾. However, PCO is the most common delayed complication of cataract surgery⁽¹⁰⁾.

Yttrium Aluminum Garnett (YAG) capsulotomies were developed in the early 1980s by Drs. Aron-Rosa and Fankhauser. Posterior capsulotomy using Neodymium-Doped Yttrium Aluminum Garnett (Nd:YAG) laser is a relatively noninvasive procedure that is used in the treatment of posterior capsular opacification. Laser capsulotomy uses a quick-pulsed Nd:YAG laser to apply a series of focal ablations in the posterior capsule and create a small circular opening in the visual axis⁽⁶⁾.

Even though the procedure is safe, occasional serious complications such as retinal detachment^(11,12,13), cystoid macular edema^(13,14) and rise in intraocular pressure^(15,16) tend to occur after Nd: YAG laser capsulotomy. Optical and mechanical factors should be considered for the optimal size of posterior capsulotomy. Optical factors include diffraction, reduced image sensitivity and glare. Optical consideration favors large capsulotomy. Mechanical consideration are based on barrier effect of the intact posterior capsule and favors small capsulotomy. Holladay. et. al concluded that optimal capsulotomy should be equal or exceed the diameter of the pupil in the scotopic conditions and remain within the border of IOL. The typical scotopic pupil diameter following extra capsular cataract extraction with a posterior chamber IOL varies between 3.9 mm and 5.0 mm⁽¹⁷⁾.

Optical effects of capsulotomy are often ignored during the procedure as the main intention is to remove the opaque barrier. Effect of capsulotomy size on refractive status after Nd: YAG laser procedure is controversial. Studies have shown that large capsulotomy size is associated with increased posterior movement of IOL^(18,25). A hyperopic shift may be caused by large capsulotomy size. However a study reported a refractive change of 0.38 diopter in patients with capsulotomy size smaller than 4 mm and 0.22 mm diopter in patients with capsulotomy size equal or larger than 4 mm⁽¹⁹⁾.

Patients and Methods

The study was approved by the Institutional Ethics Committee. Written consent was taken from all patients as a routine for YAG capsulotomy, with an additional information that the refractive outcome may be analyzed

and used for research purpose. Thirty five eyes in 35 consecutive patients who presented for Nd: YAG capsulotomy from June 2014 to June 2015 were included in the study.

Inclusion criteria: Posterior capsular opacification in patients with PC IOL following uncomplicated manual Small Incision Cataract surgery in 6 months or more were included. Patients who had anterior capsulorrhexis (during cataract surgery), in the bag IOL were selected. Systemic conditions like diabetes or hypertension did not form exclusion criteria.

Exclusion criteria: Abnormalities of IOL position (decentered, dislocated PC IOLS), Intra ocular inflammation and obvious capsular contracture formed the exclusion criteria. Documented evidence of any fundus pathology including macular edema also formed exclusion criteria. Cases of Glaucoma, Uveitis and high Myopia were also excluded from the study.

A complete ocular evaluation of the pseudophakic eye including Best Corrected Visual Acuity (BCVA), slit lamp, intraocular pressure and fundus with 90D were done as base line examination. All patients were carefully screened for any irregularities in anterior chamber depth using slit lamp. IOP was recorded by Goldman Applanation Tonometer. Objective refraction was measured by retinoscopy and an auto-refractometer, followed by instillation of commercially available mixture of Tropicamide 0.8% with Phenylephrine hydrochloride 5%.

Slit lamp examination was performed in 30 minutes, to achieve maximum possible pupillary dilation to assess the morphological type of PCO and position of IOL. The size of the PCO was noted using the slit lamp gauge, in millimeters. Refraction was assessed by manual retinoscopy and auto refractometer. Pre procedure spherical errors and cylindrical errors were documented. The patients underwent Nd:YAG posterior capsulotomy with minimal power setting and optimal number of shots to clear the visual axis. Following the procedure a drop of IOP lowering medication was instilled, if indicated. The capsulotomy size was assessed using slit lamp gauge. Then they were prescribed a topical NSAID drops three times for 3 days. The usual post procedure instructions were given and asked to come for follow up after 3 days.

All patients were evaluated 3 days after the procedure (day 4) which included BCVA and slit lamp examination. The size of the capsulotomy was measured by slit lamp, under mydriasis and classified in to 3 groups (2-3mm, 3mm and 4mm). Patients underwent retinoscopy and auto-refractometry. Then subjective refraction was performed and readings were documented. Patients who failed to achieve an improvement of minimum 1 line of BCVA were further evaluated for other causes of vision loss (Fig. 1 & Table 8). The changes in refraction were noted and analyzed. Spherical and cylindrical error shift post procedure were determined.

SPSS, software was used for statistical analysis. Wilcoxon signed rank test was used to compare two groups (pre and post procedure groups) based on spherical equivalent and BCVA (Table 6). One way analysis of variance (ANOVA) was used to determine the significance of spherical shift, cylindrical shift, BCVA and spherical equivalent (SE) among the 3 groups (Table 7).

Results

In 35 patients included in the study the mean age was 62 years. Overall in the study 60% of the patients were male and 40% were females (Table 1). Most of the patients belongs (45%) to age group of 61 to 70 years followed by 22% patients in 51-60 years of age (Table 1a). Elschnig's Pearl morphology was found in majority (74%) of patients (Table 2).

Table 1: Sex wise distribution

Gender	No. of Patients	%
Male	21	60 [†]
Female	14	40

Table 1a: Age wise distribution

Age in years	No. of patients	%
<40	1	2.85
41-50	4	11.42
51-60	8	22.85
61-70	16	45.71 [†]
71-80	6	17.14

Table 2: Morphological Type PCO

PCO Morphology	No. of patients	%
Membranous	5	14.29
Elschnig's pearls	26	74.28 [†]
Soemmering's Ring	4	11.43

Table 3: Visual acuity at presentation

Visual Acuity on Snellen's Chart	No. of Patients	%
1/60- 3/60	5	14.28
4/60- 6/60	4	11.43
6/36- 6/18	22 [†]	62.85
6/12- 6/6	4	11.44

Table 3a: Visual acuity post procedure

Visual Acuity on Snellen's Chart	No. of Patients	%
1/60- 3/60	1	2.85
4/60- 6/60	5	14.29
6/36- 6/18	8	22.86
6/12- 6/6	21 [†]	60

Table 4: Cylindrical refractive error at presentation

Cylindrical error (Diopters)	No. of Patients	%
-0.25 to -1.00	8	22.86
-1.25 to -2.00	14 [†]	40
-2.25 to -3.00	7	20
-3.25 to -4.00	3	8.57
-4.25 to -5.00	3	8.57

Table 5: Cylindrical error post procedure

Cylindrical error (Diopters)	No. of Patients	%
-0.25 to -1.00	10	28.57
-1.25 to -2.00	11 [†]	31.43
-2.25 to -3.00	11 [†]	31.43
-3.25 to -4.00	3	8.57
-4.25 to -5.00	0	0

Table 4a: Spherical refractive error at presentation

Spherical Error (Diopters)	Number of Patients	%
+ 2.25 to + 3.00	3	8.57
+1.25 to + 2.00	12 [†]	34.28
+0.25 to +1.00	7	20
-0.25 to -1.00	10	28.57
-1.25 to -2.00	1	2.86
-2.25 to -3.00	2	5.72

Table 5a: Spherical error post-procedure

Spherical Error (Diopters)	No. of patients	%
+ 2.25 to + 3.00	3	5.71
+1.25 to + 2.00	7	20
+0.25 to +1.00	13 [†]	37.14
-0.25 to -1.00	8	22.87
-1.25 to -2.00	2	5.71
-2.25 to -3.00	2	5.71

[†]Majority in the group

Table 6: Pre & Post-procedure values of spherical equivalent & BCVA

	Pre procedure		Post procedure (Day4)		P value
	Mean	SD	Mean	SD	
Spherical equivalent (SE)	0.76	1.3	0.55	1.22	0.15
BCVA (Logmar)	0.77	0.4	0.47	0.38	<0.001*

Table 7: Comparison of capsulotomy sizes

Capsulotomy size	Group 1		Group 2		Group 3		P value
	2-3		3mm		4mm		
	Mean	SD	Mean	SD	Mean	SD	
Cylindrical shift	0.45	0.91	0.02	0.95	1.62	2.3	0.036*
Spherical shift	0.05	0.32	0.25	0.63	0.46	0.76	0.32
Spherical equivalent (SE)							
Pretreatment	-0.463	0.843	-1.0006	1.479	-0.62	1.696	0.597
After 3 days	0.18	0.95	0.73	1.31	0.64	1.37	0.58
BCVA (Log MAR)							
Pretreatment	0.57	0.196	0.74	0.42	1.05	0.48	0.046*
After 3 days	0.29	0.197	0.44	0.34	0.74	0.53	0.044*

* p value <0.05

Table 8: BCVA improvement table line wise

Improvement in number of lines	No. of patients
0	2
1	9
2	12
3	9
4	3

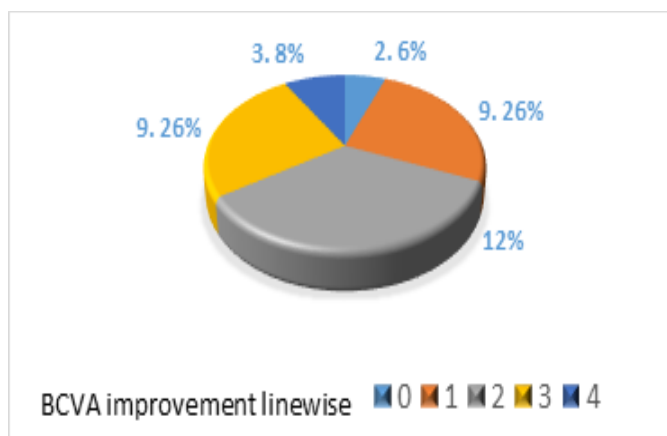


Fig. 1: Pie chart depicting post-procedure improvement in BCVA

Visual acuity at presentation was of 6/36-6/18 in majority (62%) of patients. Post-procedure visual acuity of 6/12 – 6/6 (60%) was noted the most (Table 3 and 3a). Before YAG laser capsulotomy a maximum (40%) of 14 patients showed a cylindrical error of -1.25 to -2.00 and Spherical refractive error of +1.25 to +2.00 was seen in 12 (34%) patients (Table 4 and 4a). Post procedure, two groups of 11 patients each (31%) had a cylindrical error of -1.25 to -2.00 and -2.25 to -3.00. Spherical error of +0.25 to +1.00 was seen in 13 (37 %) patients after YAG laser capsulotomy (Table 5 and 5a). Table 6 showed a statistical significance ($p < 0.001$) of BCVA after laser capsulotomy. A comparison of three groups based on capsulotomy size, cylindrical shift, spherical shift, BCVA and spherical equivalent is shown in Table 7. Although cylindrical shift showed a statistical significance of p value = 0.036, spherical shift was not significant ($p = 0.32$). There were no statistically significant differences in SE before and after laser treatment ($p = 0.597$ and $p = 0.58$, respectively). BCVA improvement was statistically significant before and after YAG laser capsulotomy ($p = 0.046$ and $p = 0.044$ respectively)

Pie chart in figure 1 showed that no patient had post procedure drop in VA, 2 status quo, & improvement in the rest. There was a posterior displacement of IOL which can be explained by reduction in minus sphere with Hyperopic shift. Most Patients were in the refractive error range of -1.00DS to +1.00 DS post procedure.

Discussion

Posterior capsule opacification continues to be the common problem following cataract surgery⁽²⁰⁾ albeit a delayed one⁽¹⁰⁾. PCO is also known as 'secondary cataract' or 'after cataract', which develops over the clear posterior capsule a few months to a few years after an uneventful cataract surgery. PCO results from the abnormal growth and proliferation of lens epithelial cells (LEC) on the capsule at the time of cataract surgery. These cells migrate to the posterior capsule, where they approach the central visual axis and cause visual axis

obscuration, resulting in dimness of vision. The PCO mainly has two forms, fibrous and pearl. Sometimes, a combination of both is also found. Clinically, it is seen as a wrinkle on the posterior capsule at the site of fusion of the anterior and posterior capsules⁽¹⁰⁾. A histological examination of the fibrous PCO shows extracellular matrix accumulation and the presence of elongated myofibroblast cells positive to vimentin and alpha smooth actin⁽²¹⁾.

Nd:YAG (1064nm) laser capsulotomy is a minimal invasive outpatient procedure, by which an opening is created in the opaque posterior capsule. The photodisruptive property of the laser, apart from causing the required therapeutic effect will also have effect on surrounding tissues; one such effect is on the myofibroblasts present in PCO causing shift in IOL position⁽²²⁾. Studies of the position of PCIOL following Nd: YAG capsulotomy have shown a tendency for a shift in the lens position⁽¹⁸⁾. The procedure has potential to affect the position of the PCIOL. Some studies have reported a subtle posterior shift⁽¹⁸⁾, while some failed to observe the effect⁽²³⁾. It is often subtle and may not be recorded. Theoretically hyperopic shift maybe caused by the backward movement of the IOL. In patients who have a PMMA intraocular lens, there is a tendency for a posterior movement and therefore a hyperopic shift⁽¹⁹⁾. The amount of shift is a function of intraocular lens style and capsulotomy size. A bigger capsulotomy is also found to be associated with increased posterior movement⁽¹⁹⁾. Chua et al found that the change in spherical equivalent after Nd: YAG laser capsulotomy was statistically insignificant⁽²⁴⁾. Eyyup *et al* reported a higher hyperopic shift and IOP elevation with a large capsulotomy size⁽²⁵⁾. Also the pseudo-accommodation in pseuophakic eyes maybe affected by the procedure⁽²⁶⁾. There are reports of IOL dislocation leading to significant changes in the refractive status of the eye following Nd YAG capsulotomy^(27,28,29).

In our study we found a statistically significant hyperopic shift in the cylindrical error of 4mm (capsulotomy size) group. Although there was a

tendency for hyperopic spherical shift, this was not statistically significant.

Conclusion

Present study concludes that patients who underwent Nd: YAG posterior capsulotomy have improved vision, have changes in the refraction, commonest being hyperopic shift. Also the cylindrical correction could vary significantly depending on the size of the opening created. Patient needs to be explained about this & the need for new spectacle correction.

Drawback in this study was lack of long follow up for at least 4 to 6 weeks to observe the refractive shift and analyze the final refractive status. This study will also require a Randomized Control Trial and a larger sample size to draw a conclusion about the pattern of refractive shift.

References

- Vasavada A, Raj S, Shah G, Nanavaty M. Posterior capsule opacification after lens implantation: incidence, risk factors and management. *Expert Review of Ophthalmology*. 2013;8(2):141-149.
- Schaumberg D, Dana M, Christen W, Glynn R. A systematic overview of the incidence of posterior capsule opacification. *Ophthalmology*. 1998;105(7):1213-1221.
- Fong C, Mitchell P, Rochtchina E, Cugati S, Hong T, Wang J. Three-Year Incidence and Factors Associated With Posterior Capsule Opacification After Cataract Surgery: The Australian Prospective Cataract Surgery and Age-related Macular Degeneration Study. *American Journal of Ophthalmology*. 2014;157(1):171-179.e1
- Van Bree M, van den Berg T, Zijlmans B. Posterior Capsule Opacification Severity, Assessed with Straylight Measurement, as Main Indicator of Early Visual Function Deterioration. *Ophthalmology*. 2013;120(1):20-33.
- Wakamatsu T, Yamaguchi T, Negishi K, Kaido M, Matsumoto Y, Ishida R et al. Functional visual acuity after neodymium: YAG laser capsulotomy in patients with posterior capsule opacification and good visual acuity preoperatively. *Journal of Cataract & Refractive Surgery*. 2011;37(2):258-264.
- Aron-Rosa D, Aron J, Griesemann M, Thyzel R. Use of the neodymium-yag laser to open the posterior capsule after lens implant surgery: a preliminary report. *American Intra-Ocular Implant Society Journal*. 1980;6(4):352-354.
- Buehl W, Findl O, Menapace R, Sacu S, Kriechbaum K, Koepl C et al. Long-term effect of optic edge design in an acrylic intraocular lens on posterior capsule opacification. *Journal of Cataract & Refractive Surgery*. 2005;31(5):954-961.
- Buehl W, Menapace R, Sacu S, Kriechbaum K, Koepl C, Wirtitsch M et al. Effect of a silicone intraocular lens with a sharp posterior optic edge on posterior capsule opacification. *Journal of Cataract & Refractive Surgery*. 2004;30(8):1661-1667.
- Cleary G, Spalton D, Koch D. Effect of square-edged intraocular lenses on neodymium: YAG laser capsulotomy rates in the United States. *Journal of Cataract & Refractive Surgery*. 2007;33(11):1899-1906.
- Vasavada A, Raj S, Johar S, Vasavada V, Vasavada V. Post-operative capsular opacification. *Nepalese Journal of Ophthalmology*. 2010;1(1).
- Leff S, Welch J, Tasman W. Rhegmatogenous Retinal Detachment after YAG Laser Posterior Capsulotomy. *Ophthalmology*. 1987;94(10):1222-1225.
- Javitt J, Tielsch J, Janner J. National outcomes of cataract extraction: Increased risk of retinal complications associated with Nd: YAG laser capsulotomy. *Ophthalmology*. 1992;99(10):1487-1498.
- Steinert R F, Puliafito C A, Kumar S R, Dudak S D, Patel S. Cystoid macular edema, retinal detachment, and glaucoma after Nd: YAG laser posterior capsulotomy. *The American Journal of Ophthalmology*. 1991;112(4):373-380.
- Shah G R, Gills J P, Durham D G, Ausmus W H. Three thousand YAG lasers in posterior capsulotomies: an analysis of complications and comparison to polishing and surgical discussion. *Ophthalmic Surgery*. 1986;17(8):473-477.
- Channell M, Beckman H. Intraocular Pressure Changes After Neodymium-YAG Laser Posterior Capsulotomy. *Archives of Ophthalmology*. 1984;102(7):1024-1026.
- Stark W J, Worthen D, Holladay J T, Murray G. Neodymium: YAG lasers: an FDA report. *Ophthalmology*. 1985;92(2):209-212.
- Holladay J T, Bishop J E, Lewis J W. The optimal size of a posterior capsulotomy. *The American Intra-Ocular Implant Society Journal*. 1985;11(1):18-20.
- Findl O, Drexler W, Menapace R, Georgopoulos M, Rainer G, Hitzinger C et al. Changes in intraocular lens position after neodymium: YAG capsulotomy. *Journal of Cataract & Refractive Surgery*. 1999;25(5):659-662.
- Yilmaz S, Ozdil M A, Bozkir N, Maden A. The effect of Nd: YAG laser capsulotomy size on refraction and visual acuity. *Journal of Refractive Surgery*. 2006;22(7):719-721.
- Aslam T M, Devlin H, Dhillon B. Use of Nd: YAG laser capsulotomy. *Survey of Ophthalmology*. 2003;48(6):594-612.
- Shirai K, Saika S, Okada Y, Oda S, Ohnishi Y. Histology and immunohistochemistry of fibrous posterior capsule opacification in an infant. *Journal of Cataract & Refractive Surgery*. 2004;30(2):523-526.
- Garg P, Malhotra R, Singh L, Agarwal K, Garg A. Role of prophylactic use of timolol maleate (0.5%) in preventing rise of intraocular pressure (IOP) post neodymium: Yttrium aluminum garnet (Nd: Yag) capsulotomy. *Nigerian Journal of Ophthalmology*. 2014;22(1):20.
- Thornval PNaeser K. Refraction and anterior chamber depth before and after neodymium: YAG laser treatment for posterior capsule opacification in pseudophakic eyes: A prospective study. *Journal of Cataract & Refractive Surgery*. 1995;21(4):457-460.
- Chua C N, Gibson A, Kazakos D C. Refractive changes following Nd: YAG capsulotomy. *Eye*. 2001;15(3):304-305.
- Karahan E, Tuncer I, Zengin M. The Effect of ND: YAG Laser Posterior Capsulotomy Size on Refraction, Intraocular Pressure, and Macular Thickness. *Journal of Ophthalmology*. 2014;2014:1-5.
- M. Nakazawa and K. Ohtsuki Apparent Accommodation in Pseudophakic Eyes after Implantation of Posterior Chamber Intraocular Lenses. *American Journal of Ophthalmology*. 1983;96(4):435-438.
- Flynn H. Pars plana vitrectomy in the management of subluxed and posteriorly dislocated intraocular lenses. *Graefe's Arch Clin Exp Ophthalmol*. 1987;225(3):169-172.

28. Maguire A. Scleral Loop Fixation for Posteriorly Dislocated Intraocular Lenses. Archives of Ophthalmology. 1991;109(12):1754.
29. Framme C, Hoerauf H, Roider J, Laqua H. Delayed intraocular lens dislocation after neodymium: YAG capsulotomy. Journal of Cataract & Refractive Surgery. 1998;24(11):1541-1543.