

## An unusual calcific myonecrosis: a case report

Banushree CS<sup>1,\*</sup>, Ramachandra V Bhat<sup>2</sup>

<sup>1</sup>Associate Professor, <sup>2</sup>Professor, Dept. of Pathology, Indira Gandhi Medical College & Research Institute, Puducherry

\*Corresponding Author:

Email: drbanushree15@hotmail.com

### Abstract

Calcific myonecrosis is a rare painful, expansile, calcified mass that develops as a result of compartment syndrome in a muscle of lower extremity. Patient usually present several years after trauma as a mass typically in anterior compartment of leg which can be mistaken for soft tissue tumor. Imaging studies can aid in the diagnosis of this less known entity. However, diagnosis is confirmed by histopathological findings of linear calcification and central necrosis inside a cavity in a muscle. We report a rare case of calcific myonecrosis involving posterior compartment of leg in a forty three year old female who had presented with pain in right mid-calf region for two weeks. Color Doppler showed small cystic lesion with calcification suggestive of probable neurofibroma for which complete excision of the lesion was done and diagnosis of calcific myonecrosis was made on histopathological examination.

**Keywords:** Calcification, Myonecrosis, Trauma.

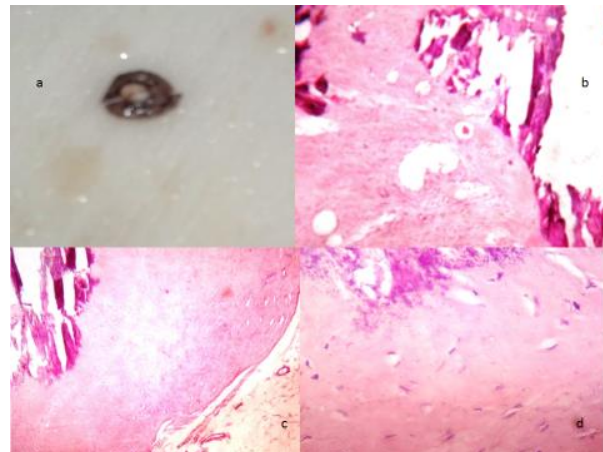
### Introduction

Calcific myonecrosis was first described in 1960 in two patients by Gallie and Thompson.<sup>[1]</sup> Literature search suggests that calcific myonecrosis has occurred anywhere between 10 and 64 years after the initial injury. The age at presentation for all the cases reported in literature ranged from 34-87 years (mean age of 51 years). Its most common location is the anterior compartment of the leg, although cases have been described in the posterior compartment (only one case), foot and upper limb.<sup>[2,3]</sup> Calcific myonecrosis is a rare sequela of compartment syndrome but its pathophysiology is unknown. However the lesion most likely arises after the trauma resulting in compartment syndrome that causes a decrease in blood supply to a limited area, which leads to a cystic degeneration, muscle necrosis and fibrosis. Repeated intra-lesional haemorrhage cause the mass to increase and calcify.<sup>[1,4]</sup> Compartment syndrome following snake bite has been reported.<sup>[5]</sup> We present a rare case of posterior compartment calcific myonecrosis of leg in a female patient who had a chronic compartmental syndrome.

### Case Report

A forty three year old female patient presented with pain in mid-calf region for two weeks. Patient gave history of on and off pain along common peroneal nerve since 10 years. On examination, patient had tenderness in mid-calf region for which Doppler study was suggested. Color Doppler showed a small cystic swelling with calcification in posterior-lateral aspect of leg and probable diagnosis of neurofibroma was made. Plain radiographs revealed a soft tissue mass with extensive calcification. Laboratory investigations were within normal limit. Complete excision of mass was done and submitted for histopathological examination. Grossly, tan globular pseudocapsulated mass measuring

10X 5mm. On cut section, central haemorrhage with extensive calcification surrounded by muscle was noted [Fig. 1a]. On histopathology, central granulation tissue composed of blood vessels, inflammatory cells and macrophages surrounded by dense linear calcification rimmed by muscle bundles were noted [Fig. 1b-d]. Final diagnosis of calcific myonecrosis was made.



**Fig. 1a-d. a) Gross specimen showing pseudocapsule with central haemorrhage surrounded by calcification and tan area. b) Photomicrograph (H & E; 10X) showing central granulation tissue surrounded by dense linear calcification. c) Photomicrograph (H & E; 10X) showing pseudocapsule enclosing muscle bundle and calcification. d) Photomicrograph (H & E; 40X) showing calcification in skeletal muscle fibre**

### Discussion

In our case, diagnosis of calcific myonecrosis was made on histopathology. This condition often mimics soft tissue tumours both clinically and radiologically because of the prolonged delay between the time of

injury and presentation as a soft tissue mass. Majority of reported cases involved anterior compartment of leg except for one case involving posterior compartment, more commonly affecting males than female and presenting as large mass. The present case is of a female patient involving posterior compartment and complete excision was done at the earliest.<sup>[3]</sup> Calcific myonecrosis should be differentiated from other calcific soft-tissue masses which include myositis ossificans, tumoral calcinosis, fat necrosis, soft tissue chondroma, metastatic calcification of renal insufficiency, abscess with calcification, myonecrosis with dystrophic calcification of diabetes, dermatomyositis and sarcomas. Calcific myonecrosis occurs most often following ischemic necrosis of muscle, typically as a result of a compartment syndrome in an extremity.<sup>[4]</sup> Liquefaction of the center of the soft tissue is unusual in neoplasm and localized involvement of single muscle will exclude systemic inflammatory disorders.

Myositis ossificans will show typical zonations.<sup>[6]</sup> Calcific myonecrosis should be diagnosed early otherwise it can get inflamed over a period of time and can lead to multiple draining sinuses discharging calcific material which is difficult to treat.<sup>[7]</sup> Compartment syndrome compromises circulation due to increase in pressure, resulting in necrosis and eventual fibrosis. There is also an association with peripheral nerve injury, especially the common peroneal nerve. The mass enlarges as a result of repeated hemorrhage into it which may be symptomatic or painless, despite enlargement.<sup>[1,8]</sup> Prevention of this condition is by early detection and treatment of patients who have compartment syndrome.<sup>[9]</sup> In a symptomatic patient, complete mass excision with flap coverage and primary closure with a suction drain or open wound for secondary intentional healing were recommended in large lesions.<sup>[10]</sup>

Any soft tissue calcified mass irrespective of its size in extremities, calcific myonecrosis should be a differential diagnosis and to the best of our knowledge we conclude that, present case of calcific myonecrosis in posterior compartment is only a second case reported in the literature till date.

## References

1. Janzen DL, Connell DG, Vaisler BJ. Calcific myonecrosis of the calf manifesting as an enlarging soft-tissue mass: imaging features. *AJR*. 1993;160:1072-4.
2. Larson RC, Sierra RJ, Sundaram M, Inwards C, Scully SP. Calcific myonecrosis: a unique presentation in the upper extremity. *Skeletal Radiol*. 2004;33:306-309.
3. Papanna MC, Monga P, Wilkes RA. Post-traumatic calcific myonecrosis of Flexor Hallucis Longus a case report and literature review. *Acta Orthop. Belg*. 2010;76:137-141.
4. Olsen KM, Chew FS. Tumoral calcinosis: pearls, polemics, and alternative possibilities. *Radio Graphics*. 2006;26:871-85.
5. Yuenyongviwat V, Laohawiriyakamol T, Suwanno P, Kanjanapradit K, Tanutit P. Calcific myonecrosis following snake bite: a case report and review of the literature. *Journal of Medical Case Reports*. 2014;8:193.
6. Janzen DL, Connell DG, Vaisler BJ. Calcific myonecrosis of the calf manifesting as an enlarging soft-tissue mass: imaging features. *AJR Am J Roentgenol*1993; 160:1072-1074.
7. Sreenivas T, Kumar KN, Menon J, Nataraj, AR. Calcific myonecrosis of the leg treated by debridement and limited access dressing. *Int j low extrem wounds* 2013;12:44-9.
8. Finlay K, Friedman L, Ainsworth K. Calcific myonecrosis and tenosynovitis: Sonographic findings with correlative imaging. *J Clin Ultrasound* 2007;35: 48-51.
9. De Carvalho BR. Calcific myonecrosis: a two-patient case series. *Jpn J Radiol*. 2012;30:517-521.
10. Holobinko JN, Damron TA, Scerpella PR, Hojnowski L. Calcific myonecrosis: keys to early recognition. *Skeletal Radiol*. 2003;32:35-40.