

Choroid plexus papilloma of the 3rd ventricle: A case report

Iffat Jamal

Tutor, Dept. of Pathology, All India Institute of Medical Sciences Patna, Bihar

Corresponding Author:

E-mail: iffatjamal111@gmail.com

Abstract

Choroid plexus papillomas (CPPs) are rare intracranial neoplasms, especially in the third ventricle. The most common site of presentation of these lesions is in the fourth ventricle in adults and lateral ventricles in children. Third ventricular lesion is uncommon, limited to a few case reports. These highly vascular tumors retain the physiological function of choroid plexus and thus lead to overproduction of cerebrospinal fluid (CSF), besides obstructing the pathway resulting in hydrocephalus. CT and MRI are the investigations of choice and are diagnostic. Surgical management vary according to the site of tumor and aim is complete excision of tumor. We present an interesting report of a 5 months old infant who presented with symptoms of raised intracranial pressure whose CT revealed third ventricular CPP. After ventriculoperitoneal shunt, tumor was excised. Pathological examination revealed Choroid plexus papilloma.

Keywords: Choroid plexus papilloma, Hydrocephalus, Third ventricular tumors.

Introduction

Case report: A 5 months old male presented with increased head circumference and vomitings for 1 week. On general examination, the child was alert with downward gaze. CT and MRI demonstrated gross ventriculomegaly and enhancing mass lesion in third ventricle. The child underwent a ventriculoperitoneal shunt procedure followed by total excision of tumor. The histopathology of the resected tumor revealed tumor cells arranged in multiple papillae with fine fibrovascular core, confirming the diagnosis of Choroid plexus papilloma.

Choroid plexus tumors are rare intraventricular tumors, accounting for less than 1% of all intracranial tumors and 2-4% of all brain tumors in children^(1,2). Most of these tumors occurs in patients less than 2 years of age. Most common location is lateral ventricle, followed by fourth ventricle. Sporadic case reports have described third ventricle choroid plexus papilloma^(4,5,6). Diagnosis rests on imaging studies that show that mass in the location of third ventricle with typical imaging features on sonography, computed tomography (CT), Magnetic resonance imaging [MRI]. Treatment is complete surgical excision of tumor.

Discussion

CPP is a rare tumor of neuroectodermal origin, accounting for less than 1% of all intracranial neoplasm⁽¹⁾. CPP is one of the neoplasm frequently observed to occur primarily within the ventricular system, but it rarely involves the third ventricle. In childhood, 80% of CPPs arises in lateral ventricle, 16% in the fourth ventricle and 4% in third ventricle. The incidence of third ventricular CPP is higher in the first decade of life with a female predominance although over all these tumors are more common in male subjects^(3,10,11).

The tumors typically present in neonatal or early childhood period, pointing to their congenital origin. These lesions typically manifests with increasing head size, lethargy, decreased activity and poor psychomotor milestones in infants. As the child grows older, visual impairment and gait disturbances are noted, related to raised intracranial pressure (ICP) and direct pressure caused by the tumor. Hydrocephalus and raised ICP in these cases caused by two mechanisms: Direct obstruction of CSF pathway and overproduction of CSF by tumor cells that tend to maintain function of choroid plexus⁽⁸⁾. CPPs are histologically benign neoplasms derived from neuroectoderm, assigned a WHO grade-1, grade-II designation is reserved for atypical CPPs. Resection of these tumors is often curative with little chance of recurrence following gross-total resection. These tumors present special management challenges due to several unique characteristics, including young age at presentation, potential for CSF overproduction and the inherent vascularity of these lesions^(2,7,12). Due to the rich vascular supply of these tumors, endovascular embolization as a preoperative adjunct has been used in an attempt to reduce blood supply intraoperatively.

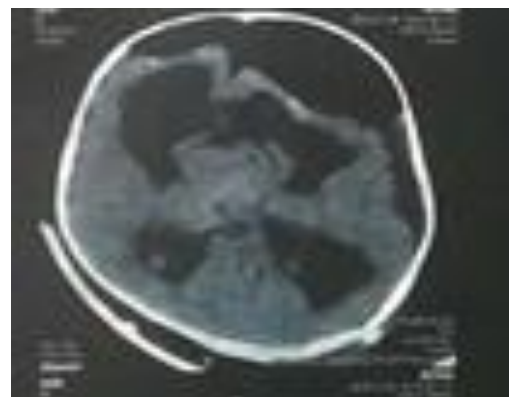

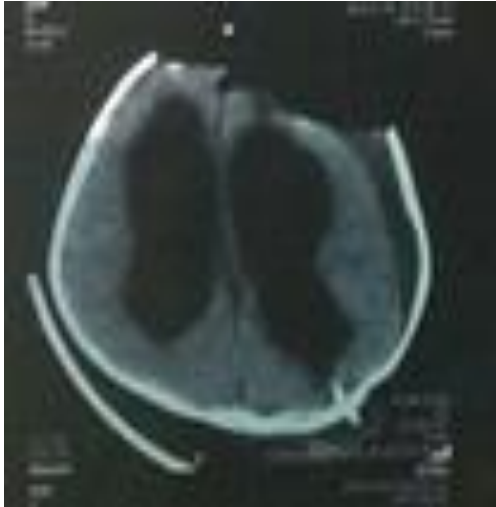


Fig. 1: Axial computed tomography (CT) images reveal an enhancing lobulated mass in the third ventricle (a) with dilatation of the lateral ventricles (b)

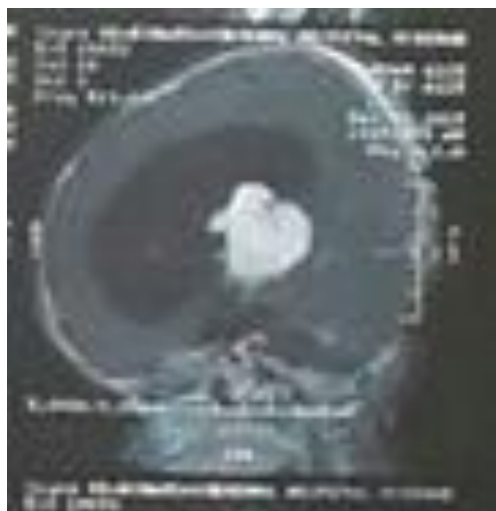
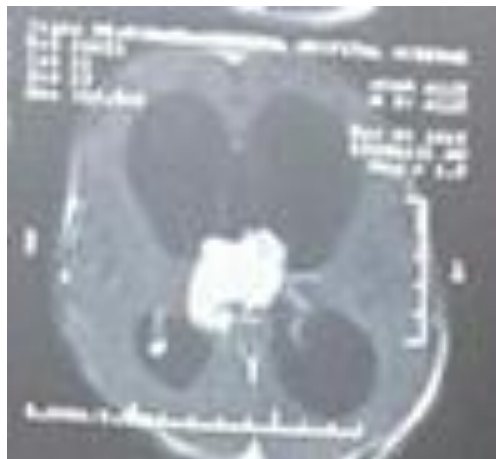

Fig. 2: Axial magnetic resonance (MR) images Contrast-enhanced axial (c) and sagittal (d) images reveal avid enhancement within the tumor and extension into fourth ventricle.

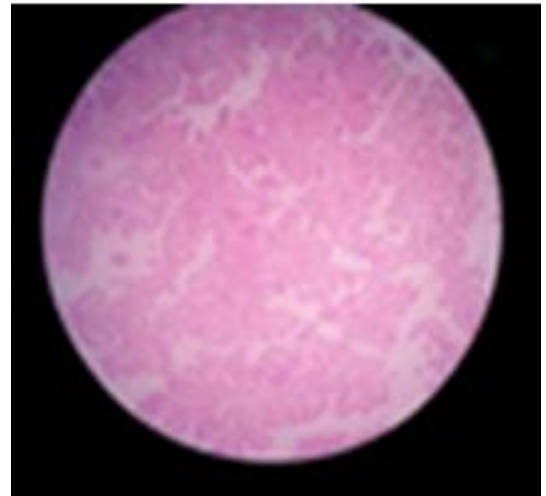
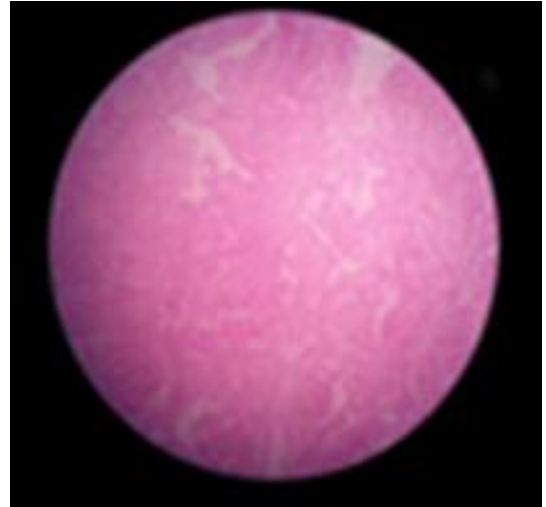


Fig. 3: Low power (a) and high power (b) photomicrograph reveal tumor cells arranged in multiple papillae with fine fibrovascular core.

Imaging plays a vital role in differentiating between obstructive (noncommunicating) and nonobstructive (communicating) hydrocephalus. Ultrasonography (USG) is the modality of choice in utero, neonatal, and early infancy. CPPs appear as echogenic masses with lobulated outline. Their echogenicity and other morphological features closely match the normal choroid plexus. CT plays an important role in older children where the acoustic window for USG is lost. CECT depicts these lesions as avidly enhancing lobulated masses. The degree of heterogeneity is variable depending on the size of tumor, and if marked, should lead to a suspicion of CPC, particularly if there is adjacent invasion. MRI is the modality of choice in older children for central nervous system imaging in general and intracranial tumors in particular. This is related to the ability of MRI to provide multiparametric imaging affording a preoperative typing and grading of tumor, planning of biopsy, and surgery.

Conclusion

Management usually comprises of diversion procedure prior to definitive tumor excision. Complete removal of tumor is advocated and various approaches to third ventricular tumors includes transcalsal, transfrontal, transforaminal routes, and supracerebellar infratentorial^(13,14).

In individual cases, the surgical approach would depend on location, size, vascularity and extension of tumor through foramen of Monro. Recently, microsurgical techniques have also been described to improve the outcome. Another innovative therapy is radiosurgery that aims at avascular necrosis and shrinkage of tumor and is best as an adjunct to surgery. CPPs have an excellent long term survival after only gross total resection, ranging from 90% to 100%.

References

1. Buckle C, Smith JK. Choroid plexus papilloma of the third ventricle. *Pediatr Radiol* 2007;37:725.
2. Ogiwara H, Dipatri AJ Jr, Alden TD, Bowman RM, Tomita T. Choroid plxus tumors in pediatric patients. *Br J Neurosurg* 2012;26:32-73.
3. Kroppenstedt SN, Golfinos J, Sonntag VK, Spetzler RF. Pineal region lesion masquerading choroid plexus papilloma: Case report. *Surg Neurol* 2003;59:124-7; discussion 127.
4. Fortuna A, Celli P, Ferrante L, Turano C. A review of papillomas of the third ventricle. *J Neurosurg Sci* 1979;23:61-76. [PUBMED]
5. Gradin WC, Taylon C, Fruin AH. Choroid plexus papilloma of the third ventricle. *Neurosurgery* 1983;12:217-20. [PUBMED]
6. Costa JM, Ley L, Claramunt E, Lafuente J. Choroid plexus papilloma of III ventricle in infants. Report of three cases. *Childs Nerv Syst* 1997;13:244-9. [PUBMED]
7. Krishnan S, Brown PD, Scheithauer BW, Ebersold MJ, Hammack JE, Buckner JC. Choroid plexus papillomas: A single institutional experience. *J Neurooncol* 2004;68:49-55.
8. Milhorat TH, Hammock MK, Davis Da, Fenstermacher JD. Choroid plexus papilloma: Proof of cerebrospinal fluid overproduction. *Childs Brain* 1976;2:273-89. [PUBMED]
9. Wind JJ, Bell RS, Bank WO, Myseros JS. Treatment of third ventricular choroid plexus papilloma in an infant with embolization alone. *J Neurosurg Pediatr* 2010;6:579-82.
10. Carson BS, Weingart JD, Guarnieri M, Fisher PG. Third ventricular choroid plexus papilloma with psychosis. Case report. *J Neurosurg* 1997;87:103-5.
11. Karim A, Fowler M, McLaren B, Cardenas R, Patwardhan R, Nanda A. Concomitant choroid plexus papillomas involving the third and fourth ventricles: A case report and review of the literature. *Clin Neurol Neurosurg* 2006;108:586-9.
12. Menon G, Nair SN, Baldawa SS, Rao RB, Krishnakumar KP, Gopalakrishnan CV. Choroid plexus tumors: An institutional series of 25 patients. *Neurol India* 2010;58:429-35.
13. Apuzzo MLJ, Chikovani OK, Gott PS, Teng EL, Zee CS, Giannotta SL, *et al.* Transcallosal, interforaminal approaches for lesions affecting the third ventricle: Surgical considerations and consequences. *Neurosurgery* 1982;10:547-54
14. Mohindra S, Savardekar A. Management problems in a case of third ventricular choroid plexus papilloma. *J Pediatr Neurosci* 2012;7:40-2. [PUBMED]