

Tenzel's: an adorable reconstruction surgery to create beautiful near normal eyelids

Anuradha Pradhan^{1,*}, Ratan Deep Kumar Agrawalla², Sharmistha Behera³, Pramod Kumar Sharma⁴, Kanhei Charan Tudu⁵, Sasmita Sahu⁶

^{1,2}Consultant, ^{3,5}Associate Professor, ^{4,6}Assistant Professor, Dept. of Ophthalmology, VSS Medical College, Burla, Orissa

***Corresponding Author:**

Email: dr.anuradha.in@gmail.com

Abstract

Background: To study the outcomes of Tenzel's flap in eyelid reconstruction to achieve near normal eyelids.

Method: A retrospective study of 30 patients who had undergone eyelid reconstruction using Tenzel's flap between January 2015 and December 2015. Initial diagnosis, postoperative complications and outcomes were noted.

Result: Reconstruction after excision of eyelid tumors is the commonest indication for surgery followed by road traffic accidents. 13 flaps are performed for upper eyelid defects and 17 for lower eyelid defects. Females (19) are outnumbered as compared to males (11). All the patients have a scar mark over temporal area which is the most common complication followed by lid instability, sagging of lateral canthus, lid dehiscence. Fat atrophy is a long term complication.

Conclusion: The cosmetic outcome is acceptable along with good lid stability.

Keywords: Advancement flap, Eyelid reconstruction, Lateral canthal tendon, Rotation flap, Tenzel's flap

Introduction

Eyelids embellish and ornate the face. Lids are aptly called, the shutters of the globe because they not only protect the eye as a whole but also maintain the physiology of tear film. Hence restoration of normal anatomy and function is always the goal in eyelid reconstruction surgery.

To provide optimal anatomical, aesthetic and functional results, several procedures have been introduced considering size of the defect, age of the patients and location of the lesions.

Reconstructive techniques can be classified considering the anatomical area of defect: superior eyelid, inferior eyelid and inner or external canthus^{1,2,3,4}. Simplifying it, we can distinguish³:

1. direct suture
2. grafts, and
3. flaps.

By definition, a skin flap differs from a skin graft as it consists of skin and subcutaneous tissue with its subdermal plexus of vessels. Although the flap is completely raised from the underlying tissue, it is still connected by at least one side to the surrounding skin and fat. Because of the vessels contained in the pedicle the flap can preserve its own blood supply, independent of the site on which it is placed.

Periorbital flaps are divided into 5 types⁵ –

1. Sliding flap: skin surrounding a simple ellipse is undermined to close the defect.
2. Advancement flap: skin surrounding the defect is fashioned into a three sided flap, which is dissected and advanced on its own long axis to close the defect.⁶
3. Rotation flap: here the skin adjacent to the defect is lifted and rotated on itself to close the defect.⁶

4. Transposition flap: the skin not directly adjacent, but close to the defect, is lifted over the intervening skin and fitted into the defect. The angle of rotation in the flaps should not be too large, because a large degree of rotation at the flap base may compromise the blood supply to the tip.⁶

5. Island flap: The flap consists of a free island of skin and muscle, here the flap is freed from all the sides, but remains attached to a central subcutaneous pedicle; the flap can now be considerably advanced in any direction to fill in the defect and the flap site can be repaired by direct closure.

In 1975, Tenzel⁷ described the use of a semicircular advancement flap over the lateral canthal area combined with a lateral canthotomy and inferior cantholysis to repair defects of the central lower eyelid up to 50% of the length of the eyelid margin. The incision begins at the lateral canthus and curves superiorly and temporally in semicircular fashion. The incision is not truly semicircular. Its horizontal dimension is greater than the vertical dimension.⁸ The incision is carried down to the lateral canthal ligament and lateral orbital rim to create a musculocutaneous flap. After the flap dissection is complete, it can be advanced medially and the defect can be closed directly. The lateral canthus is reconstructed by suturing the deep surface of the orbicularis to the periosteum overlying the Whitnall tubercle using a 5-0 vicryl suture.⁹ However the flap can be used for both upper as well as lower eyelid reconstruction surgery.

Levine and Buckman⁹ modified Tenzel semicircular advancement flap by severing the orbital septum from its attachment to the inferolateral arcus marginalis, releasing the inferior eyelid retractors and conjunctiva from the inferior edge of the tarsal plate. By doing this they were able to close defects between 60% and 80% of

the length of the eyelid margin with excellent aesthetic results.⁹

Materials and Methods

This retrospective non-comparative study was carried out in the department of Ophthalmology, VSS Medical College and Hospital, Burla, Orissa over a period of one year, from January 2015-December 2015. All patients with full-thickness lid defect with horizontal extent <1/2 following eyelid trauma or excision of lid tumor were included. Patients with canalicular injury were excluded from study.

30 patients were selected and undergone detailed medical and ocular examination. All the patients were informed about the procedures, possible outcomes and complications. Written consent was taken.

The procedure was done under local anesthesia in all the patients. A lateral cantholysis of appropriate limb of the lateral canthal tendon was carried out. A high arched semicircular flap of skin and orbicularis oculi muscle was created. The diameter of the flap was 2-4 cm depending on the primary defect. The lateral extension of the flap was not beyond the lateral part of the eyebrow to protect the terminal fibers of the trigeminal nerve. The orbital septum was freed. The conjunctiva was mobilized and the lid was pulled medially to approximate the wound edges by 5-0 silk interrupted sutures. A new lateral canthus was created with a 4-0 prolene interrupted suture which suspends the reformed segment of the lid from the intact limb of the lateral canthal tendon. The orbicularis muscle was closed with 6-0 vicryl and skin with 5-0 silk interrupted sutures. The conjunctiva and skin at the reconstructed lid margin was sutured with 6-0 vicryl.

The patients were kept on intravenous antibiotic and intramuscular analgesic for 3 days. Topical antibiotic ointment was applied locally on the wound for one week.

On first post-operative day surgical dressing was done for all patients. They were advised to report after 7 days for suture removal. All the patients were followed-up weekly for 1 month, then monthly for 6 months.

Result

Following findings are noted.

Table 1: Showing causes of reconstruction

Cause	No of Patients	Percentage
Lid tumors	15	50.00
RTA	13	43.33
Burn	2	6.67

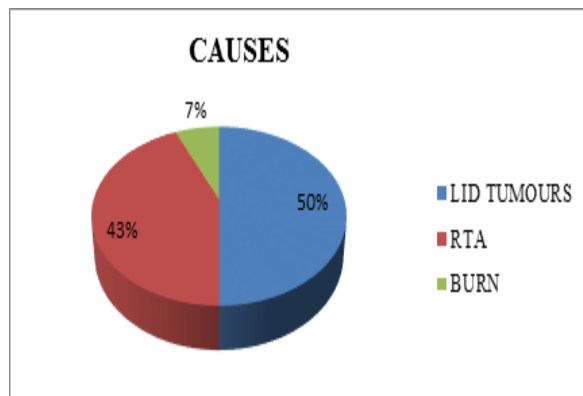


Fig. 1: Causes

Table 2: Eyelid involvement

Eyelid	RE	LE	Total no of patients	Percentage
UL	6	7	13	43.33
LL	8	9	17	56.67

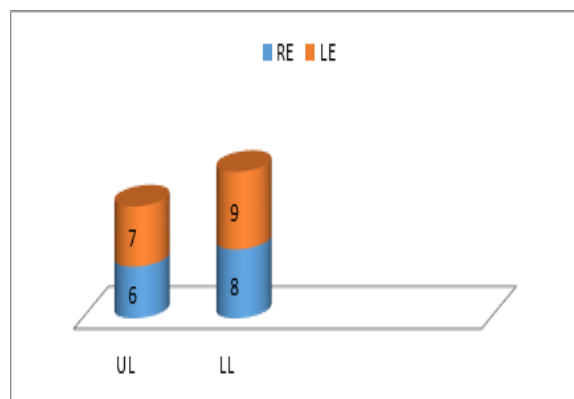


Fig. 2: Eyelid involvement

Table 3: Sex distribution

Sex	No of patients	Percentage
Male	11	36.67
Female	19	63.33

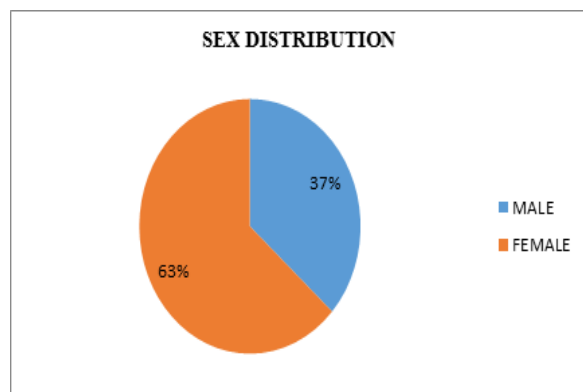


Fig. 3: Sex distribution

Table 4: Post-operative complications

Complications	No of patients	Percentage
Temporal scar	30	100.00
Lid instability	3	10.00
Lid dehiscence	1	3.33
Sagging of lateral canthus	2	6.66
Fat atrophy	1	3.33

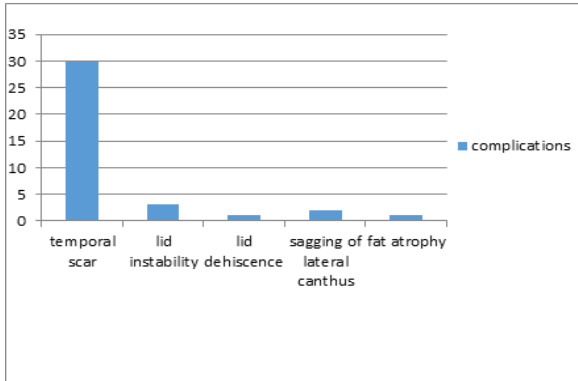
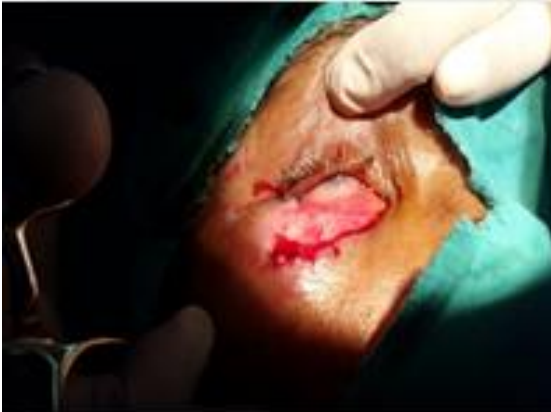
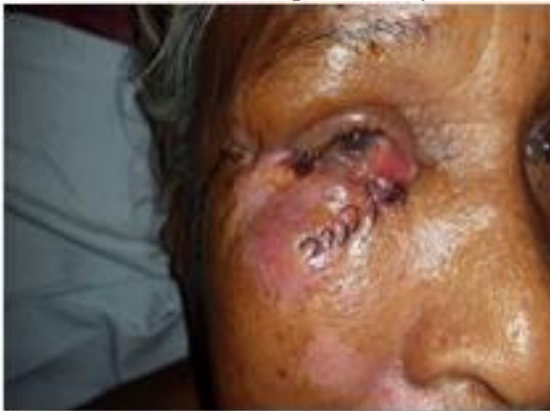
Fig. 4: Postoperative complications

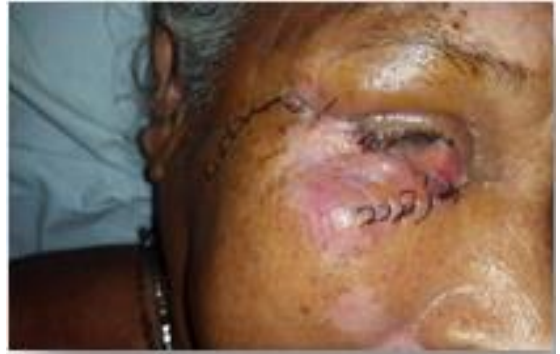Picture 1: Showing lid tissue loss following injury



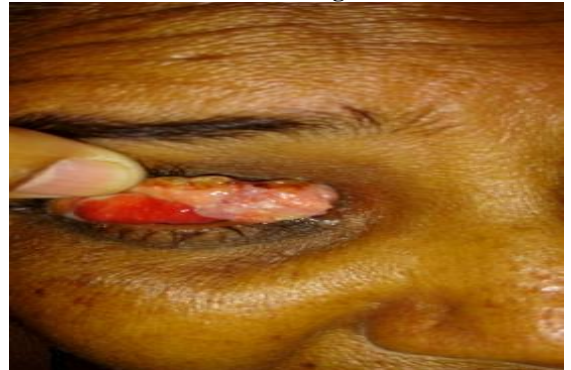
Picture 2: Post-operative day 1



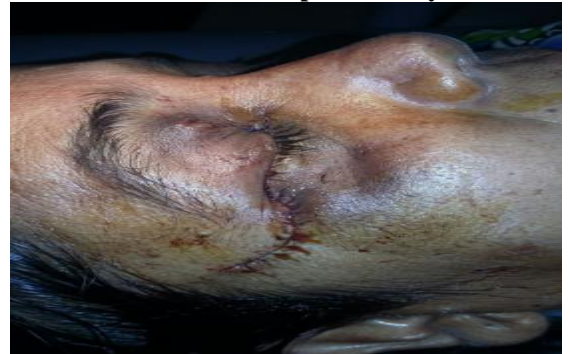Picture 3: Post-operative day 7



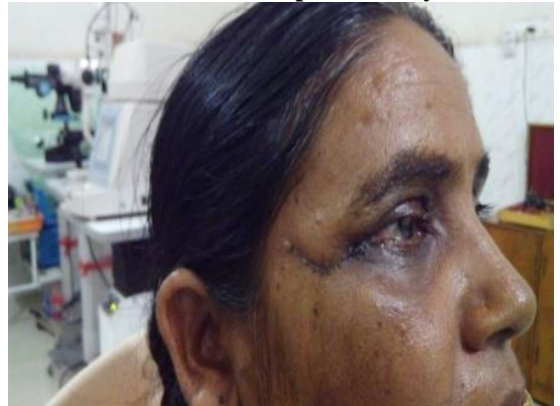Picture 4: Showing lid mass



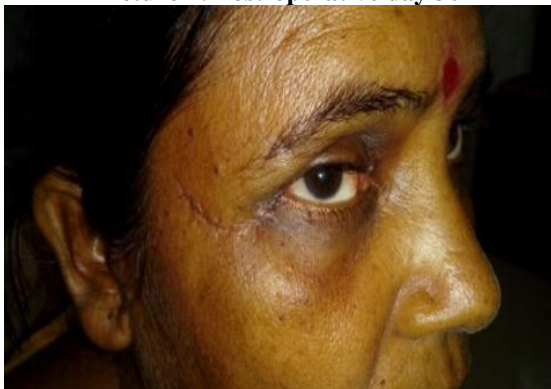Picture 5: Post-operative day 1



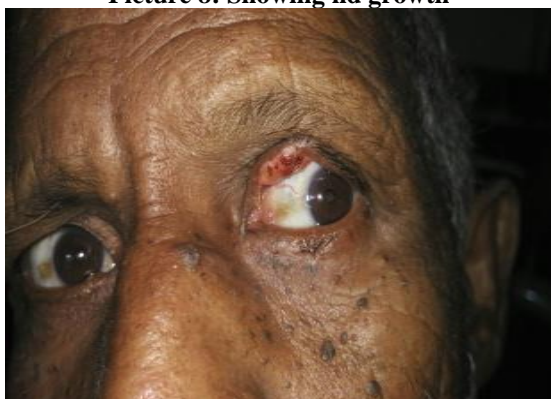Picture 6: Post-operative day 7



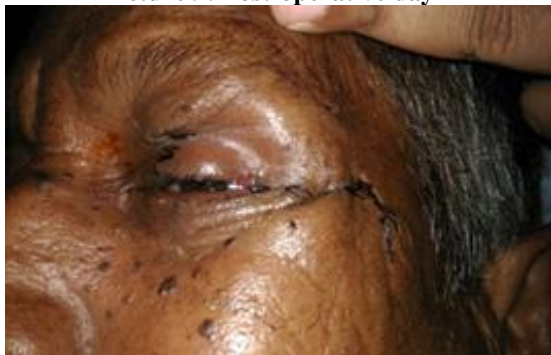Picture 7: Post-operative day 30



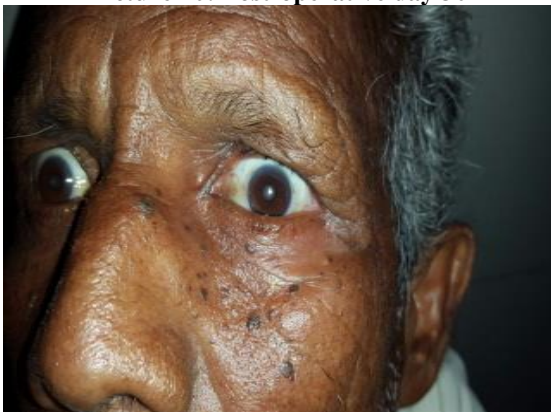Picture 8: Showing lid growth



Picture 9: Post-operative day 7



Picture 10: Post-operative day 30



Discussion

In the Present study, lid tumors (50.00%) are the most common cause of lid reconstruction followed by road traffic accidents (43.33%).

Cannon *et al.*¹⁰ in their study showed Basal cell carcinoma is the commonest cause for eyelid reconstruction.

In the present study, 17 musculocutaneous flaps are created for lower lid defects and 13 flaps for upper lid defects.

In Cannon *et al* study thirty-five composite grafts were performed for lower eyelid defects and seven for upper eyelid defects in 42 patients.

A study by Rathore *et al*¹¹ showed good results with full-thickness skin grafts in eyelid reconstruction. The study included 100 Caucasian patients out of which 60 with lower eyelid defects and the rest with upper eyelid or canthal defects.

In the present study temporal scar mark is the most common complication followed by lid instability, sagging of lateral canthus, lid dehiscence. Fat atrophy is the long term complication.

Bashour M¹² in his article mentioned about complications of eyelid reconstruction. Eyelid marginal positional abnormalities are most common complication though not serious. Other complications of lower lid reconstruction include marginal ectropion, lateral tissue sag, corneal injury, orbital hemorrhage, conjunctival scarring, upper eyelid instability.

The Present study includes 19 female patients and 11 male patients.

In Rathore et al study, out of 100 patients 54 were females and 46 patients were male.

Conclusion

There are various techniques available for reconstructions of eyelid defects starting from the spontaneous healing after excising the lesion. While choosing a technique, the specific function of the area of the eyelid has to be kept in mind. The upper eyelid is for mobility and the lower eyelid is for stability along with the canthii. It is very important to know the various options available for reconstruction. The availability of tissues, technical expertise, and the specific needs of the patient have to be kept in mind before choosing a particular technique. Eyes are the focal point of the face, so acceptable cosmesis in reconstruction should be a major requisite. In our study the cosmetic outcome is acceptable along with good lid stability.

Acknowledgement

Authors do not have any financial interest related to the study.

This study is dedicated to Tenzel and his technique, for the valuable contribution to the field of ophthalmology.

Reference

1. Bernardini FP. Management of malignant and benign eyelid lesions. *Curr Opin Ophthalmol*. 2006;17:480–484. Review. [PubMed]
2. Mustardé JC. *A Practical Guide*. ed 2. Edinburgh: Churchill Livingstone; 1980. Repair and Reconstruction in the Orbital Region.
3. Actis G, Malinverni W, Kuba I. Free grafts in the orbital region. *Panminerva Med*. 1987;29:61–63. [PubMed]
4. Ferguson NM, Mathijssen IM, Hofer SO, Mureau MA. Decision making in reconstruction of defects of the eyelid. *J Plast Surg Hand Surg*. 2011;45:45–50. [PubMed]
5. Sharma V, Benger R, Martin P. Techniques of periocular reconstruction. *Indian J Ophthalmol*. 2006;54(3):149-158
6. Patrinely JR, Marines HM, Anderson RL. Skin flaps in periorbital reconstruction. *Sury Ophthalmol* 1987;31:249-61.
7. Tenzel R R. Reconstruction of the central one half of an eyelid. *Arch Ophthalmol*. 1975;93:125–126. [PubMed]
8. Tenzel R R, Stewart W B. Eyelid reconstruction by the semicircle flap technique. *Ophthalmology*. 1978;85:1164–1169. [PubMed]
9. Levine M R, Buckman G. Semicircular flap revisited. *Arch Ophthalmol*. 1986;104:915–917. [PubMed]
10. Cannon PS, Madge SN, Kakizaki H, Selva D. Composite grafts in eyelid reconstruction: the complications and outcomes. *Br J Ophthalmol*. 2011 Sep;95(9):1268-71.
11. Rathore DS, Chickadasarahilli S, Crossman R, et al. Full thickness skin grafts in periocular reconstructions: long-term outcomes. *Ophthal Plast Reconstr Surg*. 2014 Nov-Dec. 30(6):517-20. [Medline].
12. Bashour M. Lower Eyelid Reconstruction Treatment & Management. [Medscape]