

## Radiological criteria to predict complex regional pain syndrome in distal radial fractures: A preliminary report

Mantu Jain<sup>1</sup>, Ritesh Runu<sup>2,\*</sup>, Santosh Kumar<sup>3</sup>, Manish Kumar<sup>4</sup>, Shishir Kumar<sup>5</sup>, Shweta Lal<sup>6</sup>

<sup>1</sup>Assistant Professor, AIIMS, Bhubaneswar, <sup>2</sup>Associate Professor, <sup>3</sup>Professor, <sup>4,5</sup>Assistant Professor, Indira Gandhi Institute of Medical Sciences, Patna, Bihar, <sup>6</sup>Senior Lecturer, BRADS, Patna, Bihar

\*Corresponding Author:

Email: riteshdr@rediffmail.com

### Abstract

Complex Regional Pain Syndrome is known complication of distal radial fractures. At present we have no radiological criteria to predict it. This was a prospective and retrospective observational study done on 72 patients with follow up of 1 year. The patients were divided in two groups on the basis of Effective Radio lunate flexion < 25deg (midcarpal instability) and >25deg (radiocarpal instability). The results showed that the loss of radial tilt, loss of radial length, restriction of pronation and supination was high in midcarpal instability group. The same group has high incidence of CRPS. We can conclude that midcarpal instability is due to high severity of trauma which may be one of the causes of complex regional pain syndrome. Also the group treated by manipulation and cast has high risk of complex regional pain syndrome. We recommend carpal instability to be kept in mind while deciding treatment in distal end radial fractures. Patients with midcarpal instability should preferably be treated by open reduction and fixation with early mobilisation.

**Keywords:** Distal radial fractures, Complex regional pain syndrome, Radiological criteria.

### Introduction

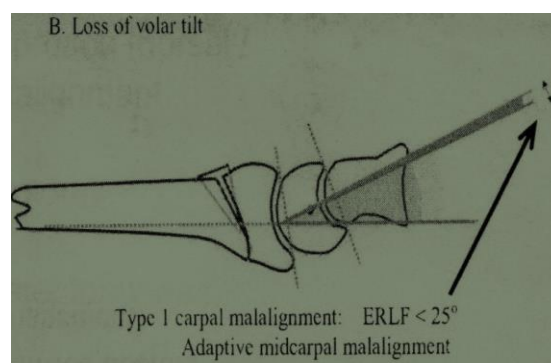
Complex regional pain syndrome (CRPS) is a known complication in 8 to 35% of distal end radial (DER) fractures.<sup>(1)</sup> Elderly and those with psychological or psychiatric conditions are at high risk of developing CRPS.<sup>(1)</sup> At present we have no radiological criteria to predict it. We hypothesize that carpal malalignment in DER fractures may help in predicting CRPS. Carpal malalignment in distal radial fractures has been studied in detail and its association with development of wrist arthritis, wrist pain and poor functional outcome has been published in English literature.<sup>(2-6)</sup> This is the first report of association of CRPS and carpal malalignment in DER fractures in English literature.

### Materials & Methods

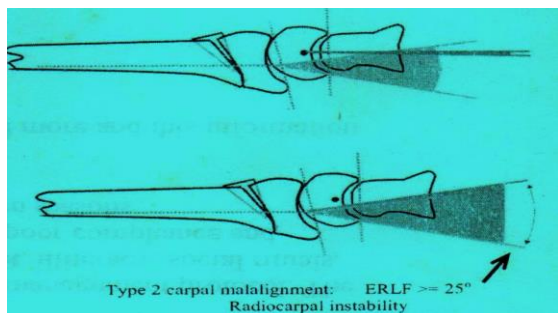
This was a prospective study done in a hospital setup. All the patients with distal radial fractures reporting to orthopedic OPD and emergency between June 2013 and December 2014 were included in this study. Patients with previously injured wrist, metabolic diseases, psychological disorders, and fractures with open physis or delayed presentation were excluded. Total of 78 patients (26 males and 52 females) were enrolled. 6 patients (case 14, 16 34, 42, 64, 68) were excluded due to age less than 19 yrs as it is the maximum age for physal closure of distal radius. 72 patients with mean age of 48years (20 – 75 years) were followed up for one year. After initial examination and x rays, the fractures were treated by either closed reduction & casting, closed reduction and pinning or open reduction & plating. The patient data was recorded at index presentation then at 6, 12, 24 and 52 weeks. Apart from demographic data, radiological data (radial

tilt -RT, radial inclination -RI, radial length -RL, ulnar variance -UV, radio lunate angle - RLA and Effective Radio Lunate Flexion - ERLF) were recorded. (Fig. 1) **Effective Radio Lunate Flexion** was calculated by deducting Radio lunate angle from Loss of radial (volar) tilt (Dorsal angulation + 11degrees).<sup>(3)</sup> Radio lunate angles are positive dorsally and negative palmarly. The ERLF < 25deg shows midcarpal instability while >25 degrees shows radiocarpal instability.<sup>(3)</sup> (Fig. 1, 2). Functional data recorded were dorsiflexion and palmar flexion of wrist, pronation and supination of forearm and grip strength. Grip strength was noted manually by single author (RR). Grip strength was classified in five grades.

1	Poor	Unable to flex the fingers
2	Weak	Able to flex the fingers but unable to make fist
3	Moderate	Able to make weak grip
4	Strong	Able to make moderate grip
5	Normal	Normal grip



**Fig. 1: Type I carpal malalignment**



**Fig. 2: Type II carpal malalignment**

The data was classified in two groups- one with ERLF less than 25 deg and second with ERLF more than 25 deg. Statistical analyses was done by paired t test. The value of significance was calculated for each parameter. The value was significant when  $p < 0.05$ . Features of complex regional pain syndrome were noted in 22 patients (Table 1-6).

**Table 1: Demographic data**

	ERLF <25	ERLF >25	p value
Total no. of patients	25	11	
Average age (years)	54.5	43.4	0.085
M:F (female %)	8:17 (65%)	5:6 (54%)	

**Table 2: Radial tilt**

	ERLF <25	ERLF >25	p value
Pre reduction RT (degrees)	-17.4	-17.03	0.92
6 wks Post reduction RT (degrees)	6.47	6.1	0.52
12 wks Post reduction RT (degrees)	2.12	4.45	0.30
Loss of radial tilt (degrees)	4.35	1.75	0.379

**Table 3: Radial length**

	ERLF <25	ERLF >25	p value
Pre reduction RL(mm)	4.28	9.27	0.000393
6 wks Post reduction RL (mm)	7	9.25	0.009
12 wks post reduction RL (mm)	7.21	9.09	0.013301

**Table 4: Radial inclination**

	ERLF <25	ERLF >25	p value
Pre reduction RI (degrees)	13.54	12.8	0.8355
6 wks Post reduction RI (degrees)	12.78	17.3	0.33
12 wks post	11.58	12.7	0.44

reduction RI (degrees)			

**Table 5: Ulnar variance**

	ERLF <25	ERLF >25	p value
Pre reduction UV (mm)	2.818	2.4	0.716
Post reduction UV (mm)	2.22	1.83	0.72

**Table 6: Functional data**

	ERLF <25	ERLF >25	p value
Dorsi flexion at 24 weeks (deg)	59.5	59.9	0.94
Palmar flexion at 24 weeks (deg)	57.8	60.9	0.102
Pronation at 24 weeks	61.5	70.9	0.355
Supination at 24 weeks	56.08	73.63	0.04

## Results

All the data were classified in two groups. Group 1 is ERLF < 25degrees (midcarpal instability) and group two is ERLF > 25degrees (radiocarpal instability). In our study male female ratio was 13:23. The average age was 54.5 years and 43.4 years in group 1 and 2 respectively (p value 0.085). Female preponderance was seen in both the groups.

Pre-reduction radial tilt (RT) was comparable in both the groups. Post reduction average radial tilt was 6.47 degrees and 6.1 degrees in group 1 and 2 respectively. At 12 weeks the reduction were lost and mean collapse was 4.35 degrees and 1.65 degrees in group 1 and 2 respectively (p = 0.379). The difference was insignificant.

Radial length showed significant difference in two groups. Pre reduction, at 6 weeks and at 12 weeks there was significant difference between two groups. Radial Inclination and Ulnar variance showed insignificant difference.

Comparing the functional status, data at 24 weeks were taken since a recovering wrist may show restriction in early part. Dorsiflexion was same in both the groups while palmar flexion was more restricted in group 1. The difference of palmar flexion was insignificant. Pronation and supination was found more restricted in group 1. The difference was significant for supination in group 1 in comparison to group 2 while it was insignificant for pronation. Incidence of CRPS was 40% in group 1 compared to 9.09% in group 2.

## Discussion

Incidence of CRPS in distal radial fractures has been reported in 8% to 15% of patients. It was reported more in elderly patients as well in psychological and psychiatric patients.<sup>(1)</sup> In our study the age difference

was insignificant in two groups. In our study, average age of patients with CRPS was 49.4 years.

Radial or palmar tilt of distal radius is usually 11-12 degrees. Due to dorsal comminution the distal articular surface faces dorsally and loss of correction is noted. Jenkins<sup>(7)</sup> showed that acute loss of radial height and radial tilt is due to dorsal comminution. He noted mean increase of 8.22<sup>0</sup> in dorsal angulation, mean loss of 5.61<sup>0</sup> in radial angulation and 3.26 mm of radial shortening. In our study we noted 4.35<sup>0</sup> and 1.65<sup>0</sup> loss of palmar tilt after correction in group 1 and 2 respectively. According to Jenkins this loss is due to initial comminution. The loss of correction was more in midcarpal instability group. The same group has more incidences of CRPS.

Taleisnik et al. in their study found loss of normal palmar tilt eventually lead to midcarpal instability and delayed wrist pain. They did corrective osteotomy in nine out of thirteen patients who had relief in symptoms after corrective osteotomy.<sup>(6)</sup> Similarly Gartland and Werley<sup>(8)</sup> concluded that residual dorsal tilt directly affects functional outcome as compared to other radiographic parameters. McQueen and Casper<sup>(9)</sup> concluded in their article on "Functional outcome of Distal End Radial fractures" that malunited colles' fracture results in significant functional deficit. This can be defined by carpal malalignment due to loss of palmar tilt. We found more loss of palmar tilt and high incidence of CRPS in group 1. Although the difference was insignificant, this may be an indirect evidence of severity of trauma and its association with midcarpal instability.

Average radial length is 12mm which is reduced in DER fractures due to axial compression. In a 30years follow up, Kopylov et al. reported high chances of distal radiocarpal and distal radio ulnar arthritis with axial compression. They recommended maintenance of radial height in young individuals to reduce wrist arthritis.<sup>(5)</sup> Adams found distortion of triangular fibro cartilage due to radial length discrepancy. He also reported intermediate changes due to decreased radial inclination and dorsal angulation.<sup>(10)</sup> Solgaard<sup>(11)</sup> and Batra & Gupta<sup>(3)</sup> concluded that radial length is more important factor affecting functional outcome as compared to palmar tilt and it should be restored primarily. In our study, group 1 has significant loss of radial length pre reduction and was less than 8mm post reduction. Since the difference of radial length was significant between groups, it can be concluded that CRPS is more likely in cases with less radial length.

In DER fractures median nerve injury is reported between 0% to 17%.<sup>(1)</sup> It is usually due to raised compartment pressure in carpal tunnel after trauma. This has been proved by Dresing et al.<sup>(12)</sup> in their prospective study on 56 patients. The carpal pressure was found to increase during reduction which decreased gradually. Risk of CRPS was high in late presenting cases.<sup>(12)</sup> In our study the average duration between

trauma and reduction was a day. Hence prolonged compression of median nerve was not the cause in our study. Hove LM<sup>(13)</sup> found compression neuropathy in 30 (5.5%) patients in a series of 542 conservatively treated patients. He found median nerve symptoms in 23(76.6%) patients and ulnar nerve symptoms in 5(24%) patients. Twenty six (86%) patients recovered conservatively in three months. Only five (16%) patients developed typical CRPS features. In our series including group 1 and 2, thirty percent patients developed CRPS. Acute Carpal Tunnel Syndrome (CTS) is due to severe injury. We had no case of acute CTS. Late median nerve neuropathy has been reported due to malunion, residual palmar displacement, median nerve impingement due to callus, prolonged immobilization.<sup>(1)</sup> We had 2 case (case no. 3) of late carpal tunnel syndrome. The patient had symptoms at 6 months and improved with analgesics and exercises by 9 months.

In midcarpal instability group, 18 (40.90%) patients developed CRPS who were treated with casts and 2 of 6patients (33%) developed CRPS those treated with operative procedure. In the radiocarpal instability group only 2 patients developed CRPS who was treated with cast and none developed CRPS treated with operation. Stoffelen and Broos<sup>(14)</sup> found in their study on 272 patients that those treated with plate fixation had no algodystrophy. All other treatment modality like closed reduction, Kapandji and external fixation had varying incidence of algodystrophy with no significant difference. We found that casting group has high chances of developing CRPS. It may be due to prolonged immobilization and lack of early exercises (Table 7).

**Table 7: Cast and CRPS**

	ERLF <25	ERLF >25	Total
MUA and cast	9/22 (40.90%)	1/10 (10%)	10
Operative intervention	1/3 (33%)	0/ 1 (0%)	1
Total	10	1	11

Pronation and supination activity are main function of forearm. At 24weeks the pronation was 61deg and 70deg (p value 0.355) whereas supination was 56.5deg and 72.2 (p value 0.04). We found both supination and pronation were restricted more in group 1 with supination more significantly restricted. This proves the severity of trauma and functional impairment more in group 1. Dorsiflexion and palmar flexion was comparable in both the groups. Bronstein et al.<sup>(15)</sup> in their cadaveric study showed that osseous malalignment and soft tissue contracture were the cause of forearm rotation deficit. Ulnar translation and significant radial shortening leads to loss of pronation in 47% cases and loss of supination in 29% cases. Fraser et al.<sup>(16)</sup> showed

in their cadaveric study that rotations are restricted when dorsal angulation exceeds 30deg and radial shortening exceeds 7.5mm.

### Conclusions

The results showed that the loss of radial tilt, loss of radial length, restriction of pronation and supination was high in midcarpal instability group. The same group also has high incidence of CRPS. We can conclude that midcarpal instability is due to high severity of trauma which may be one of the causes of complex regional pain syndrome. Also the group treated by manipulation and cast has high risk of complex regional pain syndrome. We recommend carpal instability to be kept in mind while deciding treatment in distal end radial fractures. Patients with midcarpal instability should preferably be treated by open reduction and fixation with early mobilisation.

### References

1. Campbell's Operative Orthopaedics. Editors S. Terry Canale and James H. Beaty; 13<sup>th</sup> edition: 2892-95.
2. Medoff R. Essential radiographic evaluation of distal radius fractures. *Hand clin* 2005;21(3):279-288.
3. Gupta A, Batra S, Jain P, Sharma SK. Carpal alignment in distal radial fractures. *BMC Musculoskelet Disord* 2002;3:14-20.
4. Lee J S, Gaalla A, Shaw R L, Harris J H. Signs of acute carpal instability associated with distal radial fracture. *Emergency radiology* 1995;2(2):77-80.
5. Kopylov P, Johnell O, Redlund- Johnell I, Bengner U. Fractures of the distal end of radius in young adults: a 30 year follow up. *J Hand Surg Br.* 1993;18(1):45-9.
6. Taleisnik J, Watson HK. Midcarpal instability caused by malunited fractures of the distal radius. *J hand Surg Am.* 1984;9(3):350-7.
7. Jenkins NH. The unstable colles fracture. *J Hand Surg Br.* 1989;14(2):149-54.
8. Gartland JJ Jr, Werley CW. Evaluation of healed Colles' fractures. *J Bone Joint Surg Am.* 1951;33-A:895-907.
9. Mcqueen M, Caspers J. Colles fracture: Does the anatomical result affect the final function? *J Bone Joint Surg (Br)* 1988;70(B):649-51.
10. Adams BD. Effects of radial deformity on distal radioulnar joint mechanics. *J Hand Surg Am.* 1993 May;18(3):492-8.
11. Solgaard S. Function after distal radius fracture. *Acta Orthop Scand* 1988;59(1):39-42.
12. Dresing K, Peterson T, Schmit – Neuerburg KP. Compartment pressure in the carpal tunnel in distal fractures of radius. A prospective study. *Arch Orthop Trauma Surg* 1994;113(5):285-9.
13. Hove LM. Nerve entrapment and reflex sympathetic dystrophy after fractures of the distal radius. *Scand J Plast Reconstr Surg Hand Surg* 1995;29(1):53-8.
14. Stoffelen D, Broos, Paul L.O. The importance of algoneurodystrophy in different options of distal radial fractures. *J Orthop Trauma* 2000;14(2):122-123.
15. Bronstein A, Heaton D, Tencer AF, Trumble ET Distal Malunion and Forearm Rotation: a cadaveric study. *J Wrist Surg.* 2014 Feb;3(1):7–11.
16. Fraser GS, Ferreira LM, Johnson JA, King GJ. The effect of multiplanar distal radius fractures on forearm rotation: in vitro biomechanical study. *J Hand Surg Am.* 2009 May-Jun;34(5):838-48.