

A study of soft tissue interface in implant removal cases

Anurag Chandrakar¹, Nitin Samal², Romil Rathi^{3,*}, Nupur Gupta⁴, Sanjay Deshpande⁵

¹Junior Resident, ²Associate Professor, ³Assistant Professor, ⁵Professor & Unit Head, Dept. of Orthopaedics, ⁴Senior Resident, Dept. of Ophthalmology, Jawaharlal Nehru Medical College, Wardha, Maharashtra

***Corresponding Author:**

Email: dr.romilrathi@gmail.com

Abstract

Aim: To study the soft tissue interface in implant removal cases.

Materials and Methods: Present study was carried out in Department of Orthopaedics of a medical college and attached tertiary care hospital during the period from August 2014 to August 2016. The study consisted of 104 indoor patients who came for implant removal either voluntarily or were advised implants removal. The metallic implant were examined for any deformation and also for evidence of corrosion at the time of implant removal. A note was made about the condition of the implant and the surrounding tissues. The interface tissue was separated from the parent bone and examined in relation to colour. It was sent for histopathology.

Observation and Results: Patients were studied with special reference to clinical, radiological and histopathological findings undergoing implant removal. Pain was the main cause of implant removal in our study. Pain at the site of implant could be allergic reaction which subsided on implant removal. Pain for prolonged period indicates presence of chronic inflammatory reaction at implant site. Implant corrosion was more on implant failure cases followed by case involved with infections. Fibrosis was seen in every removal case denoting it as a universal phenomenon. Commonest metallurgical cause attributable to implant breakage was corrosion.

Conclusion: When clinico-radiological and histo-pathological factors coincide then implant failure shows a cumulative relation. Corrosion and degradation of the implants in the body is one of the major issues resulting in the failure of biomedical devices. The degradation process may decrease the structural integrity of the implant, and the release of degradation products may elicit an adverse biological reaction in the host which was clinically evident as chronic pain, biomechanical failure of implant, infection and possibly non-union of the fractures.

Keywords: Soft tissue interface, Implant removal, Implant failure.

Introduction

For centuries, fractures healed naturally without surgery and implants. Later on, implants have come to play a more important role in orthopedic surgery. Gradually there has been development of metal appliances and instruments for bone surgery. Advances in metallurgy, biomechanics and surgical techniques have opened up broad areas of implant application. But due to anatomical and biological variations in patients, no two implant surgeries are exactly alike. An orthopedic surgeon depends on his knowledge of the basic sciences of biomechanics, surgical anatomy and physiology to develop a successful plan of action for a given implant application. It was later realized that living bone reacts to any foreign body such as metallic implant with reaction in the surrounding tissue. A variety of metals have been used for fracture fixation in the past even prior to 1856. The implants commonly used today are stainless steel, cobalt chromium alloys and titanium alloys. Studies and research today are being done to develop better, stronger and more durable materials for implants, but the dominating question in the use of all kinds of implant materials is how they react with the body tissues and how the body tissues react to them. Although implants are supposed to be made of biologically inactive materials, they may cause soft-tissue reactions.⁽¹⁾ Hence the study of tissue behavior to various implants is vital. Tissue reaction is a time related

phenomenon. Its severity is related to the shape and size of the implant, to the movement between the implant and the tissues, to the amount of corrosion and degradation of the implants, to the duration of implantation and finally to the biological activity of the host tissue to the products of the corrosion and degradation.⁽²⁾ In spite of marked advances in metallurgy and refined surgical techniques, many of these implants require removal from the body, on account of implant related problems. Very few studies have been done on soft tissue interface in orthopedics cases being treated by internal fixation by implants. In view of scanty nature of our knowledge of the effect of metal implants on surrounding tissues, it was decided to study soft tissue from implant tissue interface in cases undergoing elective implant removal in a tertiary care hospital attached to medical college.

Materials and Methods

Aim: To study the soft tissue interface in implant removal cases.

Objectives: 1) To analyze the patient profile who have undergone the implant removal surgery. 2) To analyze the local gross pathological finding at implant bone interface. 3) To study correlation of clinical and radiological findings with histo-pathological changes in the interface tissue.

Study design: It was a prospective type of study, carried out in Department of Orthopaedics of a medical college

and attached tertiary care hospital during the period from August 2014 to August 2016. The study consisted of 104 indoor patients who came for implant removal either voluntarily or were advised implants removal.

The following inclusion and exclusion criteria were used for recruitment of patients in this study.

Inclusion Criteria:

1. Patients of any age group who came to the hospital for implant removal.
2. Patients in whom implant removal was necessary due to pain, breaking of the implant, loosening of the implants, infection or implant failure.
3. Patients in whom fracture had united and surgeon advised the implant removal.

Exclusion Criteria:

1. Patient who underwent implant extraction due to Pathological fracture
2. Patients who were not willing to participate in the study.

The present study included the old operated patients who came to the Orthopaedic OPD of tertiary care hospital attached to the medical college for implant removal on their own or were advised implant removal by surgeon. After admission a detailed history was taken, patients were evaluated as per the Performa and findings were noted. Appropriate Antero-posterior and lateral radiographs were taken depending upon the site of implant. A detailed informed Consent was taken from all the patients enrolled in this study. The pre-anesthetic check-up and fitness for operative procedure were done.

The patients in the present study were grouped according to **Emneus and Stenram (1965)**⁽³⁾ classification as under:

Group I: Prophylactically extracted implants.

Group II: Fracture treatment failed probably because of reasons not directly related to the osteosynthetic materials.

Group II-A: Infection

Group II-B: Loosening

Group II-C: Delayed union or nonunion

Group III: Mechanical failure of implant with or without pain.

All the cases selected for implant removal for our study, underwent pain measurement using VAS scale. The patients were posted for elective implant removal under appropriate anesthesia and the implants were removed under all aseptic precautions. The metallic implant were examined for any deformation and also for evidence of corrosion at the time of implant removal. A note was made about the condition of the implant and the surrounding tissues. The interface tissue was separated from the parent bone and examined in relation to colour. It was sent for histopathology after preserving it in 10% formalin. The tissue in the department of pathology was processed and two sections from each block were obtained, one for routine H&E staining and the other one for turn bull reaction for iron and other type of reaction.

However, In Intramedullary Devices we were unable to collect the sample from fracture site so the samples were taken from the tip of the nail and its surrounding tissue, where as we collected the soft tissue sample from fracture site in case of plate removal.

Results and Observations

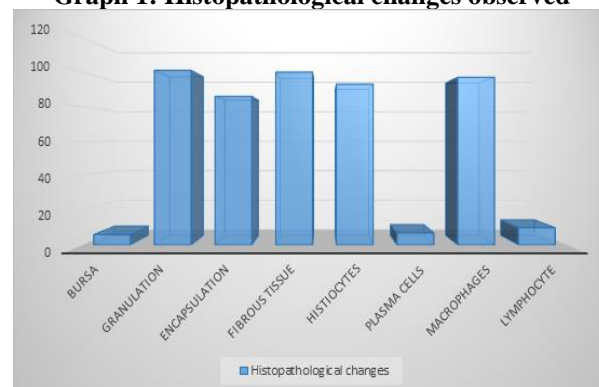
A prospective study was carried out on indoor patients in the department of Orthopaedics of a medical college and attached tertiary care hospital, from Aug 2014 to Aug 2016. Total numbers of cases recruited were 104 who underwent implant removal. After complete clinical, radiological and histopathological examinations following observations were made.

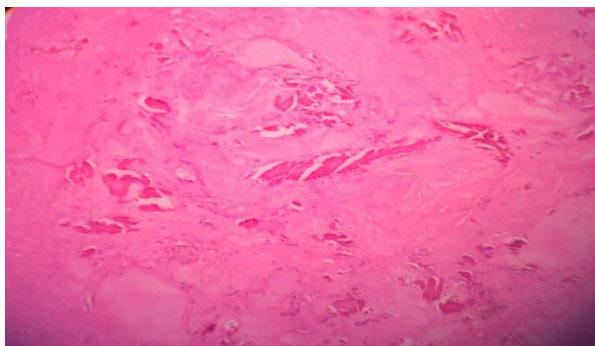
Table 1: Frequency distribution of histopathological changes

Histopathological changes	Frequency	Percent
Bursa	6	5.8
Granulation	101	97.1
Encapsulation	86	82.7
Fibrous tissue	100	96.2
Histiocytes	93	89.4
Plasma cells	7	6.7
Macrophages	97	93.3
Lymphocyte	10	9.6

In our study Bursa formation was seen in 5.8%, Granulation seen in 97.1%, Encapsulation seen in 82.7%, Fibrous tissue formation in 96.2%, Histiocyte formation seen in 89.4%, plasma cells were seen in 6.7%, Macrophages were seen in 93.3% and Lymphocyte were seen in 9.6%.

Graph 1: Histopathological changes observed





Histo pathological slide showing Osteoid formation

Table 2: Frequency Distribution on Pain

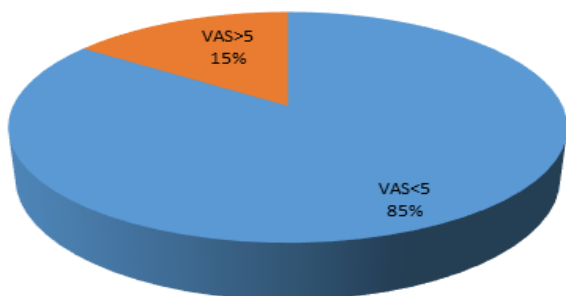
Pain Score	Frequency	Percent
VAS<5	88	84.6
VAS>5	16	15.4
Total	104	100.0

Patients were classified under two categories on the basis of visual analogue score (VAS)

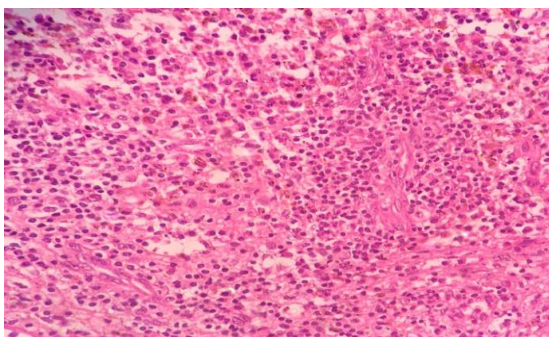
Group I - 88 patients (84.6%) in which VAS score was less than 5

Group II - 16 patients (15.4%) in which VAS score is more than 5

Graph 2: Pie chart on frequency distribution on pain
Pain Score



Patients were classified under two categories on the basis of visual analogue score (VAS) presented under pie chart here.



Histo pathological slide showing Neutrophils

Table 3: Frequency distribution on metal debris

Metal debris	Frequency	Percent
Type 1	88	84.6
Type 2	3	2.8
Type 3	13	12.5

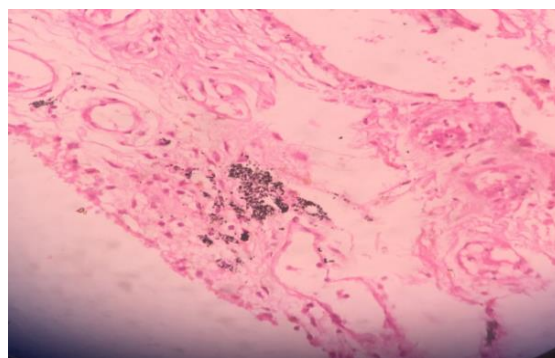
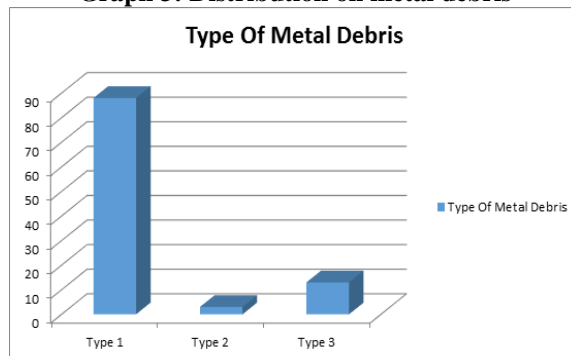
The metal Debris were divided into three types Type I, Type II and Type III.

Group I - 88 patients (84.6%)

Group II - 3 patients (2.8%)

Group III - 13 patients (12.5%)

Graph 3: Distribution on metal debris



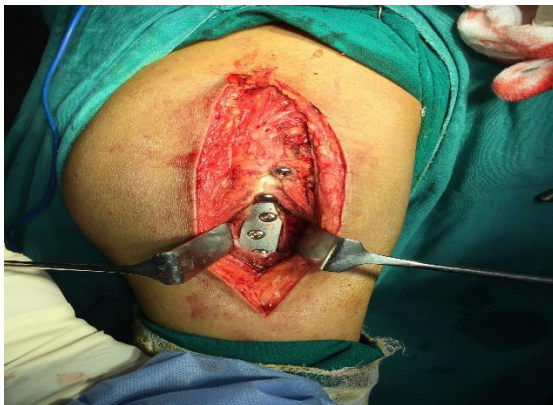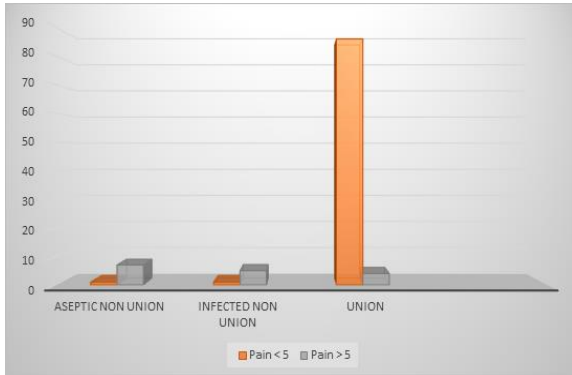
Histo pathological slide showing Foreign body

Table 4: Correlation between pain and final outcome

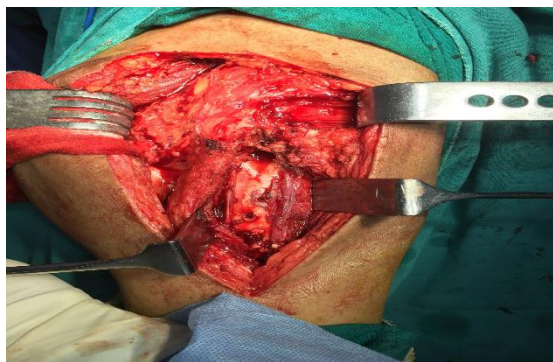VAS score	Aseptic non union	Infected non union	Union	Total
Pain < 5	1	1	86	88
Pain > 5	7	5	4	16
Total	8	6	90	104

In patients having pain score less than 5, union was observed in 97.7% cases and there was one case each of aseptic nonunion and infected nonunion. In patient having pain score more than 5 union was achieved in 25% of cases and 43% patients having aseptic non-union and 31% were having infected non-union. Hence, the severity of pain and final outcome was found to be statistically significant (p value 0.00).

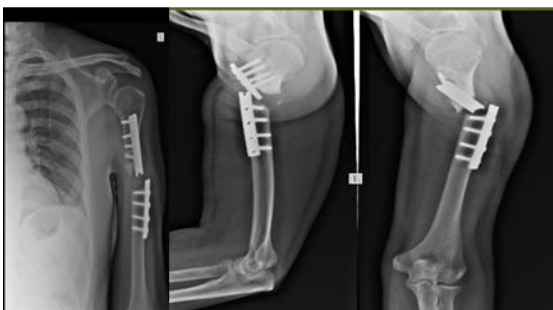Graph 4: Correlation between Pain and Final outcome



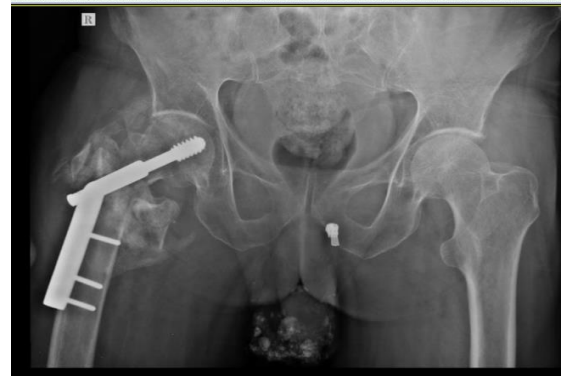Intraoperative picture of implant removal



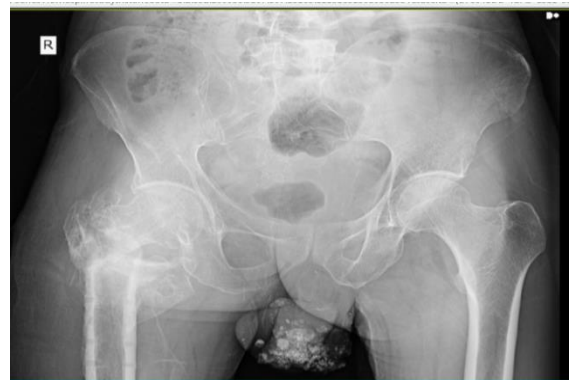Post implant removal picture



X-ray 1: Peri-implant fracture of shaft humerus left side (dynamic compression plate used)



X-ray 2a: Pelvis with both hip showing old operated case of fracture intertrochanteric femur right side, fixed with dynamic hip screw



X-ray 2b: Pelvis with both hip after implant removal

Discussion

There were 104 patients in our series who underwent implant removal. Patients were studied with special reference to clinical, radiological and histopathological findings undergoing implant removal. This study was done in an attempt to understand the role of interface tissue reaction, histopathological consequences and its relation with the clinical outcome. The mean age of the patient enrolled in our study was 36.83 with ± 6.293 (Range 3 – 85 years). This was comparable to a study conducted by **Onche II et al**⁽⁸⁹⁾ on 47 patients of implant removal the mean age observed was 31.6 ± 13.4 years and in study conducted by **H. French et al**⁽²²⁾ on 11 patients, the mean age was 28.8 years. (Range 4 – 61 years).

Soft Tissue color changes and interface tissue reaction - Color changes of interface tissue were studied and patients were divided into 3 groups:

Group I - 25 patients (24.03%) shows presence of yellow interface tissue

Group II - 64 patients (61.53%) shows presence of Brownish color interface tissue

Group III - 15 patients (14.42%) shows presence of Blackish color interface tissue

Laing 1973⁽³⁾ in his study had observed that most of the failures causing implant removal were due to infection, loosening, non - union and it was not due to implant

material and tissue response, Also in a study conducted by **Jamil et al**⁽⁷¹⁾ in 2008 on implant removal found that the indications for implant removal in symptomatic patients were pain, implant loosening, infection, broken implants, skin irritation, peri-prosthetic fractures and functional limitation.

Interface tissue reaction: On studying the color changes in our included patients at the interface, 3 types were observed. Brown being the most common, seen in 64 patients (61.43%). Yellow in 24.03% and black in 14.42% patients respectively. **Fornasier et al**⁽⁷⁾ (1994) observed that the tissue removed from the proximity of metal implant showed discoloration when examined with naked eye. Section taken perpendicular to the surface of the implant showed decreasing amount of discoloration when moving away from the surface of the implant into the adjacent tissue. **Mathiesen et al.**⁽⁹³⁾ reported extensive necrosis of periprosthetic tissue due to metal toxicity in association with four of nine cobalt-chromium-alloy.

Histopathological analysis: In our study, histopathological analysis of 104 patients was done and it was observed that 101(97.1%) patients had granulation tissue formation being the maximum followed by fibrous tissue formation in 100 patients (96.2%), macrophages in 97 patients (93.3%), histiocytes in 93 patients (89.4%) and encapsulation in 86 (82.7%) patients. 10 patients had lymphocytes, 7 had plasma cells and 6 had bursa formation. Whereas **Prakash et al (1996)**⁽³⁰⁾ also studied the interface tissue response to implant and found neutrophilic infiltration and granulation tissue to be a constant feature. Lymphocytes were present and distributed among all groups of patients. Giant cells formation was uncommon finding.

The histopathological study of the interface tissue is a useful tool to find out the implant related problem and also look closely at the biological response of the tissue to the implant. In our study Fibrosis were seen in 98.1%, Necrotic hemorrhagic cells were seen in 12.5%, Siderosis was seen in 6.7% which was comparable to study done by **Mody and Hugeness (1994)**⁽²⁹⁾ who carried out an interesting histological study on spinal implants of 36 patients undergoing elective spinal hardware removal, and found fibrous tissue hypertrophy in all specimens (100%). Unique cell layers of histolytic origin were seen along with iron containing metal debris. **Evan et al (1974)**⁽¹⁷⁾ had also reported the formation of a fibrous tissue barrier when implant goes into corrosion or wear. Fibrous tissue interface represent the tissue response of the metal. It is the universal response elicited by metallic implants as a repair of its damage. **Skinner et al (1980)**⁽²⁰⁾ gave a histopathological grading of tissue reaction in relation to implant surface. They stated that severe chronic inflammatory response was found to be associated with giant cells and necrosis whereas necrotic haemorrhagic cells were found to be 12.5%.

In our study pain was evaluated using Visual analogue score and were classified under two groups

with VAS score less than 5 and VAS score more than 5, VAS less than 5 was observed in 88 patients (84.6%) and more than 5 was seen in 16 patients only (15.4%). **French et al (1987)**⁽²²⁾ evaluated the interaction of osteosynthetic plates to adjacent tissue. All patients with pain adjacent to the implant were relieved by implant removal. This indicates that in some group of patients, pain in the area of the implant may be caused by an allergic reaction which subsides on implant removal. This finding was corroborated by **Minkowitz et al**⁽⁹⁴⁾ who found a significant improvement in pain scores decreasing from mean of 5.5 to 1.3 in their study. They also found an overall improvement of 76% at one year of follow up.

Metal debris with final outcome: In our study Metal debris were present in patients and according to the quantity it is classified under three groups. Group I consisting 88 patients (84.6%) in which metal debris are low in numbers. Group II consisting of 4 patients (3.8%) were having metal debris medium in number. Group III consisting of 13 patients (12.5%) who were having good amount of metal debris.

In a study conducted by **J D Witt et al**⁽⁹⁵⁾ on 13 patients showed histology Tissue reaction in response to the metal-wear debris may have contributed to the early failure of these implants. **Mody and Hugeness (1994)**⁽²⁹⁾ carried out an interesting histological study on spinal implants of 36 patients undergoing elective spinal hardware removal, and found fibrous tissue hypertrophy in all specimens. Unique cell layers of histolytic origin were seen along with iron containing metal debris.

Jacobs et al (2003)⁽³³⁾ reported the long term effect of implant materials, and found the tendency of metallic component to undergo electrochemical corrosion resulting in degradation. Debris of these products when present in sufficient amount cause corrosion and induces the formation of granulation tissue.

In our study of 104 patients of implant removal, fracture union after implant removal was evaluated. The findings were classified under 3 groups. Group 1 of (Aseptic non-union) consisted of 8 patients (7.7%). Group II of (Infected non-union) consisted of 6 patients (5.8%) Group III consisted of (union of fracture) 90 patients (86.5%).

Pain and final outcome: In patients having pain score less than 5, union was observed in 97.7% of cases and there was one case each of aseptic non-union and infected non-union. Where as in patient having pain score more than 5, union was observed in 25% of cases and 43% patients were having aseptic non-union and 31% were having infected non-union. So the severity of pain and final outcome was found to be statistically significant (p value 0.00)

Summary and Conclusion

Corrosion and degradation of the implants in the body is one of the major issues resulting in the failure of biomedical devices. The degradation process may

decrease the structural integrity of the implant, and the release of degradation products may elicit an adverse biological reaction in the host which was clinically evident as chronic pain, biomechanical failure of implant, infection and possibly non-union of the fractures. However, the types of debris may be closely correlated with the presence of infection, chronic inflammatory reaction leading to long standing pain and mechanical disintegration of implants. In clinical terms, the biggest improvements could be made by surface modification of 316L stainless steel, and hard coatings of alloy could have great potential to improve the biomechanical performance characteristics of implants and improving the lives of their recipients. The following conclusions are drawn based on this study in relation to objectives decided for the study.

1. Male female ratio was 3.5:1. Mean age of the patient was 36.83 years. More than one third patients were smokers.
2. On gross examination of implant bone interface granulation tissue seen was brown in colour in 62%, yellow in 24% and blackish in 14% respectively.
3. Histologically type I metal debris consisting of small particles was seen in the maximum number of patients. Prominent cells seen were histiocytes and macrophages. All the interface tissue showed prominently feature of fibrosis. No definite correlation between the clinico-radiological and histo pathology could be found.

Pain was the main cause of implant removal in our study. Pain at the site of implant could be allergic reaction which subsided on implant removal. Pain for prolonged period indicates presence of chronic inflammatory reaction at implant site. Implant corrosion will be more on implant failure cases followed by case involved with infections. Fibrosis was seen in every removal case denoting it as a universal phenomenon. Commonest metallurgical cause attributable to implant breakage was corrosion. When clinico-radiological and histo-pathological factors coincide then implant failure shows a cumulative relation. An in depth and expanded analysis of orthopedic osteosynthetic implants is needed to know definite and wider aspects of soft tissue interface.

Reference

1. Jacobs JJ, Skipor AK, Black J, Urbam RM, Galante JO. Release and excretion of metal in patients who have a total hip replacement component made of titanium-base alloy. *J Bone Joint Surg* 1991;73-A:1475-1486.
2. Il Onche, O.E. Osagie Removal of orthopaedic implants: indications, outcome and economic implications, *J West Afr Coll Surg*. 2011 Jan-Mar;1(1):101-112.
3. French HG; Cook SD, Haddad RJ (Jr.). Correlation to tissue reaction in osteosynthetic device. *Jr. Biomedical Material Research*.1984;18(7):817-828.
4. Laing PG, Compatibility of biomaterial, *Orthopedic Clinics of North America*.1973;4(2):249-273.
5. Jamil W, Allami M, Choudhury MZ, Mann C, Bagga T, Roberts A. Vol. 3. 39;2002. Do orthopaedic Surgeons need a policy on the removal of metalwork? A descriptive national survey of practising surgeons in the United Kingdom; pp. 362-367.
6. Fornasier VL. The pathology of prosthetic implants-bone implant interface, Year book 1st edition Published by Cameron H .V. Mosby Publication. St. Louis, Missouri. 1994;29.
7. Mathiesen EB, Lindgren JU, Blomgren GG, Reinholt FP. Corrosion of modular hip prostheses. *J Bone Joint Surg Br*. 1991 Jul;73(4):569-75.
8. Prakash et al (1996) Prakash S. Malik AC, Raj GA, Rao KSA. Histopathology analysis of interface tissue retrieved at the time of implant extraction. *Indian journal of Orthopedics*.1996;30:150-154.
9. Mody and Heggeness (1994) Mody, D. R.; Esses, S. I.; and Heggeness, M. H.: A histologic study of soft-tissue reactions to spinal implants. *Spine*, 19:1153-1156,1994.
10. Evans EM, Swansea, Wales, Freeman, MAR, Miller AJ, Veron-Roberts B. Metal sensitive as a cause of bone necrosis and loosening of the prosthesis in total joint replacement. *Jr. of bone and joint surgery*. 1974;56(4):626-642.
11. Skinner H, Weinstein AM, Clemon AJT, Mc Philips Meade M, Klawitter J French. Corrosion metal characteristics and local tissue reaction associated with osteosynthetic devices in implant retrieval. *Material and biological analysis* ED. Weinstein Gibson, Brownand Ruff NBS.1980;604:423-447.
12. Minkowitz RB, Bhadsavle S, Walsh M, Egol KA. Removal of painful orthopaedic Implants after fracture union. *J Bone Joint Surg*. 2007;89:1906-1912.
13. Witt. J.D, M. Swann. Metal wear and tissue response in failed Titanium alloy Total hip replacements. *J Bone Joint Surg[Br]* 1991; 73-B:559-63).
14. Jacobs et al (2003) Jacobs JJ, Hallab NJ, Skipor AK, Urban RM. Metal degradation product a cause for concern in metal-metal bearings. *Clinical Othopedics & Related research*.2003;417:139-147.