

Lichen striatus with coexistent onychodystrophy - a rare entity

Sonia Raghukumar¹, Ravikumar B.C^{2,*}

¹Postgraduate, ²Professor, Dept. of Dermatology Venerology & Leprosy, Hassan institute of medical sciences, Karnataka

***Corresponding Author:**

Email: dr.ravikumarbc@gmail.com

Abstract

Lichen striatus is an asymptomatic, benign, self-limiting condition occurring in children and young adults presenting as grouped skin colored papules in a linear fashion. Nail involvement is a rare finding and when present, often involves a portion of the nail and shows a protracted course. Here, we report a case of total nail involvement in one such case.

Keywords: Lichen striatus, Onychodystrophy

Introduction

Lichen striatus (LS) is an uncommon, asymptomatic, self-limiting, linear dermatosis of unknown origin that usually occurs along Blaschko's lines on the extremities.⁽¹⁾ It is a benign condition that primarily affects children and is relatively rare in adults.^(2,3)

Nail involvement need not necessarily be associated with skin lesions and can also be an isolated finding.⁽⁵⁾ These changes may appear before, after or concurrently with cutaneous lesions.⁽⁶⁾ We herein report a case of lichen striatus presenting with total onychodystrophy of the affected nail.

Case Report

A five year old girl presented for evaluation of an asymptomatic linear rash over the right upper limb and acquired onychodystrophy of the right thumb. The skin eruption started 3 months ago and was followed by involvement of nails 4 weeks later.

Cutaneous examination revealed a linear array of 1-4mm skin-colored flat topped papules and plaques, some surmounting thin scales, involving the medial aspect of the dorsum of the right hand extending to the thumb up to the periungual area.

The corresponding thumb nail displayed a brownish-yellow discoloration, splitting, longitudinal ridging, onychorrhexis and onycholysis (Fig. 1).

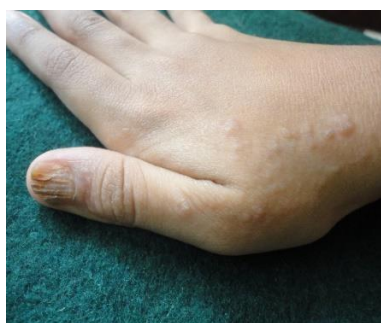

Fig. 1: Nail lichen striatus showing onychorrhexis, brown discoloration and onycholysis

Examination of the other fingernails and toenails was unremarkable.

A 3mm punch biopsy from one of the cutaneous papules revealed a thinned out epidermis with vacuolization of cells and elongation of rete ridges. Dermis showed edema of the upper and deep dermis with lymphoplasmacytoid infiltration in the upper dermis. In one focus, infiltrate was seen around the appendages. (Fig. 2)

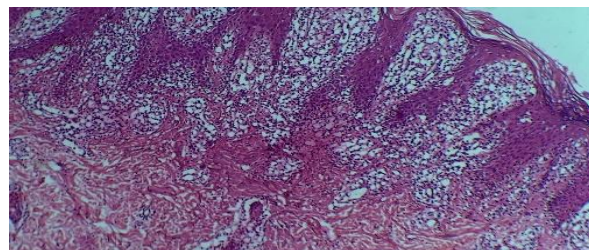


Fig. 2: Histopathology of skin showing thinning of epidermis, elongation of rete ridges and lymphoplasmacytoid infiltrate

Nail biopsy was refused. Besides, the diagnosis of LS is usually based on the presence of typical skin lesions.⁽⁴⁾ A Diagnosis of LS with nail dystrophy was made and the child was started on topical tacrolimus 0.1% ointment. A considerable improvement was observed in the six month follow up period (Fig. 3).




Fig. 3: Improvement following six months of treatment

We are reporting this case due to its rarity in literature and due to the peculiarity of the nail characteristics presented with.

Discussion

The etiology of LS remains obscure. Environmental triggers such as trauma or infection, genetic predisposition and autoimmune response have been postulated to be involved.⁽⁷⁾ LS presents as unilateral, asymptomatic (rarely pruritic) flesh-colored to red-brown flat topped papules and must be differentiated from lichen planus, linear localized neurodermatitis, linear psoriasis (almost always associated with typical lesions of psoriasis elsewhere on the body), linear keratosis follicularis (histologically typical of Darier's disease) and linear epidermal nevus which occasionally does not appear at birth but later in life and may present nail involvement.⁽⁶⁾

Nail involvement in LS is uncommon.⁽⁴⁾ Fewer than 40 cases of LS with nail involvement have been reported so far. Owing to which the number of reports on the characteristics of nail LS is limited.⁽¹⁾ The upper limb is favored, and thumb nail more frequently involved.⁽³⁾ Longitudinal ridging, longitudinal splitting, onycholysis, nail plate overcurvature, nail plate thinning, nail pitting, punctate or striate leukonychia, and nail bed hyperkeratosis may be the presenting features.⁽³⁾ These changes are attributed to the inflammation involving the nail matrix, leading to abnormal keratin synthesis.

Criteria for diagnosis include- longitudinal ridging and splitting localized to one portion of the nail, single nail involvement and presence of skin lesions near the nail.⁽⁴⁾ However, contrarily, the nail in our patient showed no such predilection for localization, and was involved in entirety.

LS although being self-limiting, when associated with nail changes follows a protracted course ranging from 6 months to 5 years.⁽¹⁾ Isolated cases may be treated with emollients alone. Topical corticosteroid creams may be employed to combat pruritus and dryness if any. Tacrolimus ointment 0.1% has been found to be effective in the treatment of nail LS⁽¹⁾ and triamcinolone acetonide intralesional injection may be tried for adults.⁽¹⁾

Conclusion

Nail involvement in LS is perhaps an underdiagnosed and undertreated condition and must be looked for in cases of LS especially those involving the dorsum of feet and hands.

References

1. Miri K, Hwa Y J, Young S E, Baik K C, Hyun J P. Nail lichen striatus: report of seven cases and review of the literature. *Int J Dermatol.* 2015;54:1255-60.
2. Laura P, Eulàlia B, Joan D, Esther R, Maria M C, Agustín A. Lichen striatus: clinical and epidemiological review of 23 cases. *Eur J Pediatr* 2006;165:267–269.
3. Shilpa YK, Sudir kumar NR, Periswamy V. Lichen striatus with onychodystrophy in an infant. *Indian Dermatol Online J.* 2015;6:333-5.
4. Inamadar AC. Lichen striatus with nail involvement. *Indian J Dermatol Venereol Leprol.* 2001;67:197.
5. Tosti A, Peluso AM, Misciali C, Nortna C. Nail lichen striatus: clinical features and long-term follow-up of five patients. *J Am Acad Dermatol.* 1997;36:908-13.
6. Baran R, Dupré A, Lauret P, Puissant A. Lichen striatus with nail involvement. Report of 4 cases and review of the 4 cases in the literature (author's transl). *Ann Dermatol Venereol.* 1979;106:885-91.
7. Amer A. Bilateral onychodystrophy in a boy with a history of isolated lichen striatus. *Cutis* 2014;94:16-19.