

Relevance of fetal echocardiography screening in antenatal women: An Observational Study

Mendiratta S¹, Singh P², Seervi S³

¹ Senior Resident, PGIMER & Dr. Ram Manohar Lohiya Hospital, New Delhi

² Professor, PGIMER & Dr. Ram Manohar Lohiya Hospital, New Delhi

³ Junior Resident, PGIMER & Dr. Ram Manohar Lohiya Hospital, New Delhi

Abstract:

Aims and Objectives: To assess the efficacy of fetal echocardiographic examination in antenatal women to diagnose structural and functional heart disease.

Materials and Methods: A prospective cohort study of 600 antenatal women was performed; 227 low-risk and 373 high-risk women were evaluated. High-risk factors were hypothyroidism, diabetes, heart disease, Rh negative pregnancies, preeclampsia, SLE, sickle cell anemia, thalassemia and tuberculosis. All women had detailed fetal echocardiographic examination at 20-24 weeks gestation. Accuracy of fetal echocardiography was evaluated from neonatal outcome at birth and after six months.

Observation & Results: Two percent antenatal women had echocardiographic findings suggestive of fetal heart disease (1.7% of low-risk and 2% of high-risk). Major congenital heart disease on echocardiography, was suspected in two women of high-risk group, which was further confirmed in neonatal period. Eight fetuses were suspected with minor cardiac abnormalities. However, after birth three of them were found to be normal and 5 neonates needed to be kept under follow-up for confirmation or spontaneous resolution.

Conclusion: Fetal echocardiography is suggested in high-risk pregnancy for exclusion of congenital heart disease. It should be offered to low risk antenatal women also.

Introduction

Cardiac defects are the most common structural abnormalities seen at birth with prevalence of 8 per 1000 live births. It has been shown that prenatal detection of congenital heart disease may reduce perinatal mortality. It provides the opportunity to discuss the findings with parents, describe the obstetric management plan, and raise the possibility of termination if appropriate. Fetal echocardiography has evolved over the past three decades from a basic diagnostic tool in pediatric cardiology and obstetrical medicine to its own, vibrant tool that encompasses prenatal diagnosis, counselling, prenatal therapies and perinatal and neonatal management planning for various fetal cardiovascular abnormalities(1). Till date many structural heart diseases have been diagnosed during antenatal period and the details of the cardiovascular anatomy defined including detailed evaluation of systemic and pulmonary venous connections and aortic and ductal arch position relative to the trachea(2). Most of these results are quite comparable to post natal conditions.

Aims and Objectives

Aim of the study was to assess the efficacy of fetal echocardiographic examination in antenatal women to diagnose structural and functional heart disease. It was done to provide an opportunity to discuss with parents, in case of any structural cardiovascular anomaly and to intervene as early as possible after delivery if needed. The goal was to achieve a better neonatal outcome and an increased survival rate.

Materials and methods

A prospective cohort study was undertaken at Dr. Ram Manohar Lohia hospital, New Delhi between June 2011- December 2012. Total 600 antenatal women were enrolled for the study. These women were grouped into low-risk and high-risk group according to presence or absence of high risk factors. Total 227 low-risk and 373 high-risk women were evaluated. All women had detailed fetal echocardiographic examination at 20-24 weeks gestation. Accuracy of fetal echocardiography was statistically evaluated from neonatal outcome at birth and follow-up

till six months. Maternal high risk factors included acquired or congenital cardiac disease, medical disorders (eg. diabetes, preeclampsia, PKU, hypothyroidism, anaemia), exposure to teratogens, TORCH infection, autoimmune disease (eg, SLE, Sjo"gren's), epilepsy and IVF conception.

Obsevation's & Results

Two percent antenatal women had echocardiographic findings suggestive of fetal heart disease (1.7% of low-risk and 2% of high-risk). Major congenital heart disease on echocardiography, was suspected in two women of high-risk group, which was further confirmed in neonatal period. Eight fetuses were suspected with minor cardiac abnormalities. However, after birth three of them were found to be normal and 5 neonates needed to be kept under follow-up for confirmation or spontaneous resolution.

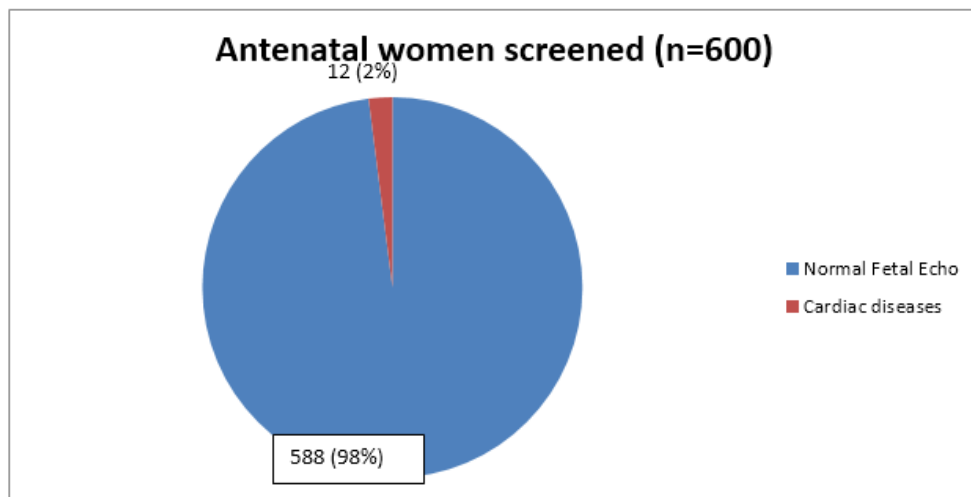


Fig. 1: Two percent (12 women) antenatal women had echocardiographic findings suggestive of fetal cardiac disease

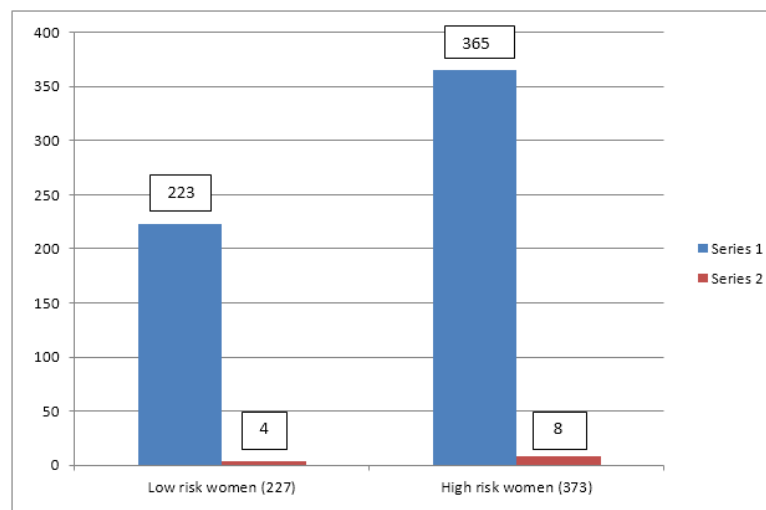


Fig.2: In low-risk women incidence of cardiac disease suspected by fetal echocardiography is (1.7%), whereas in high-risk women (2%)

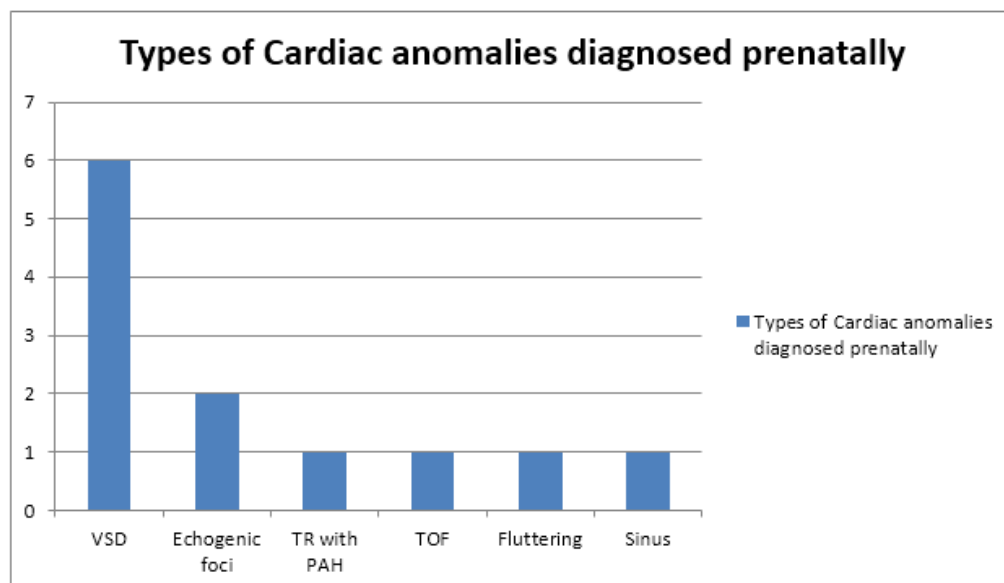


Fig.3: Types of cardiac anomalies diagnosed prenatally

Table 1: Distribution of high-risk factors

Sr. No.	High-risk factor	Total	Percentage	Cardiac anomaly on Echo
1	Pre-eclampsia	50	13%	-
2	Anemia	35	9%	1
3	Diabetes	33	8%	3
4	Bronchial asthma/Tuberculosis	10	2.6%	-
5	Epilepsy	5	1.3%	-
6	Maternal heart disease	5	1.3%	-
7	Hypothyroidism	170	45%	4
8	Collagen disease (SLE)	1	0.26%	-
9	Maternal Infections (TORCH)	23	6.1%	-
10	Positive triple test	6	1.6%	-

Table 2: Postnatal confirmation of detected anomalies

Antenatal fetal ECHO	Total number of patients	Post natal abnormalities
VSD	6 (50%)	Yes
TOF	1 (8.3%)	Yes
TR and PAH	1 (8.3%)	Yes
Echogenic foci in left ventricle	2 (16.6%)	No
Sinus bradycardia	1 (8.3%)	No
Fluttering foramen ovale	1 (8.3%)	No

Discussion

Screening for prenatal diagnosis of CHD using fetal echocardiography is important as it allows both detailed counseling of families after a prenatal diagnosis of CHD, and better perinatal and neonatal outcome as the neonate with a significant cardiac lesion will benefit from delivery at a tertiary care center where the paediatric cardiologists and cardiac surgeons are readily available(3). It should also be mentioned that a negative fetal echocardiography would assure parents who had had a previous child with CHD. The results of this study suggest that whenever there is a normal appearing heart on fetal echocardiogram, the newborn is likely to be normal at birth. (NPV=100%). The incidence of cardiac disease in low-risk and in high-risk women was similar to that observed by Bronshtein M (1993) which was further ascertained by Hagemann L et al (2004)(4). It is also observed that rate of cardiac malformation between two groups was not significantly different. Calculated Sensitivity, specificity, PPV and NPV were similar to that proclaimed by Khoo S (2008) (5).

Conclusion

Fetal echocardiography is suggested in high-risk pregnancy for exclusion of congenital heart disease. It should be offered to low risk antenatal women also. It provides an opportunity for thorough counseling of parents, enables them to take informed decisions regarding productive options and hence avoidance of cesarean section in cases of term pregnancy with lethal CHD. Recognition of structural and functional heart lesions provides a chance for delivery at a tertiary care center where the paediatric cardiologists and cardiac surgeons are readily available and improves both perinatal and neonatal outcome.

References

1. Lisa K. Hornberger, Anita J. Moon – Grady and Wayne Tworetzky, Fetal Echocardiography and perinatal cardiovascular interventions- An update, Journal of clinical and experimental cardiology,2012
2. Gottliebson WM, Border WL, Franklin CM, Meyer RA, Michelfelder EC (2006) Accuracy of Fetal Echocardiography: A cardiac segment specific analysis. Ultrasound Obstetr Gynecol 28:15- 21.
3. Nuruddin Badruddin et al, Evolution of fetal echocardiography as a screening tool for prenatal diagnosis of congenital heart disease, J Pak Med Assoc, September 2011.
4. Hagemann L, Zielinsky P, Alegre P. Arquivos Brasileiros de Cardiologia - Population Screening of Fetal Cardiac abnormalities through Prenatal Echocardiography in Low-Risk Pregnancies in the Municipality of Porto Alegre Volume 82, N° 4, Abril 2004

5. Khoo NS, Van Essen P, Richardson M et al – Effectiveness of prenatal diagnosis of congenital heart defects in South Australia: a population analysis. *Aust N Z J Obstet Gynaecol* 2008; 48(6):559-563