

Valsalva retinopathy managed surgically by 25 gauge pars plana vitrectomy: A case report

Manmath Das¹, Abhishek Varshney^{2,*}, Priyanka Chaudhary³

^{1,2,3}Vitreoretina Services, CL Gupta Eye Institute, Moradabad

***Corresponding Author:**

Email: doctorabhishekvarshney@gmail.com

Abstract

We report a case of unilateral valsalva retinopathy caused by severe coughing who presented to us with the complaints of sudden, painless loss of vision in the right eye (RE) for 1 week. Her presenting visual acuity for distance was 20/200 for RE. Fundus examination of RE revealed pre-retinal haemorrhage (PRH). Left eye (LE) fundus examination was normal. A diagnosis of valsalva retinopathy in RE was made and the patient was subjected to 25 gauge pars plana vitrectomy (PPV) with complete visual recovery.

Keywords: Coughing, MIVS, Nd:YAG hyaloidotomy, Valsalva retinopathy

Introduction

Valsalva retinopathy is a form of pre-retinal haemorrhage (PRH) that was described by Duane in 1972 as “a particular form of retinopathy, pre-retinal and hemorrhagic in nature, secondary to a sudden increase in intrathoracic pressure”.⁽¹⁾ It has been described after activities such as coughing, vomiting, lifting, straining for a bowel movement, strenuous exertion, sexual intercourse, labor, blowing musical instruments, compression injuries, endoscopic procedures (colonoscopy and gastroscopy). Treatment consists of either observation or Nd:YAG hyaloidotomy or pars plana vitrectomy (PPV). With the advent of micro incision vitreous surgery (MIVS), PPV is becoming a viable option for valsalva induced PRH. We report a case of unilateral valsalva retinopathy caused by severe coughing in a young healthy female and its management by PPV.

Case Report

A 20 year old healthy female presented to us with the complaints of sudden onset of decrease in vision in RE for 1 week after severe coughing. There was no history of vomiting, lifting heavyweights, sneezing, straining during micturition or defecation. The patient did not give history of any diagnostic or surgical intervention in the recent past. LE examination was unremarkable. RE best corrected visual acuity (BCVA) was 20/200 for distance and N36 for near, anterior segment examination was normal. Fundus examination of the RE showed an attached retina, dome shaped pre-macular hemorrhage with a glistening surface and regular margins suggesting sub internal limiting membrane (ILM) hemorrhage and a dull crescent with irregular margins inferior to it suggesting a sub hyaloid hemorrhage (Fig. 1). Optical coherence tomography (OCT) was performed that revealed sub ILM location of blood (Fig. 2). Options of observation, Nd:YAG hyaloidotomy and surgery was given to the patient. The patient was keen for her

visual recovery so Nd:YAG hyaloidotomy was tried but was unsuccessful. Following failure of hyaloidotomy, choice of PPV was given to the patient explaining the potential risks of surgery. A 25 gauge PPV was planned. Posterior vitreous detachment was completely achieved, ILM was incised by 25 gauge micro vitreoretinal (MVR) blade and was peeled off using 25 gauge ILM peeling forceps. PRH was then aspirated using soft tip aspiration flute (Fig. 3). Post-operative period was uneventful. Visual acuity showed improvement on day 1 after surgery and was 20/20 for distance by 1st week. At final examination after 6 weeks her BCVA both eyes was 20/20, N6, anterior segment examination was normal and LE fundus examination was also normal. RE fundus examination showed an attached retina (Fig. 4). 6 months post operatively patient was doing well with no visual complaints.

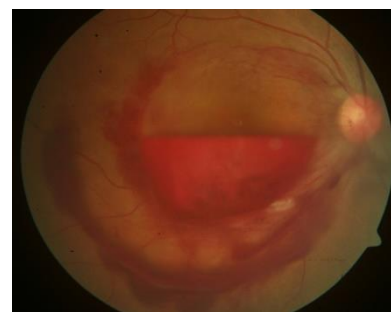


Fig. 1: RE fundus photograph at presentation

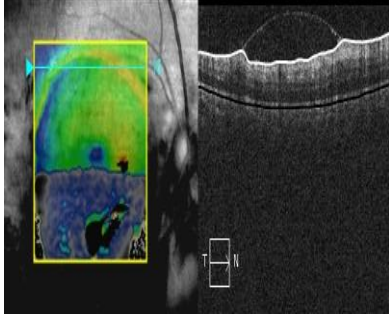


Fig. 2: RE OCT image showing ILM separation due to hemorrhage

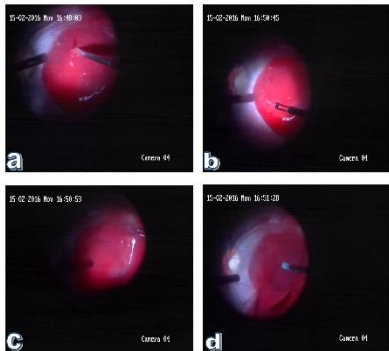


Fig. 3: Intra-operative sequential photographs showing ILM peeling and aspiration of hemorrhage

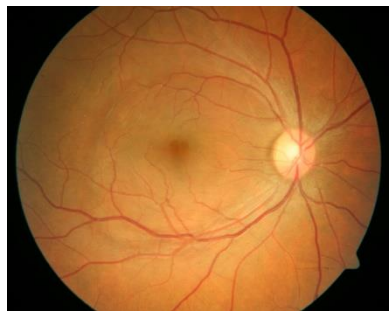


Fig. 4: RE fundus photograph 6 weeks post operatively

Discussion

Since its description by Duane in 1972⁽¹⁾ many causes of valsalva retinopathy and its treatment strategies have been described. It has been described secondary to activities like coughing, vomiting, lifting, straining for a bowel movement, strenuous exertion, sexual intercourse, labor, blowing musical instruments, compression injuries, night club dancing, endoscopic procedures (colonoscopy and gastroscopy).

Clinically PRH of valsalva has been described as a well circumscribed, round or dumbbell shaped bright red mound of blood beneath the ILM in or near the central macula with a glistening surface.⁽²⁾ Sub ILM location of the pre retinal hemorrhage has been confirmed on OCT.⁽³⁾ It has also been mentioned that

if the site of hemorrhage is near the fovea, blood can dissect the fovea and can reach sub-foveally.⁽²⁾ Choroidal hemorrhage in moderate myopia has also been described following valsalva maneuver.⁽²⁾ Complete resolution of PRH usually occurs but it may take months, leaving the serous detachment of ILM which may reattach spontaneously.⁽²⁾ Nd:YAG hyaloidotomy is usually successful, if the patient presents early. A higher amount of energy is required in this process (4.2mJ to 9.2 mJ). This can lead to photomechanical injury to the retina leading to vitreous hemorrhage, intraretinal hemorrhage or subretinal hemorrhage.⁽⁴⁾ Apart from that occasional epiretinal membrane formation has also been described.⁽⁵⁾ Though PPV has associated risks of surgery like early cataract formation and retinal breaks, but is emerging as an effective and safer technique for the management of dense pre-macular haemorrhages and insufficient spontaneous reabsorption.^(6,7) Other therapeutic modalities described are intravitreal gas injection in conjunction with recombinant tissue plasminogen activator or alone⁽⁸⁾ and non-vitreotomising vitreous surgery.⁽⁹⁾

Conclusion

With reference to our case, failure of Nd:YAG hyaloidotomy can be attributed to the relatively late presentation of the patient which lead to the surgical intervention for removal of pre macular hemorrhage.

References

1. Duane TD. Valsalva hemorrhagic retinopathy. *Trans American Ophthalmological Society* (1972)70,298–313.
2. Agarwal A. Gass' Atlas of Macular Disease. 5th ed. Elsevier; 2012. Chapter 8, 730-731.
3. Shukla D, Naresh KB, Kim R. Optical coherence tomography findings in Valsalva retinopathy. *American Journal of Ophthalmology* (2005)140,134–6.
4. Frankhauser F, Kwasniewska S. Neodymium: yttriumaluminium- garnet laser. In: L'Esperance FA, editor. *Ophthalmic lasers*, vol II. St Louis: CV Mosby,1989.
5. Kwok AK, Lai TY, Chan NR. Epiretinal membrane formation with internal limiting membrane wrinkling after Nd:YAG laser membranotomy in Valsalva retinopathy. *American Journal of Ophthalmology* (2003)136,763–766.
6. De Maeyer K, Van Ginderdeuren R, Postelmans L, Stalmans P, Van Calster J. Sub-inner limiting membrane haemorrhage: causes and treatment with vitrectomy. *British Journal of Ophthalmology* (2007) 91,869–872.
7. Garcia-Fernandez, Castro-Navarro J, Gonzalez-Castano C. Long-term evolution of Valsalva retinopathy: a case series. *Journal of Medical Case Reports* (2012)6,346.
8. Park SW, Seo MS: Subhyaloid hemorrhage treated with SF6 gas injection. *Ophthalmic Surgical Lasers and Imaging* (2004) 35,335–337.
9. Wu TT, Chuang CT, Sheu SJ, Chiou YH: Non-vitreotomizing vitreous surgery for pre-macular haemorrhage. *Acta Ophthalmologica* (2011) 89:194–197.

