

## A case report of Mounier–Kuhn syndrome

Ravikumar P.<sup>1,\*</sup>, Priyadarshini Bai G.<sup>2</sup>

<sup>1</sup>Associate Professor, Dept. of Pulmonary Medicine, Sri Siddhartha Medical College, Tumakuru, <sup>2</sup>Assistant Professor, Dept. of Pharmacology, Chamarajanagar Institute of Medical Sciences, Chamarajanagar

**\*Corresponding Author:**

Email: ravi\_kumar3020@yahoo.com

### Abstract

We are reporting a case of a 35-year-old man with chronic cough, increased sputum production, breathlessness with fever. Computed tomography of chest showed tracheal dilation (diameter, 31 mm) and emphysematous changes. Fiberoptic bronchoscopy revealed enlarged trachea and main bronchi. Pulmonary function testing showed combined ventilatory defect. Histopathological examination of biopsy specimens from the bronchi and the tracheal wall suggestive of Mounier-Kuhn syndrome. The present case is an example for under diagnosis, as he was treated twice with anti-tubercular treatment for radiological shadows. The diagnosis of Mounier–Kuhn syndrome should be considered in instances of recurrent pneumonia and mucous plugging with or without typical radiologic findings.

**Keywords:** Anti-tubercular treatment; Bronchoscopy; Pulmonary function tests; Pneumonia; Tracheobronchomegaly.

### Introduction

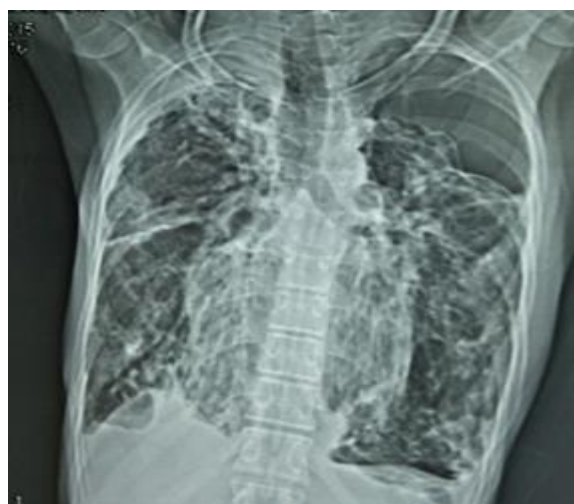
Mounier–Kuhn syndrome is characterized by dilatation of the trachea and major bronchi because of atrophy or absence of elastic fibers and smooth muscle cells. This syndrome is diagnosed by computed tomography and bronchoscopy. Clinical presentation may vary from asymptomatic to minimal symptoms with preserved lung function and rarely with severe respiratory failure. Treatment being supportive care and treating secondary infections like bronchiectasis. Surgery has a minimal role in the treatment.

The syndrome was first described by Mounier-Kuhn in 1932. Very few cases are reported in the medical literature. Mounier-Kuhn syndrome is also called as Tracheobronchomegaly. This is a rare syndrome characterized by dilation of the major airways like trachea and bronchi and presents with recurrent lower respiratory tract infections. The exact cause of the syndrome is not known; however, in biopsy studies, congenital atrophy has been observed in the smooth muscle and elastic tissue of the affected airways. Rarely bronchial and tracheal diverticula can also accompany this syndrome [1]. We are reporting a patient who was diagnosed with Mounier-Kuhn syndrome and we discuss the case in the context of the medical literature.

### Case report

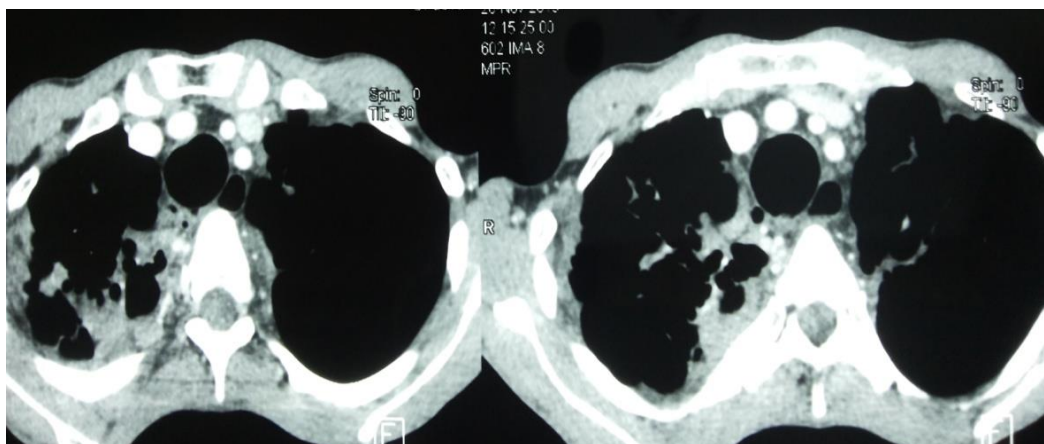
In Nov 2015, a 35-year-old Indian man presented at our hospital with chronic cough, increased sputum production, breathlessness and wheeze and fever. He had been diagnosed earlier with pulmonary Tuberculosis and treated two times with anti-tubercular treatment (ATT) (smear negative). He was a nonsmoker.

A chest radiograph showed an enlarged tracheal and its branches and emphysematous changes in both lungs (Fig. 1).

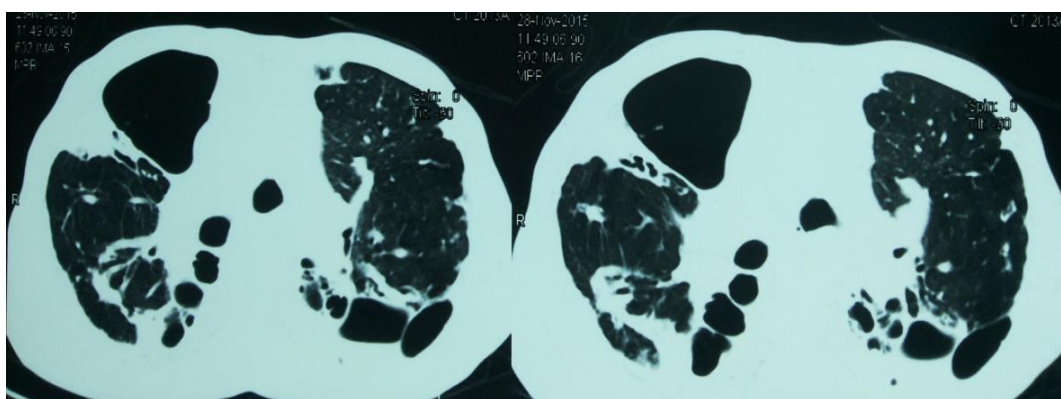


**Fig. 1: Chest X-ray showing tracheobronchomegaly, emphysematous and bronchiectatic changes**

The physical examination revealed emphysematous chest, and clubbing. Auscultation revealed extensive wheeze and basal course creptations in both chest fields. Routine investigations revealed elevated erythrocyte sedimentation rate (35 mm in 1<sup>st</sup> hour) and increased total leukocytes, count-14500/dl. Pulmonary function tests revealed a forced expiratory volume in 1 sec (FEV<sub>1</sub>) of 1.52 L (45%), a forced vital capacity (FVC) of 2.01 L (65%), and FEV<sub>1</sub>/FVC of 75%. Thoracic computed tomography (CT) showed dilated trachea, major bronchi and lobar and segmental bronchus, emphysematous changes in both lung apices with bullae and encysted pneumothorax. The CT images revealed a tracheal diameter of 31 mm. The internal diameters of the right and left main bronchi were dilated to 21 mm and 19 mm, respectively (Fig. 2A & B).



**Fig. 2A: Mediastinal window depicting tracheomegaly**



**Fig. 2B: Lung window showing tracheobronchomegaly, emphysematous bullae and encysted pneumothorax**

Fiberoptic bronchoscopy revealed tracheal dilation and enlargement of both bronchi up to 4<sup>th</sup> generation. Biopsy specimens taken from the trachea and bronchial wall revealed loss of elastic fibers around the respiratory tract and almost complete in some areas. On the basis of these findings, the patient was diagnosed with Mounier-Kuhn syndrome and was treated conservatively with Piperacillin and Tazobactam (4.5gm IV TID) and Levofloxacin 500mg IV OD with nebulization with bronchodilators and discharged from the hospital after five days with inhaled medications.

### Discussion

Mounier-Kuhn syndrome is a syndrome characterized by marked trachea-bronchial dilation. Pathologically this is due to atrophy of the muscular and elastic tissues in the trachea and main bronchial wall. This syndrome is more common in men and is typically diagnosed in the 3<sup>rd</sup> or 4<sup>th</sup> decades of life. The presentation varies from minimal symptoms, in which lung function is preserved to recurrent lower respiratory tract infections with severe respiratory failure and death. Bronchial involvement occurs at different levels, from the trachea down to the 4<sup>th</sup> bronchial branch [1]. Though exact cause is not fully known it is linked to familial susceptibility with autosomal recessive inheritance.

Mounier-Kuhn syndrome is classified into 3 subtypes [4]:-

- Type 1- Slight symmetric dilation in the trachea and main bronchi
- Type 2- Dilation and diverticula are distinct involves large airways
- Type 3- Severe disease, diverticular and saccular structures extend to the distal bronchi

The pathogenesis is due to ineffective cough consequent to pathologic dilation in the tracheobronchial tree and the impairment of mucociliary activity leading to recurrent lower respiratory tract infections [2]. The presentations of Mounier-Kuhn syndrome are nonspecific. Bronchiectasis and recurrent lower respiratory tract infections are clinically prominent, fibrosis can develop [3,4]. This syndrome is diagnosed by typical CT findings, where abnormally large air passages are detected. Diagnostic criteria is -diameters of the trachea >30 mm; right main bronchus >20 mm; and left main bronchus >18 mm [5]. Pulmonary function tests- characterized by the combined ventilator defect. Bronchoscopy- Can visualize dilation in the trachea and main bronchi during inspiration, and constriction and even collapse during expiration and coughing. Histopathological examination of tracheal or bronchial biopsy can be diagnostic [4].

Differential diagnosis includes Connective-tissue diseases like ataxia-telangiectasia, ankylosing spondylitis, Ehlers-Danlos syndrome, Marfan syndrome, Kenny-Caffey syndrome and is also associated with secondary tracheobronchial enlargement [6].

Asymptomatic patients may not require treatment. Supportive treatment includes cessation of smoking and minimizing exposure occupational irritants and pollutants. In symptomatic patients, treatment is limited to respiratory physiotherapy for clearing secretions and antibiotics during infectious exacerbations [7]. Tracheal stenting can be helpful in severe cases, but surgery is rarely performed because of the diffuse nature of the disease. Lung transplantation has minimal role with regard to the morbidity and mortality [8].

Most cases of tracheobronchomegaly are probably under diagnosed. The present case is such an example, as he was treated with ATT twice in the past for radiological shadows. The diagnosis of tracheobronchomegaly should be considered in instances of recurrent pneumonia and mucous plugging with or without typical radiologic findings.

**Conflicts of interest:** None declared

**Acknowledgements:** None

### References

1. Sarper A, Oz N, Demircan A, Isin E. Mounier-Kuhn syndrome: case report [in Turkish]. *Turk J Thorac Cardiovasc Surg.* 2002;10(2):116-17.
2. Damgaci L, Durmus S, Pasaoglu E. Mounier-Kuhn syndrome (tracheobronchomegaly). *Tanimsalve Girisimsel Radyoloji.* 2002;8(1):165-66.
3. Karalezli A, Yurdakul M, Misirli F. Mounier-Kuhn syndrome: a case report (tracheobronchomegaly) [in Turkish]. *Turkiye Klinikleri J Med Sci.* 1999;19(1):37-9.
4. Schwartz M, Rossoff L. Tracheobronchomegaly. *Chest.* 1994;106(5):1589-590.
5. Menon B, Aggarwal B, Iqbal A. Mounier-Kuhn syndrome: report of 8 cases of tracheobronchomegaly with associated complications. *South Med J.* 2008;101(1):83-7.
6. Ghanei M, Peyman M, Aslani J, Zamel N. Mounier-Kuhn syndrome: a rare cause of severe bronchial dilatation with normal pulmonary function test: a case report. *Respir Med.* 2007;101(8):1836-839.
7. Dunne MG, Reiner B. CT features of tracheobronchomegaly. *J Comput Assist Tomogr.* 1988;12(3):388-91.
8. Noori F, Abduljawad S, Suffin DM, Riar S, Pi J, Bennett-Venner A, et al. Mounier-Kuhn syndrome: a case report. *Lung.* 2010;188(4):353-54.