

A rare case of isolated pyomyositis of superior rectus in a young woman

Neha Singh^{1,*}, Jolly Rohatgi², Upreet Dhaliwal³, Shubhank Khare⁴, Manisha⁵

¹Senior Resident, King George Medical University, Lucknow, ^{2,3}Professor, ^{4,5}Senior Resident, Dept. of Ophthalmology, University College of Medical Sciences, New Delhi

***Corresponding Author:**

Email: nhsngh.89@gmail.com

Abstract

A young woman presented with acute onset diminution of vision, painful ocular movements in LE, and binocular diplopia since 10 days. Examination revealed Visual Acuity(VA) of 20/240, mild proptosis 3 mm, limitation on down gaze and RAPD with no signs of inflammation. Fundus revealed multiple bilateral disc drusen. ENT examination was normal. Suspecting orbital cysticercosis/leaking demoid/ orbital cellulitis MRI was ordered which revealed abscess of posterior aspect of Superior Rectus (SR) muscle. A diagnosis of pyomyositis of superior rectus causing retrobulbar neuritis was made. IV antibiotics were administered. VA, diplopia improved with mild residual restriction of down gaze at 4 weeks and grade 1 RAPD. Serial USG B scan revealed decreasing size of abscess. This case demonstrates a rare occurrence of superior rectus abscess causing retrobulbar neuritis which resolved with intravenous antibiotics alone. Pyomyositis should also be considered when there is painful limitation of extraocular movements.

Keyword: Pyomyositis, Proptosis, Superior Rectus, Neuritis

Introduction

Pyomyositis is a suppurative infection of striated muscles caused most commonly by staphylococcus aureus. It usually affects muscles of the limbs. Pyomyositis of extra-ocular muscles is extremely rare; only few cases have been reported.⁽¹⁻⁴⁾ The presentation, with proptosis and painful limitation of ocular movement, is similar to other orbital inflammations; however, because the deep seated abscess is not associated with external signs of inflammation, and because it is a condition that is rarely encountered in clinical practice, the diagnosis is often not considered by ophthalmologists resulting in a delay in initiating appropriate treatment. We report a case of superior rectus abscess in a 20 year old woman in whom leaking orbital dermoid or myocysticercosis was initially suspected.

Case Report

A 20-year old woman presented with pain, LE, worse on ocular movements, for one month. In the last ten days, she noticed diminished vision LE and diplopia on down gaze. Systemic examination was normal; there was no fever. Vision was 20/20 RE and 20/240 -LE. Hertles' exophthalmometry was 22mm RE and 25mm LE (bar reading 115mm). Resistance was felt on retropulsion, --LE. Ocular movements were full RE, but restricted in extreme up and down gaze, LE (Fig. 1). The anterior segment was normal except for a relative afferent pupillary defect, LE. There were multiple optic disc drusen in both eyes, but no signs of disc edema.

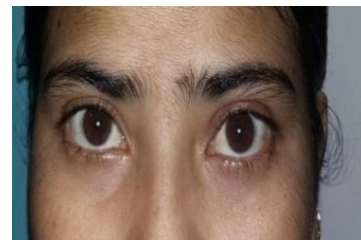

Fig. 1a

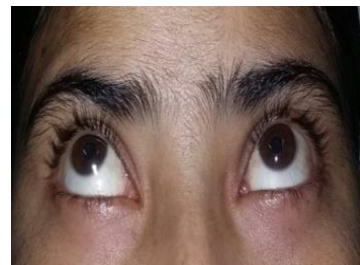

Fig. 1b

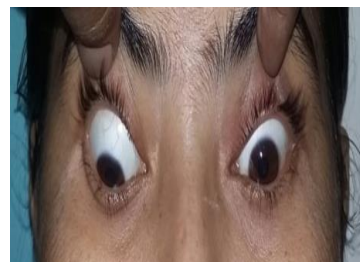

Fig. 1c

Fig. 1: a. Primary Gaze b. Up gaze c. Down gaze

Past history was significant for intestinal obstruction in 2013, which, as per records, was managed conservatively. In 2014, she underwent laparoscopy for severe spasmodic dysmenorrhoea;

found to have granulomatous endometritis, she received category-I antitubercular treatment for six months. There was a history suggestive of hordeolum in left eye in the recent past for which no treatment was sought; the lesion drained spontaneously and resolved.

Current haemoglobin was 11gm%, ESR 22mm/h, TLC 6,200/cubic mm, random blood sugar 90mg/dl, HIV nonreactive, and blood culture was sterile. Chest and orbital radiograms were normal. Based on the clinical picture we considered a differential diagnosis of myocysticercosis or a leaky orbital dermoid. Orbital sonography showed a well-defined, hypoechoic mass measuring 2.0x1.8 cm in the superior orbit. Magnetic resonance imaging (MRI) of the orbit, performed for precise localisation, revealed irregular thickening and edema in the left superior rectus with an irregular, thick-walled, predominantly fluid-intensity collection within the muscle (Fig. 2).

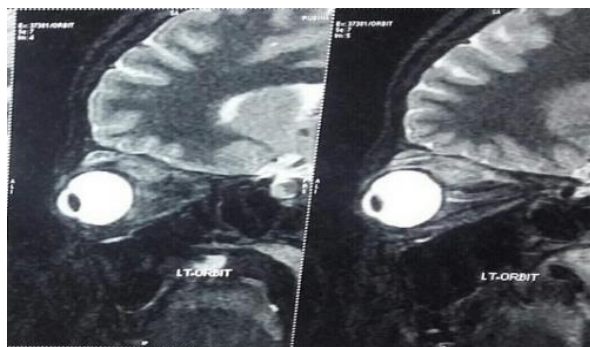


Fig. 2: Sagittal T1-weighted MRI scans showing abscess with surrounding edema in left superior rectus

A diagnosis of muscle abscess was made, and broad spectrum antibiotics (intravenous ceftriaxone 1gm and amikacin 500mg, both 12 hourly) were administered, with an option to surgically drain the abscess if there was no clinical improvement in the next 48-hours. Within 24-hours the patient reported marked reduction in pain; vision improved to 20/120, LE. At 2 weeks, proptosis was 2mm and vision 20/30. The left relative afferent pupillary defect persisted, although reaction was brisker than before. Repeat orbital ultrasound showed that the abscess was smaller (1.5x0.8 cm). At three weeks after initiation of treatment, follow up MRI was requested. As the patient could not afford it, contrast-enhanced computerized tomography (CECT) was performed; this showed only swelling of the superior rectus with complete resolution of the abscess (Fig. 3). Intravenous antibiotics were discontinued, and the patient discharged on oral amoxicillin and clavulante (625 mg thrice a day). Oral prednisolone, 30 mg per day was started to reduce chances of permanent fibrosis in the muscle. Steroids were tapered over the next month at which time vision was 20/30 LE, grade-1 relative afferent pupillary defect and minimal limitation on down gaze. Follow up after 6

months showed only a minimal limitation on down gaze with VA of 20/30.

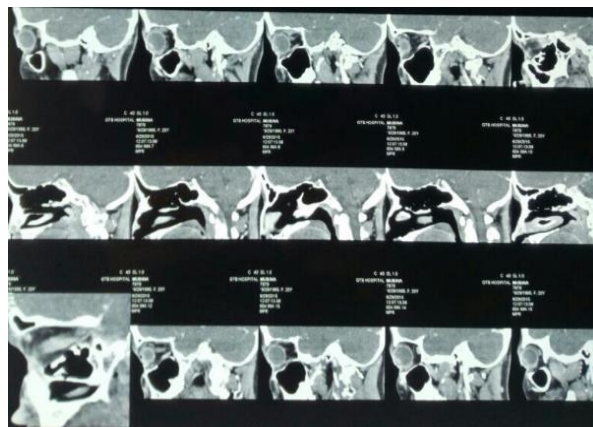


Fig. 3: CECT of patient after receiving antibiotics for 3 weeks showing a bulky superior rectus with no evidence of abscess

Discussion

Proptosis, pain, and restricted ocular movements, developing over a relatively short period of time, alerted us to the possibility of an inflammatory or infective etiology. Since there were no overt signs of orbital inflammation, we did not consider diffuse conditions like pseudotumor or orbital cellulitis.⁽⁵⁾ On learning of her recent treatment for extrapulmonary tuberculosis, we considered the possibility of orbital tuberculosis. Orbital tuberculosis may present as classical periosteitis, orbital soft tissue tuberculoma with no bony destruction, dacryoadenitis, orbital spread from paranasal sinuses, and orbital tuberculosis with bony involvement.⁽⁶⁾ The relatively short duration, acuteness of symptoms and the fact that she had recently completed a full course of anti-tubercular therapy shifted the diagnosis away from tuberculosis. While the diagnosis and management of orbital tuberculosis depends on biopsy confirmation, dramatic response to intravenous antibiotic supported a non-tubercular aetiology.

Ultrasonography was helpful in that it established the size of the lesion and excluded cysticercus and dermoid. MRI was unequivocal and clinched the diagnosis of muscle abscess.

The origin of pyomyositis is thought to be through seeding via haematogenous spread.^(2,3) Our patient reported the occurrence of a hordeolum a short period before the onset of the current problem. Perhaps seeding occurred from the hordeolum which festered untreated before draining and resolving.

Our patient had vision loss that improved as the abscess regressed; we speculate that she may have had retrobulbar neuritis which resolved with the treatment of lesion. The oral steroids, though they were initiated only after complete resolution of the abscess, may have helped. As the abscess was in the superior rectus

muscle very close to optic nerve, it must have caused inflammation of the adjacent nerve.

So far only few cases of pyomyositis of extra ocular muscles have been reported. *S. aureus* was the responsible organism in most of them. Owing to its rare occurrence, pyomyositis is not usually considered as a diagnosis in orbital inflammations. The usual culprits are diffuse orbital pseudotumor, orbital cellulitis, myocysticercosis, and leaking orbital dermoid.⁽⁵⁾ As with other inflammatory conditions involving the orbit, the signs and symptoms in orbital pyomyositis can be myriad. Most often, these cases present with an acute onset proptosis, pain on ocular movements, swelling, and redness.⁽³⁾ Presentation with a mass in the orbit and acute central retinal artery occlusion has also been described.⁽³⁾ Systemic symptoms are usually absent. Other, non-inflammatory differentials are structural lesions (dermoid cyst), vascular neoplastic lesions (capillary hemangioma, lymphangioma), lymphoproliferative diseases (lymphocytic granuloma), neurogenictumors and metastatic carcinoma. Non invasive investigations such as orbital ultrasonography, CT scan and MRI are required for precise anatomical tissue location and diagnosis. Of the previous reported cases, seven were treated with broad-spectrum IV antibiotics and with drainage of pus⁽¹⁻³⁾ and one with IV antibiotics alone.⁽⁴⁾ In our patient a decision against pus drainage was taken as the abscess was deep seated in the close vicinity of the optic nerve and was impacting its function. Furthermore, there were signs of early response to IV antibiotics alone.

Conclusion

Pyomyositis of extraocular muscle should be considered in any patient presenting with acute onset of painful proptosis and limitation of movement, where there are no local, external signs of inflammation. After diagnosis is established, orbital pyomyositis can be successfully treated with intravenous antibiotics; drainage of the abscess may not be required.

References

1. Kumar R, Singhal N, Sahu RN, Kalra SK, Sharma K, Mahapatra AK. Isolated superior rectus abscess following traumatic blunt injury to the eye. *J Pediatr Neurol.* 2008;6(3):287-292.
2. Bhalerao S, Singh K, Yadav B, Kumar R. Isolated abscess in superior rectus muscle in a child. *Indian J Ophthalmol.* 2015;63(3):284-286.
3. Acharya IG, Jethani J. Pyomyositis of extraocular muscle: case series and review of the literature. *Indian J Ophthalmol.* 2010;58(6):532-535.
4. Haufschild T, Weber P, Nuttli I, Hecker B, Flammer J, Kaiser HJ. Idiopathic isolated abscess in an extraocular muscle in a child. *Arch Ophthalmol.* 2004;122(8):1233-1234.
5. Yuen H., Yanoff M, Lam Choi V, Biswas J. Update in pathological diagnosis of orbital infections and inflammations. *Middle East Afr J Ophthalmol.* 2011;18(4):268-276
6. Babu K, Mukhopadhyay M, Bhat SS, Chinmayee JT. Orbital and adnexal tuberculosis: a case series from a South Indian population. *J Ophthalmic Inflamm Infect.* 2014;4:12.