

Transient inverse bells Phenomenon following frontalis sling surgery

Dhivya Ashok Kumar¹, Amar Agarwal^{2,*}

¹Consultant, ²Chairman, Dept. of Ophthalmology, Dr. Agarwal Eye Hospital

***Corresponding Author:**

Email: aeh19c@gmail.com

Abstract

Downward and inward movement of eyeballs on voluntary lid closure is known as Inverse Bells Phenomenon. This has been known to happen after maximal Levator resection surgeries. We present similar reversal of normal Bells phenomenon to Inverse Bells following Frontalis sling surgery in a young female patient with congenital ptosis. The inversion became normal after 2 weeks with conservative management. We believe that this report can add to the existing literature that inverse Bells shall occur not only in Levator surgery but also following frontalis sling and the surgeon should be well aware of such complication.

Introduction

Upward and outward movement of eyeball on attempted voluntary lid closure is termed as Bell's phenomenon.^(1,2,3) Downward and inward movement of eyeballs on lid closure is known as Inverse Bells. There have been few reports substantiating the chance of inverse Bells after supramaximal Levator resection following congenital ptosis.^(5,6,7) However, there are no previous reports or literature showing the risk of inverse Bells after frontalis sling surgery.

Case Report

A 26 years old female patient with bilateral droopy eyes since childhood, on examination had bilateral upper lid ptosis with poor levator function (3mm). The vertical palpebral height was 5mm and 5mm in OD and OS respectively. Marginal reflex distance (MRD) was -2mm and -2mm in OD and OS respectively. Her extraocular movements were normal and Bells was normal (upward and outward). There were no other ocular abnormalities in anterior or posterior segment observed. She underwent Bilateral Frontalis Sling in pentagon fashion using silicone sling under local infiltration anesthesia. There were no intraoperative complications noted.

On Day one postoperative period, her MRD was 4mm OD and 4mm OS. There was significant lid edema and prominent lagophthalmos was present. Sling was in position and skin wound sutures were intact. There was inverse Bells (downward and inward movement) noted (Fig. 1) on voluntary lid closure and other extra ocular movements were normal. Patient had excessive lacrimation and early epithelial defect on day 1. Frost suture was secured in place and copious lubricants (carboxy methyl cellulose 1%) in gel and drops formulations were given. On 2 weeks postoperative follow up, the Bells phenomenon has become normal (Fig. 2) and there was no lacrimation or epithelial changes. Lagophthalmos has reduced and the patient was asymptomatic with edema resolved (Fig. 3).

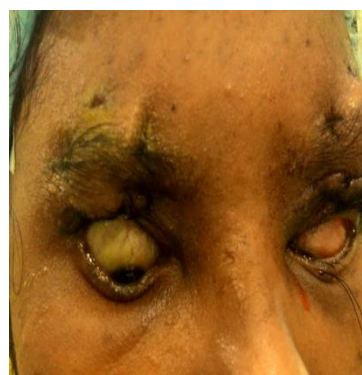

Fig. 1: Postoperative inverse Bells following frontalis sling surgery seen as eyes moving down and inwards on lid closure

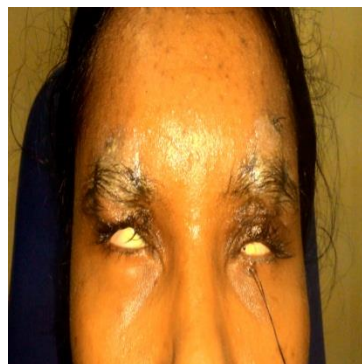

Fig. 2: Bells becoming normal on lid closure at 2 weeks postoperative period

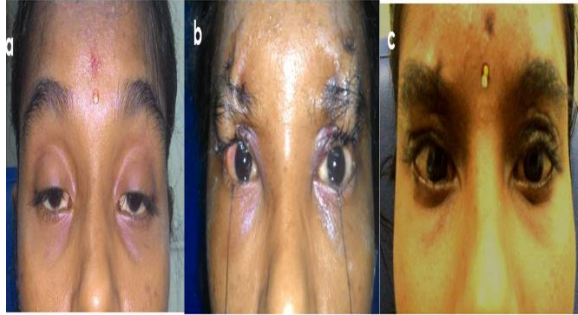


Fig. 3: Preoperative (a), 2 weeks (b) and 4 weeks (c) postoperative following sling surgery

Discussion

Levator resection is often identified as the common surgery before Inverse Bells.⁽⁵⁻⁷⁾ The proposed mechanism being the extensive tissue manipulation and dissection. However, such tissue manipulation does not happen in frontalis sling as it passes through one plane or axis only. Nevertheless there is excess tissue bundled up by the sling along its path which induces indirect trauma by causing edema and hemorrhage in muscular and subcutaneous plane. Though the silicone sling is less traumatic, the needle end of the sling can induce trauma and induce acute edema, hemorrhage and inflammation. Similar to other cases, the inverse bells resolved within 2 weeks post-surgery without any additional treatment. Certain pathologic conditions like 7th cranial nerve palsy, Tabes Dorsalis, conjunctival scarring, malignancy and ectropion of upper lid may induce inverse Bells.^(1,8) Gupta et al reported that in such situations the reflex arc involves the 4th cranial nerve nuclei along with 3rd and 7th nerve causing inverse phenomenon i.e. eye rotates down instead of up.⁽¹⁾ The clinical significance is increased when the

inverse movement happens in a post ptosis surgery as there is coexisting lagophthalmos.

Examination of Bells phenomenon is vital in all lid surgeries. It has to be stressed that preoperative eye movement documentation and post-operative ocular movements abnormalities identification is important in learning curve. We believe that this report can add to the existing literature that inverse Bells shall occur not only in Levator resection but also following frontalis sling and the surgeon should be well aware of such complication.

References

1. Gupta JS, Chatterjee A, Kumar K. Inverse bells phenomenon as a protective mechanism. *Am J Ophthalmol.* 1965 May;59:931-3.
2. Marin Amat, M.: Inverse Bell's sign. *Am. J. Ophth,* 29:248,1946.
3. Cohen SW, Banko W, Zerykier A. Testing of Bell's phenomenon by transocular transcutaneous transillumination. *Am J Ophthalmol.* 1977 Nov;84(5):735.
4. Yoon JS, Lew H, Lee SY. Bell's phenomenon protects the tear film and ocular surface after frontalis suspension surgery for congenital ptosis. *J Pediatr Ophthalmol Strabismus.* 2008 Nov-Dec;45(6):350-5.
5. Betharia SM, Sharma V. Inverse Bell's phenomenon observed following levator resection for blepharoptosis. *Graefes Arch Clin Exp Ophthalmol.* 2006 Jul;244(7):868-70. Epub 2005 Sep 21.
6. Na KS, Yang SW. Two cases of inverse Bell's phenomenon following levator resection: a contemplation of the mechanism. *Eur J Ophthalmol.* 2009 Mar-Apr;19(2):285-7.
7. Shitole S, Jakkal T, Khaire B. Inverse Bell's Phenomenon: Rare Ophthalmic Finding Following Ptosis Surgery. *J Clin Diagn Res.* 2015 Mar;9(3):ND01-2. doi: 10.7860/JCDR/2015/11340.5686.
8. Lisch, K.: Bell's phenomenon. *Am. J. Ophth,* 39:617, 1955.