

Pigmented Bowen's disease of bulbar conjunctiva: A case report

Manoj Vasudevan^{1,*}, Chidambharam Choccalingam², Rajesh Kanna³, Vijayshree Raghavan⁴

¹Associate Professor, Dept. of Ophthalmology, ²Assistant Professor, ³Associate Professor, ⁴Professor & HOD, Dept. of Pathology, Chettinad Medical College

***Corresponding Author:**

Email: manojvasudevanms@gmail.com

Abstract

Introduction: Ocular surface squamous neoplasia (OSSN) includes pre-cancerous and cancerous lesions of the cornea and conjunctiva. Bowen's disease (BD) is carcinoma in situ or intra-epidermal squamous cell carcinoma which is a part of intraepithelial ocular surface squamous neoplasia of conjunctiva. Pigmented Bowen's disease is a rare entity characterized by presence of increased pigmentation in the epidermis or papillary dermis, in addition to the typical findings of Bowen's Disease commonly affecting the skin and mucous membranes. We report here a case of pigmented Bowen's disease of the bulbar conjunctiva in a middle aged south Indian man. To our knowledge, this is the first reported case of pigmented Bowen's Disease of bulbar conjunctiva in the world.

Keywords: Pigmented Bowen's disease, Conjunctiva, Squamous Neoplasia, Intra-epithelial, Mitomycin, Auto graft.

Case Report

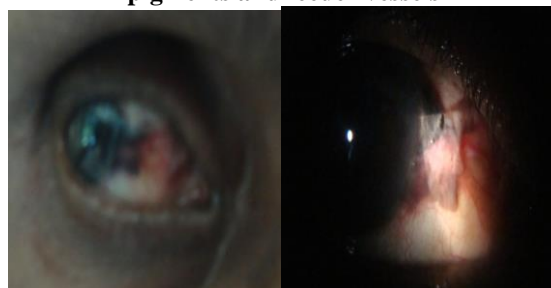A 48 years man presented with 3 month history of a painless, slowly enlarging dark brown plaque in right eye (RE) conjunctiva (Fig. 1). There is no history of any other ocular symptoms. There is no history of trauma or exposure to chemical injuries in the past. He is a chronic smoker for the past 20 years. His past medical history was insignificant. On examination by diffuse examination RE showed a growth of about 8mm by 6 mm on the nasal bulbar conjunctiva crossing on to the limbus and about 1mm into the clear cornea. The surface of this lesion was rough and showed vascularity with patchy areas of black to brownish pigmentations. No regional lymph nodes were palpable. The lesion was planned for an excision biopsy under topical anaesthesia and the surgical excision of the lesion with a clear margin of 1mm all around except at the corneal end was done and intra operative mitomycin application was done at a concentration of 0.02% for 90 seconds over the bare scleral bed after total excision and conjunctival autograft was put on the bare sclera with 4 anchoring sutures using absorbable 8.0 vicryl. Post operatively topical 1% prednisolone acetate was used 4 times a day for 2 weeks and 0.05% cyclosporine 2 times a day for 3 months was used.

The lesion was sent for histopathological examination (HPE) which revealed hyperkeratosis with disorderly arranged atypical squamous cells throughout the epidermis. 2-3 mitotic figures/10 high power fields were seen. Increased melanin pigmentation was seen throughout the epidermis. No evidence of invasion or infiltration into the sub-epithelium was seen. The histological features were consistent with pigmented Bowen's disease.

During a regular follow up about 6 months later, a small nodule was seen at the site of previous growth which was again excised and sent for HPE. Histopathology of the lesion showed squamous

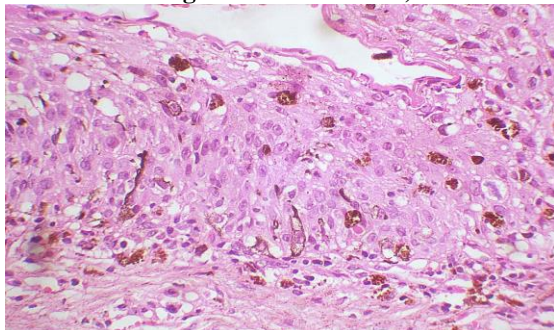
epithelium with mild hyperkeratosis. No atypical cells were seen. The patient was advised close follow up and started on 0.05% topical cyclosporine eye drops 2 times a day and was continued for 6 months and stopped. There were no further recurrences and the patient is on 2 years of follow up till now.

Pre-operative photographs of the pigmented growth of the right eye nasal bulbar conjunctiva
Photo 1: Clinical image showing: Elevated bulbar conjunctival lesion extending on to the nasal limbus from the bulbar conjunctiva with evidence of pigments and feeder vessels



Histopathological Examination

Photo 2: Histopathology showing stratified squamous epithelium, with loss of polarity, atypical squamous cells, melanin pigmentation throughout the epidermis (Haematoxylin and Eosin, magnification 40 times)



Discussion

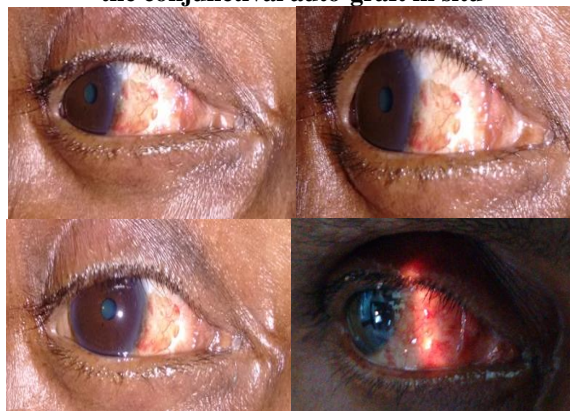
Pigmented Bowen's Disease is a rare entity which belongs to the spectrum of intra-epithelial OSSN, with less than 2% incidence in the general population. There have been reports of Bowen's Disease presenting at the limbus⁽¹⁾ diagnosed using histopathological examinations and using markers. The treatment of Bowen's Disease by excision followed by cryotherapy was reported in 1982 by Takahashi T.⁽²⁾ Recurrence of Bowen's Disease and malignant transformation were noted to occur more commonly where only excision was done.⁽²⁾ There has never been reported a case of pigmented Bowen's Disease of conjunctiva while a report of pigmented Bowen's Disease of the eyelid with prominent amyloid deposit⁽³⁾ was reported in 2014. Similarly a pigmented intraepithelial squamous neoplasia of the anal canal was reported.⁽⁴⁾

Bowen's Disease presents as slowly growing erythematous plaque or growth. Histologically, pigmented Bowen's Disease presents as full thickness atypical squamous cells, with no invasion into dermis along with melanin pigmentation in basal cells. In our patient, melanin pigmentation was present in the full thickness of the atypical squamous cells. The differential diagnosis includes pigmented basal cell carcinoma and melanoma. The absence of infiltration by basaloid cells and retraction artefacts are important clues to differentiate basal cell carcinoma from pigmented Bowen's Disease. Absence of nevus cell nests with large prominent nucleoli and presence of intra-epithelial bridges are clues to differentiate basal cell carcinoma from pigmented Bowen's Disease. Recurrence of intra-epithelial squamous cell carcinoma is high and depends on the involvement by surgical

margins. Our patient presented with a nodule in the same site after the first excision biopsy within 6 months, however the repeat excision biopsy revealed no atypical squamous cells.

Post-operative photographs 3 months after excision with conjunctival autograft and 0.02% Mitomycin C

Photo 3: Right eye post excision of the lesion with the conjunctival auto-graft in situ



Conclusion

This is the very first reported case of pigmented Bowen's Disease of the conjunctiva and is a very rare clinical entity occurring in the ocular adnexa like the skin of the eyelid more commonly encountered by the dermatologists affecting skin. Excision biopsy combined with application of 0.02% Mitomycin C followed by conjunctival auto-graft is an effective treatment option for these lesions and these have to be followed up for recurrences and a very rare possibility of malignant transformation must be always remembered.

References

1. Ben Rejeb A, Mabrouk L, Makni K, Chadli A, Hafsia M, Gabsi S. Ag-NORS and non-pigmented tumors of the sclerocorneal limbus. Apropos of 20 cases. *J Fr Ophtalmol.* 1994;17(2):99-102.
2. Takahashi T. Bowen's disease at the limbus. *Acta Ophthalmol (Copenh).* 1982 Feb;60(1):147-55.
3. Ito T, Wada M, Kuma Y, Kido-Nakahara M, Yamada Y, Okano S, Oda Y, Furue M. Pigmented Bowen's disease with prominent amyloid deposition on the eyelid. *Indian J Dermatol Venereol Leprol.* 2014 Nov-Dec;80(6):558-60.
4. Ishida M, Iwai M, Kagotani A. Pigmented anal squamous intraepithelial neoplasia: a case report and review of literature. *Int J Clin Exp Pathol.* 2014 May 15;7(6):3456-9.