

Morphometric and morphological study of foramen ovale in dry adult human skull bones

Poornima B^{1,*}, Sampada P K², Mallikarjun M³, Santosh B S⁴

^{1,2}Assistant professor, ³Professor & HOD, Dept. of Anatomy, Vijayanagar Institute of Medical Sciences, Ballari, Karnataka,

⁴Professor, Dept. of Public Health Dentistry, SAIDS, Calicut, Kerala

***Corresponding Author:**

Email: pnima73@gmail.com

Abstract

Background: One of the important foramen which connects the middle cranial fossa to the infratemporal fossa is the foramen ovale. Structures passing through this foramen are lesser petrosal nerve, mandibular nerve, accessory meningeal artery and an emissary vein which connects the pterygoid venous plexus in the infratemporal fossa to the cavernous sinus.

Materials and Methods: This study was done by using 100 dry adult human skull bones taken from the Anatomy Department, V.I.M.S., Ballari, Karnataka, India. Anteroposterior and transverse diameters of the foramen ovale were measured. Different shapes of the foramina and any bony growth around its margins were noted. Duplication of the foramen was observed.

Results: Out of 200 sides in 100 adult dry human skull, average transverse and anteroposterior diameters of foramen ovale was 3.50 ± 0.842 mm and 6.4 ± 1.471 mm on left side and on right side was 3.54 ± 0.569 mm and 6.5 ± 1.398 mm. Oval shaped foramina were 60%, almond shape were 25%, round shape were 13% and slit like foramina were 2%. 11% of foramina had spines, 5% had tubercles and 10% had a bony plate. Duplication of the foramen was seen in one skull on the right side.

Conclusion: Our present study may be of immense importance in cases of neurovascular compression due to abnormal bony growth, fine needle aspiration technique in perineural spread of tumor and in trigeminal neuralgia.

Keywords: Foramen Ovale, Middle Cranial Fossa, Mandibular Nerve, Trigeminal Neuralgia.

Introduction

There are several foramina piercing the greater wing of the human sphenoid bone and one amongst them is the foramen ovale. Foramen ovale is present medial to the foramen spinosum and foramen lacerum is located medial to the foramen ovale. It transmits the mandibular division of the trigeminal nerve, accessory meningeal branch of the maxillary artery, lesser petrosal nerve and an emissary vein which connects the pterygoid venous plexus in the infratemporal fossa to the cavernous sinus.^(1,2) Foramen ovale is situated at the transition zone between the extra cranial and the intracranial structures.⁽³⁾ Thus, it is one of the important foramina of the skull. Hence, it is used for diagnostic and surgical procedures.

Knowledge of the foramen ovale morphometry and morphology is important in procedures involving Trigeminal neuralgia and administration of anaesthesia via mandibular nerve.⁽⁴⁾ Through foramen ovale, percutaneous biopsy of cavernous sinus can be performed.⁽⁴⁻⁶⁾ Our present study was conducted to define anatomical variations in foramen ovale. Prior knowledge of variations in foramen ovale may be important for forensic, anthropological and surgical purpose and this study aims to highlight such.⁽⁴⁾

Materials and Methods

The study was carried out on 200 foramen ovale using 100 dry adult human skull bones of unknown sex, the bones were taken from the Anatomy Department, Vijayanagar Institute of Medical Sciences, Ballari, Karnataka, India. Skulls which were fractured at the

surroundings of foramen ovale were not included in the study.

- Maximum transverse diameter, anteroposterior diameters of the foramen were measured with the help of vernier calipers.
- Any variations in the shape of foramen were noted.
- Margins of foramen were carefully observed for any bony projections.
- Duplication of foramen ovale was observed.

Independent sample 't' test was used for statistical analysis.

Results

Out of 200 foramen ovale, minimum to maximum anteroposterior diameter on left side were 3.3mm-8.6mm and on right side were 4.1mm-8.8mm. Average anteroposterior diameter on left side was 6.4 ± 1.471 mm and on right side was 6.5 ± 1.398 mm. Minimum transverse diameter on left side was 2.4mm and on right side was 2.8mm. Maximum transverse diameter was 6.1mm and 5.4mm on left and right sides respectively.

Majority of the foramen were oval shaped and it was seen in 120 sides(left 58, right 62), almond shape was seen in 50 sides(26 left, 24 right), round shape was seen in 26 sides(14 left, 12 right), slit like foramen was seen in 4 sides(2 left, 2 right). Incidences of various shapes of the foramen ovale were oval 60%, almond 25%, round 13% and slit like 2%.

Out of 200 foramina, bony spine were observed in 22 followed by 10 tubercle and 20 bony plate. Incidences of spine, tubercle and bony plate were 11%, 5% and 10% respectively.

Duplication of foramen ovale was observed in one skull on the right side.

Table 1: Anteroposterior and transverse diameters of foramen ovale on both sides (Right and Left)

Values	Anteroposterior diameter(mm)		Transverse diameter(mm)	
	Right	Left	Right	Left
Maximum	8.8	8.6	5.4	6.1
Minimum	4.1	3.3	2.8	2.4
Mean	6.5	6.4	3.54	3.5
Standard Deviation	1.398	1.471	0.569	0.842
p-value	0.667		0.824	

Graph 1: Bar diagram showing the anteroposterior and transverse diameters of foramen ovale on both sides

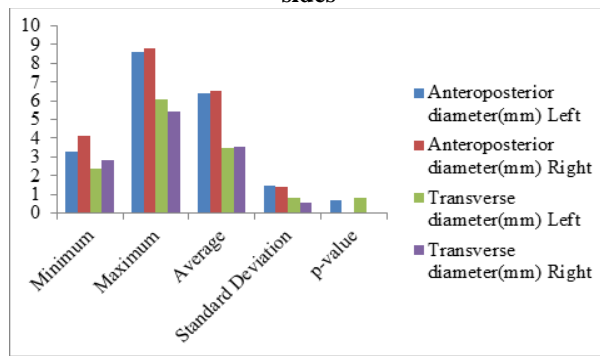


Table 2: Variations in the shape of foramen ovale

Foramen ovale shapes	Right	Left	Total
Oval	62	58	120
Almond	24	26	50
Round	12	14	26
Slit	2	2	4

Graph 2: Bar diagram showing the different shapes of the foramen ovale

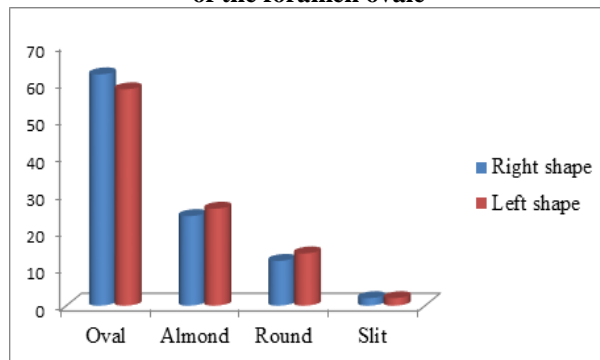


Fig. 1: Showing 100 dry adult human skull bones

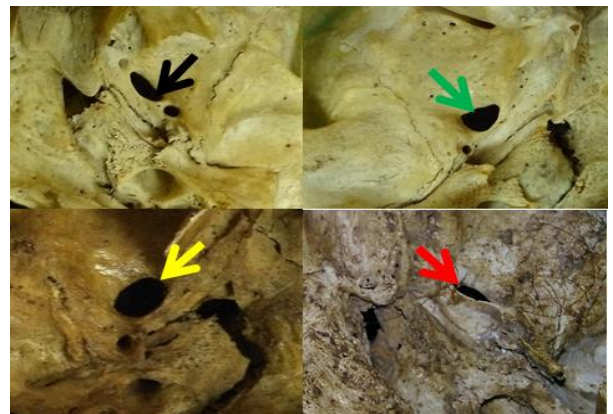


Fig. 2: Variations in the shape of foramen ovale: oval shape (black arrow), almond shape (green arrow), round shape (yellow arrow), slit like (red arrow)

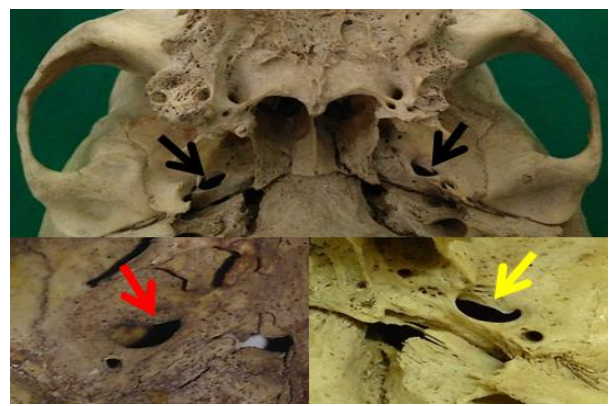


Fig. 3: Margins of the foramen ovale exhibiting variable projections: bilateral presence of spine (black arrow), tubercle (red arrow), bony plate (yellow arrow)



Fig. 4: Showing duplication of foramen ovale (yellow arrow)

Discussion

Foramen ovale is considered to be one of the vital foramina situated between intracranial and extra cranial structures across transition zone. Its application in the field of invasive surgery and in diagnostic procedure is unparalleled. Thus, the knowledge of morphometric and morphology of foramen ovale is essential for surgeons.

In this study, the average value of anteroposterior diameter of left foramen ovale was 6.4 ± 1.471 mm and on right side was 6.5 ± 1.398 mm. Left foramen ovale mean transverse diameter was 3.5 ± 0.842 mm and on right side was 3.54 ± 0.569 mm. Though the anteroposterior diameters of right foramen ovale were longer than on left side, but this variation was not statistically significant ($p > 0.05$). The transverse diameters of right and left foramen ovale were found to be not statistically significant ($p > 0.05$).

The study of Gupta N was similar with the results of our study which was conducted on 35 dry adult skulls. Their study revealed that the mean length of foramen ovale was 7.228 ± 1.39 mm on right side and 6.48 ± 1.131 mm on left side. On left side, mean width was 3.50 ± 0.75 mm and on right side was 3.57 ± 0.70 mm. The difference between the mean values of the length and width of the right and left foramen ovale⁽⁷⁾ was not that significant.

Osunwoke E.A. study revealed that the mean of the lengths of the right and left foramen ovale was 7.01 mm and 6.89 mm with the range; 5.0-9.5 mm and 5.0-9.0 mm, on right and left sides respectively. The mean value for the widths of the right and left foramen ovale was 3.37 mm and 3.33 mm with range of 2.0-5 mm on both sides. Significant difference between the mean of the length and width of the right and left foramen ovale⁽⁸⁾ was not observed.

Our present study showed greater number of foramen to be oval shaped about 60% remaining almond, round and slit like were 25%, 13%, 2% respectively. Our results are in agreement with study of Gupta N and Rai AL, which followed in the same sequence of oval shaped 54.2%, almond shaped 35.7%, round shaped 8.5% and slit like 1.4%.⁽⁷⁾

In a study conducted by Ray B et al, they noted that 61.4% of the foramen were oval shaped, 34.3% were almond shaped, 2.9% were round and slit like were 2.9%.⁽³⁾ In a developmental study conducted by yanagi, the results were similar.⁽⁹⁾

Out of 200 foramina, 22 showed the presence of a bony spine followed by tubercle with 10 foramina and bony plate with 20 foramina. Incidences of spine, tubercle and bony plate were 11%, 5% and 10% respectively. Our results are in agreement with study of John DA conducted on 30 adult skulls, bony spine was found on 8 foramina out of 60, 4 foramina showed the tubercle and 7 foramina showed the bony plate. Incidences of spine, bony plate and tubercle bony plate were 13% followed by 11.6% and 6% respectively.⁽¹⁰⁾

In our study, duplication of foramen ovale was observed in one skull on the right side. In a study conducted by Ray B et al, they observed the presence of a bony spur that divided the foramen ovale in two separate compartments.⁽³⁾ Reymond et al, in their study found that in 4.5% of the cases the foramen was divided into two or three different compartments.⁽²⁾

The key to understanding both the completed normal anatomic structure and the abnormal variations lies with the deeper understanding of development and fetal growth. Majority of the central part of the base of the skull bone develops from endochondral ossification through an intermediary chondrocranium. The sphenoid bone is made up of the body which is formed by the postphenoid and presphenoid centres, medial crus of the orbitosphenoid also contributes to its formation. The alisphenoids and orbitosphenoids gives rise to the greater and lesser wings of the sphenoid bone. Ossification of skull takes place from posterior to anterior. The postsphenoid part ossifies at about 14 weeks and presphenoid part at about 17 weeks. Alisphenoids ossify at about 15 weeks and orbitosphenoid at about 16 weeks. A fetal specimen with a gestational age of 22 weeks 3 days in a CT scan study showed ossification of alisphenoid and foramen ovale is seen as a large defect. Around the large trunk of mandibular nerve, ossification takes place later. The variations in margins and shape of the foramen indicate bony outgrowth during the developmental process.⁽¹¹⁾

In various diagnostic and surgical procedures, foramen ovale is used. It is used for electroencephalographic analysis of the seizure for patients undergoing selective amygdalohippocampectomy,⁽¹²⁾ percutaneous biopsy of cavernous sinus tumours⁽⁶⁾ and micro vascular decompression by percutaneous trigeminal rhizotomy for trigeminal neuralgia.^(12,13) Through the foramen ovale the CT-guided transfacial fine needle aspiration technique is performed. It is done to diagnose meningioma, squamous cell carcinoma etc., and biopsy of the lesions which require open surgical biopsy or craniotomy.^(14,9)

Conclusion

Morphometric and morphological anatomy of foramen ovale is very useful for medical practitioners while handling the cases of trigeminal neuralgia, tumour detection, bony outgrowths that leads to necrosis, ischaemia.

References

1. Standing S: The Anatomical Basis of Clinical Practice, Gray's Anatomy. 39th Edition. Elsevier Limited, 2006, pp. 460-462.
2. Reymond J, Charuta A, Wysocki J. The morphology and morphometry of the foramina of the greater wing of the human sphenoid bone. *Folia Morphologica*: 2005;64(3):188-93.
3. Ray B, Gupta N, Ghose S. Anatomic variations of foramen ovale. *Kathmandu University Med J*:2005;(3):64-68.
4. Abd Latiff A et al. The accessory foramen ovale of the skull: an osteological study. *Clin Ter*: 2009;160(4):291-3.
5. Yi W, Ohman K, Brannstrom T, Bergenheim AT. Percutaneous biopsy of cavernous sinus tumour via the foramen ovale. *Acta Neurochir (Wien)*: 2009;151(4):401-7.
6. Sindou M, Chavez JM, Saint Pierre G, et al. Percutaneous biopsy of cavernous sinus tumours through the foramen ovale. *Neurosurgery*: 1997;40:106-11.
7. Gupta N, Rai AL. Foramen ovale-morphometry and its surgical importance. *Innovative Journal of Medical and Health Science*: 2013;3(1):4-6.
8. Osunwoke EA, Mbadugha CC, Orish CN, Oghenemavwe EL and Ukah CJ. A morphometric study of foramen ovale and foramen spinosum of the human sphenoid bone in the southern Nigerian population. *Journal of Applied Biosciences*: 2009;26:1631-35.
9. Yanagi S. Developmental studies on the foramen rotundum, foramen ovale and foramen spinosum of the human sphenoid bone. *The Hokkaido Journal of Medical Science*: 1987;62(3):485-496.
10. John DA, Thenmozhi. Anatomical Variations of Foramen ovale. *J. Pharm. Sci. & Res*: 2015;7(6):327-329.
11. Nemzek WR, Brodie HA, Hecht ST, Chong BW, Babcock CJ, Seibert JA. MR, CT and plain film imaging of the developing skull base in fetal specimens. *American Journal of Neuroradiology*: 2000;21:1699-706.
12. Wieser HG, Siegel AM. Analysis of foramen ovale electrodergorded seizures and correlation with outcome following amygdalohippocampectomy. *Epilepsia*: 1991;32:838-850.
13. Gusmao S, Oliveria M, Tazinaffo U, Honey CR. Percutaneous trigeminal nerve radiofrequency rhizotomy guided by computerized tomography fluoroscopy: Technical note. *J Neurosurg*: 2003;99:785-786.
14. Barakos JA, Dillon WP. Lesions of the foramen ovale: CT-guided fine-needle aspiration. *Radiology*: 1992;182:573-575.