

A comparative study between 0.375% ropivacaine with 50mcg of dexmedetomidine and 0.375% ropivacaine with 8mg of dexamethasone for ultrasound guided supraclavicular brachial plexus block

Krishna Chaithanya^{1,*}, Asritha², Narasimha Reddy³, Sangamithra⁴

¹Associate Professor, ²PG Student, ³Professor, Dept. of Anaesthesia, ⁴PG Student, Dept. of Neurology,

***Corresponding Author:**

Email: chaithu8@gmail.com

Abstract

Introduction: Ultrasound has been increasingly used for nerve blocks as it shows precise location of nerve plexus, its surrounding vessels, reduces the injury to nerves and also avoids accidental intravascular injection as we can see the needle location and drug distribution. Various additives were used over the years. We used Dexmedetomidine and Dexamethasone as adjuvants to Ropivacaine for orthopaedic upper limb surgeries.

Objectives: To assess and compare the effects of Dexmedetomidine and Dexamethasone on onset and duration of sensory and motor block when added to Ropivacaine for supraclavicular brachial plexus block.

Materials and Methods: This randomized double blind study was conducted in 60 ASA grade I and II patients posted for elective hand surgeries under ultrasound guided supraclavicular brachial plexus block after obtaining informed consent. Patients were divided into two equal groups of 30 each. Group DX patients received 0.375% Ropivacaine(30ml) + Dexmedetomidine 50 mcg (0.5 ml) + normal saline(1.5ml) and Group DM patients received 0.375% Ropivacaine(30ml) + Dexamethasone 8 mg(2 ml). Sensory and motor block onset and durations were recorded.

Results: We observed early onset of sensory and motor block in group DX in comparison with DM ($p < 0.005$). Duration of Sensory and motor block was prolonged in Group DX than Group DM ($p < 0.0001$). Intra-operative hemodynamics were similar in two groups ($P > 0.05$).

Conclusion: We conclude that Dexmedetomidine added to Ropivacaine in ultrasound guided supraclavicular brachial plexus block is effective in reducing the onset time and prolongs the duration of sensory & motor blockade compared to Dexamethasone.

Introduction

Successful peripheral neural blocks widens the scope of anesthesiologist in providing anesthetic care.⁽¹⁾ The ultrasonographic visualization of the nerves to be blocked is a relatively new technique that holds promise for the future.⁽²⁾ This allows direct visualization of peripheral nerves, the block needle, and local anesthetic distribution. Past few years have observed a great increase in the use of ultrasound for regional nerve blocks.⁽³⁾

The search for best adjuvant to local anaesthetics for nerve blocks for rapid onset and prolonged duration of analgesia with less side effects has been never ending. Various adjuvants like opioids, neostigmine, midazolam, hyaluronidase, α_2 adrenergic receptor agonists, dexamethasone⁽⁴⁻⁷⁾ etc. have been used to modify the onset of action, enhance quality, prolong duration & post-operative analgesia.

We have chosen Dexmedetomidine and Dexamethasone as adjuvants to Ropivacaine for ultrasound guided supraclavicular brachial plexus block.

Dexmedetomidine, an imidazole compound is the pharmacologically active s-enantiomer of medetomidine. The specificity of Dexmedetomidine for the α_2 receptor is 8 times that of clonidine, with an α_2 / α_1 binding affinity ratio of 1620:1 and hence, considered as the full agonist at α_2 receptors.^(8,9)

Steroids have very good anti-inflammatory as well as analgesic properties. When the steroids are injected

around the nerves, they influence the block to a great extent. Various studies conducted in animals and humans showed that addition of dexamethasone to local anaesthetic drugs prolonged the block duration considerably.^(10,11)

Ropivacaine (0.75%), as a (S)-stereoisomer is less lipophilic than bupivacaine. It is being increasingly used for regional nerve blocks as the cardiovascular and central nervous system threshold is higher for Ropivacaine compared to bupivacaine.⁽¹²⁾

Materials and Methods

The study was conducted in 60 American Society of Anesthesiologists (ASA) grade I and II patients aged 18- 60 years of either sex posted for elbow, forearm and hand surgeries under ultrasound guided supraclavicular brachial plexus block after institutional ethics committee permission and written informed consent.

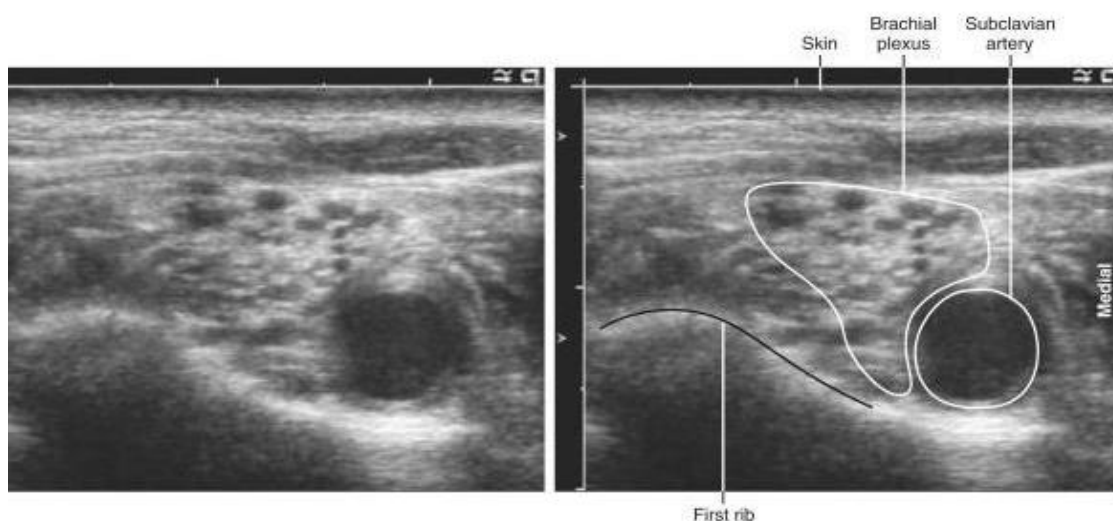
Group DX: Patients received 0.375% Ropivacaine(30ml) + Dexmedetomidine 50 mcg (0.5 ml) + normal saline(1.5ml).

Group DM: Patients received 0.375% Ropivacaine(30ml) + Dexamethasone 8 mg(2 ml).

Exclusion criteria: Patient refusal, known hypersensitivity to local anaesthetics, parturients, breast feeding mothers, diabetics, hepatic, renal or cardiopulmonary abnormalities, alcoholism, local skin site infections, coagulation abnormalities, significant neurological, psychiatric, or neuromuscular disorders.

Preoperative assessment: After thorough pre anesthetic evaluation and explaining the procedure on the day before surgery, patients of both groups were kept nil by mouth according to fasting guidelines. All patients were investigated for Haemoglobin, leukocyte count, platelet count, blood sugar, urea, creatinine and liver function tests. A 12 lead electrocardiography (ECG) and chest X-ray were also taken. In the operation theatre pulse oximeter, ECG, non-invasive blood pressure monitor were attached and baseline parameter were recorded. After securing wide bore intravenous canula (i.v), ringer's lactate infusion started and oxygen was given at 4L/min via poly mask. All patients were premedicated with injection midazolam 0.03 mg/kg before procedure.

Landmarks: Subclavian artery half an inch above the midpoint of clavicle. Under strict aseptic precautions and after local infiltration of 2ml of 1% lignocaine, the procedure was carried out using sonosite ultrasound with 13-6 MHz probe via in-plane approach with 22g 100mm needle. With the patient in supine position and the head turned 45° to the opposite side, the probe was placed in the supraclavicular fossa in coronal oblique plane to visualize the brachial plexus and subclavian artery. The brachial plexus is seen as cluster of hypoechoic nodules with hyperechoic margins lateral to the hypoechoic pulsating subclavian artery on top of the hyperechoic first rib (Fig. 1). Block was performed after real time visualization of the brachial plexus, artery & first rib.



Once brachial plexus is identified, **Group DX** Patients received 0.375% Ropivacaine(30ml) + Dexmedetomidine 50mcg (0.5 ml) + normal saline(1.5ml) and **Group DM** Patients received 0.375% Ropivacaine(30ml) + Dexamethasone 8 mg(2 ml) over 2-3 minutes using in plane approach. The patients were observed throughout the surgery for any adverse effect of the drugs. Onset of sensory and motor blockade was assessed every 3 minutes till the loss of sensory and motor sensations and from then on every 30 minutes till the regain of sensations and motor power. Vital parameters like heart rate, mean arterial blood pressure and oxygen saturation were also recorded during this period. The duration of sensory block was measured as the time from the onset of sensory block till the first post-operative pain. Motor block duration was defined as the time interval between the onset of motor block and complete motor function recovery. Spirit swab testing was used to assess the sensory onset. Motor block was assessed using the Bromage score.

0	normal motor function with full extension and flexion of elbow, wrist and fingers
1	decreased motor strength with ability to move fingers only
2	complete motor block with inability to move elbow, wrist and fingers.

Sedation was evaluated using the Ramsay sedation score (RSS)⁽¹³⁾

- 1 Patient is anxious and agitated or restless, or both
- 2 Patient is co-operative, oriented, and tranquil
- 3 Patient responds to commands only
- 4 Patient exhibits brisk response to light glabellar tap or loud auditory stimulus
- 5 Patient exhibits a sluggish response to light glabellar tap or loud auditory stimulus
- 6 Patient exhibits no response.

Heart rate, blood pressure & oxygen saturation were recorded every 5min intra-operatively & then at an interval of every 30mins postoperatively.

Statistical Analysis: All recorded data were entered using MS Excel software and analysed using SPSS 20 version software for determining the statistical significance. Results were presented as mean±standard deviation. Proportions were compared using Chi-square test. Statistical difference between both the study groups was determined by student ‘t’ test. p <0.05 was taken as statistically significant, p value of <0.01 has high statistical significance and p value of <0.001 was considered as extremely statistically significant.

Demographic Data: Age, sex, height & weight were similar in both the groups. The difference was not statistically significant (p >0.05).(Table 1)

Table 1: Demographic Variables among the groups

	Group DX	Group DM	p value
Age in years (mean±SD)	34.18±12.13	34.87±10.12	0.964
Height in cms (mean±SD)	168.88±66	164.32±2.10	0.53
Weight in kgs (mean±SD)	60.45±3.26	63.32±7.22	0.43
Gender (M/F)	24/26	30/20	0.34

Table 2: Sensory and motor block recordings of both groups

	Group DX	Group DM	p value
Onset of sensory block in minutes	8.34±1.4	12.34±3.45	0.0124
Onset of motor block in minutes	10.12±1.6	15.34±4.51	0.052
Duration of sensory block in minutes	899.5±61.9	734±23.4	0.0001
Duration of motor block in minutes	845.12±56.2	692.65±23.08	0.0001

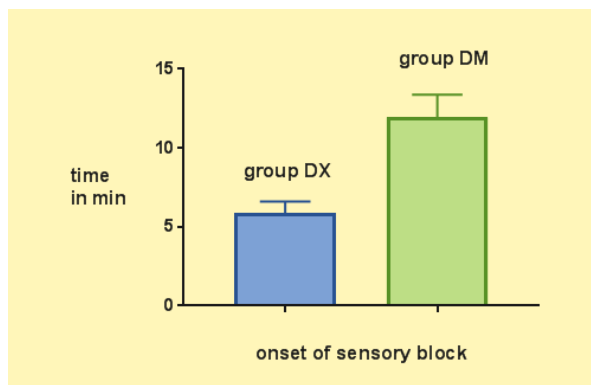


Fig. 1: Onset of Sensory block

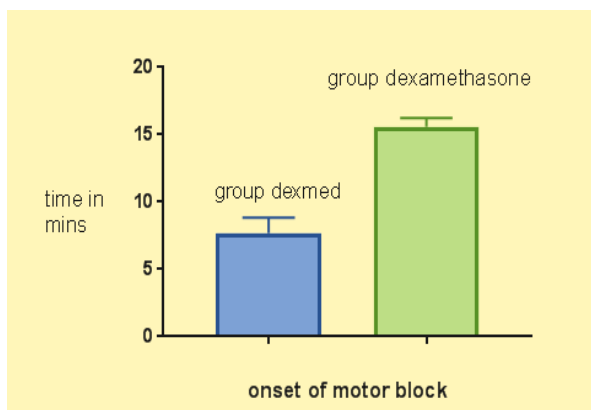


Fig. 2: Onset of motor block

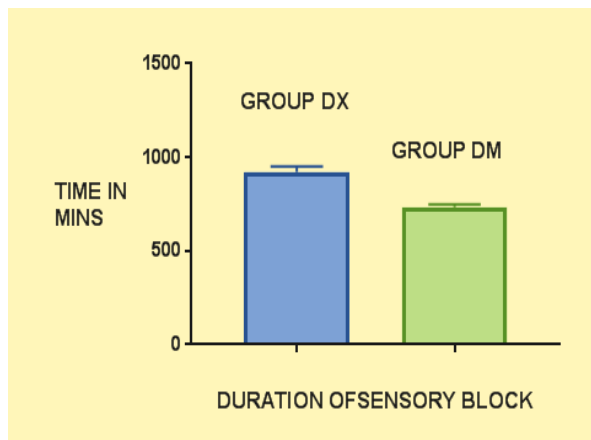


Fig. 3: Duration of Sensory block

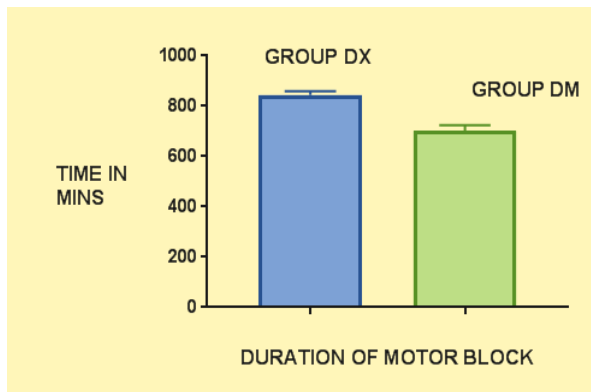


Fig. 4: Duration of motor block

Onset of sensory and motor block was earlier in group DX as compared to group DM (table 2; $p < 0.05$). Sensory and motor block duration was prolonged in DX group than D group (Table 2; $p < 0.001$). Duration of analgesia was significantly prolonged in DM group than DX group (Table 3) ($p < 0.001$).

Table 3: Comparison of heart rates in both groups

Duration	Group DX	Group DM	p value
Baseline	82	84	0.743
15 mins	80	82	0.568
30 mins	76	79	0.629
60 mins	68	74	0.232
120 mins	64	77	0.051
180 mins	66	74	0.065

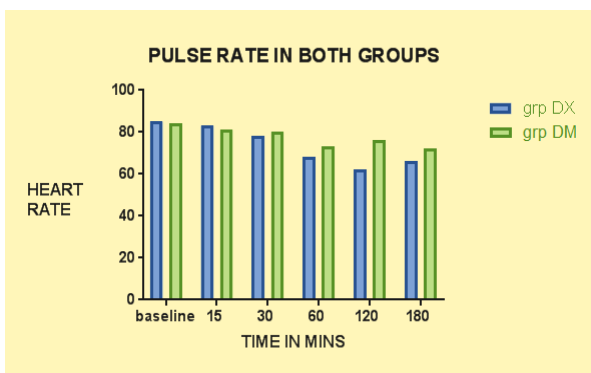


Fig. 5

Table.3 Variation in heart rates between the two groups was not statistically significant. But the heart rates at 60, 120 and 180 minutes were slightly lower in DM group compared to Group DX but it was never below 60 per minute.

Table 4: Comparison of mean arterial blood pressures in both groups

Mean arterial pressure	Group dexmed (DX)	Group dexamethasone	P value
Baseline	87	85	0.766
15 mins	84	82	0.654
30 mins	81	78	0.112
60 mins	76	75	0.234
120 mins	74	72	0.087
180 mins	72	70	0.065

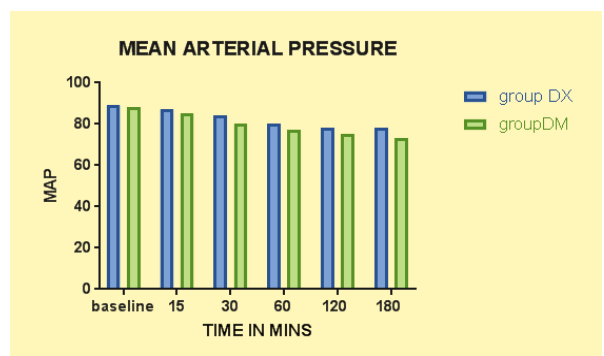


Fig. 6

Table.4 Difference in mean arterial pressure between both the groups was not statistically significant. Ramsay sedation score I was seen in all the patients of Group DX whereas score was 0 in Group DM.

Side effects like nausea, vomiting, bradycardia, hypotension and hypoxia were not noticed in both the groups.

Discussion

The brachial plexus is very compactly located at the supraclavicular region. So deposition of anaesthetic solution in this region provides dense block of upper limb. Hence this is the most preferred site of brachial plexus block.⁽¹⁴⁾ By using Ultrasound we could achieve high success rate avoiding the discomfort, injury to nerves and vessels associated with blind technique. Most considerable advantage with ultrasound is reduced total volumes of anaesthetic solutions injected in conventional techniques.

The quest for additives to long acting local anaesthetic like Ropivacaine which hastens the onset of block and prolongs the pain relief into the postoperative period is never ending. Both Dexmedetomidine, an alpha 2 agonist and Dexamethasone, a steroid when added to Ropivacaine for brachial plexus block speeds up the onset, quality and span of analgesia.⁽¹⁵⁾

In our study we compared Dexmedetomidine and Dexamethasone added to ropivacaine for

supraclavicular brachial plexus block. Faster onset and prolonging characteristics of Dexmedetomidine in synergy with local anaesthetics has been proved by many studies.^(16,17)

Dexamethasone, a synthetic glucocorticoid, has potent anti-inflammatory activity and no mineralocorticoid activity. Also it has no serious side effects. The mechanism of dexamethasone-induced prolongation of peripheral nerve blockade is not well understood. Dexamethasone alone does not have analgesic effects but when added to local anaesthetics prolong the duration of analgesia.⁽¹⁸⁾

N K Verma and A Ranjan⁽¹⁹⁾ in their study concluded that Dexmedetomidine and Dexamethasone as adjuvants to Ropivacaine (0.5%) for Supraclavicular brachial plexus block extend the duration of block considerably but dexmedetomidine provides more rapid onset of block when compared to dexamethasone.

Results of our study showed significant rapid onset of sensory and motor block in group DX compared to DM group ($p < 0.05$). Duration of Analgesia was highly significant in Group DX (899.5 ± 61.9) compared to Group DM (734 ± 23.4) ($p < 0.0001$). Duration of motor blockade was also highly significant in Group Dx (845.12 ± 56.2) compared to group DM (692.65 ± 23.08) ($p < 0.0001$). Though Dexmedetomidine has hastened the onset of sensory and motor block and also prolonged the block duration, Dexamethasone can also be effective alternative to Dexmedetomidine for regional nerve blocks owing to the cost effectiveness and availability.

Conclusion

Our study has proved that Dexmedetomidine provided rapid onset of sensory and motor blockade and significantly extended the sensory and motor block duration, when compared to Dexamethasone.

Conflicts of Interest: None.

Source of support: Nil.

References

- Denise J. Wedel and Terese T. Horlocker, Nerve blocks, Miller's Anesthesia, Ronald. D. Miller 7th edition 2010; Churchill living stone Elsevier; 1639-1674.
- H.H. Meherkans, Tutorials in peripheral regional anesthesia, 3rd edition 2005;6.
- Andrew T. Gray, Ultrasound Guidance for Regional Anesthesia, Miller's Anesthesia, Ronald. D. Miller 7th edition 2010; Churchill living stone Elsevier; 1675-1686.
- Bazin JE, Massoni C, Bruelle P, Fenies V, Groslier D, Schoeffler P. The addition of local anesthetics in brachial plexus block: The comparative effects of morphine, buprenorphine & sufentanil. *Anaesthesia* 1997;52:858-62.
- Bone HG, van Aken H, Brooke M, Burkle H. Enhancement of axillary brachial plexus block anaesthesia by co-administration of neostigmine. *Reg Anesth Pain Med* 1992;24:405-10.
- Keeler JF, Simpson KH, Ellis FR, Kay SP. Effect of addition of hyaluronidase to bupivacaine during axillary brachial plexus block. *Br J Anaesth* 1992;68:68-71.
- Sarita S Swami, Varshali M Keniya, Sushma DLadi, Ruchika Rao: Comparison of dexmedetomidine and clonidine (α_2 agonist drugs) as an adjuvant to local anaesthesia in supraclavicular brachial plexus block: A randomised double-blind prospective study. *Indian Journal of Anaesthesia*: 2012 May-Jun; 56(3):243-249.
- Reves JG, Glass PSA, Lubarsky DA, McEvoy MD, Martinez-Ruiz R. *intravenous anesthetics*. Miller's anesthesia. 7th edition. Philadelphia: Elsevier Churchhill Livingstone; 2010. p.751-57.
- Kaur M, Singh PM. Current role of Dexmedetomidine in clinical anesthesia & intensive care. *Anaesthesia: Essays and Researches*; 5(2); Jul-Dec 2011.
- Yoshitomi T, Kohjitani A, Maeda S, Higuchi H, et al. Dexmedetomidine enhances the local anaesthetic action of lidocaine via an alpha-2A adrenoceptor. *Anesth Analg* 2008;107:96-101.
- Golwala MP, Swadia VN, Dhimar AA, Sridhar NV. Pain relief by dexamethasone as an adjuvant to local anaesthetic in supraclavicular brachial plexus block. *J Anesth Clin Pharmacol* 2009;25(3):285-88.
- Simpson D, Curran MP, Oldfield V, Keating GM, Ropivacaine A review of its use in regional anaesthesia and acute pain management. *Drugs* 2005;65(18):2675-717.
- Ramsay MA, Savage TM, Simpson BR, Godwin R. Controlled sedation with alphaxolon -alphanolone. *Br Med J*. 1974;2:656-9.
- Esmooglu A, Yegenoglu F, Akin A, Turk CY. Dexmedetomidine added to Levobupivacaine prolongs axillary brachial plexus block. *Anaesth Analg*. 2010;111:1548-51.
- Gertler R, Brown HC, Mitchell DH, Silvius EN. Dexmedetomidine: a novel sedative-analgesic agent. *BUMC proceedings* 2001;14:13-21.
- Rachana Gandhi, Alka Shah, Ila Patel: Use of Dexmedetomidine along with Bupivacaine for brachial plexus block. *National journal of medical research Jan-March* 2012;2(1):67-69.
- Amany S. Ammar, Khaled M. Mahmoud: Ultrasound-guided single injection infraclavicular brachial plexus block using bupivacaine alone or combined with dexmedetomidine for pain control in upper limb surgery: A prospective randomised controlled trial. *Saudi Journal of Anaesthesia*: April-June 2012;6(2):109-14.
- Liu K, Hsu CC, Chia YY. Effect of dexamethasone on postoperative pain and emesis. *Br J Anaesth* 1998;80:85-86.
- Niranjan Kumar Verma and Ashutosh Ranjan. (2016). A clinical comparison of Dexmedetomidine and Dexamethasone as adjuvant to Ropivacaine in Supraclavicular brachial plexus blocks for upper arm surgeries.. *Int. J. Adv. Res. Biol. Sci.* 3(7):56-61.