

A capillary hemangioma on the gingiva of an adult associated with a Phlebolith –a rare case report

Karthik R^{1,*}, Mohan N², Saramma Mathew Fenn³, Ravikumar PT⁴, Sabitha Gokulraj⁵

¹Reader, ²Professor & HOD, ^{3,5}Senior Lecturer, ⁴Associate Professor, Dept. of Oral Medicine & Radiology, Vinayaka Missions Sankarachariyar Dental College,

***Corresponding Author:**

Email: drkarthik17@gmail.com

Abstract

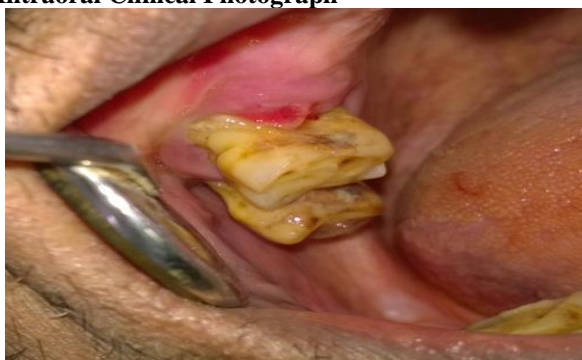Haemangioma is a benign tumor of capillary endothelium. This tumor presents at age 2-8 weeks and then goes through a rapid growth phase during the first year of life. It then begins to regress (involute) with complete regression in 50% of patients by age 5. Regression does not necessarily imply return of the skin to normal.⁽¹⁾

Keywords: Capillary Haemangioma, Gingiva, Diascopy, Tufted angioma, Haemangioendothelioma

Introduction

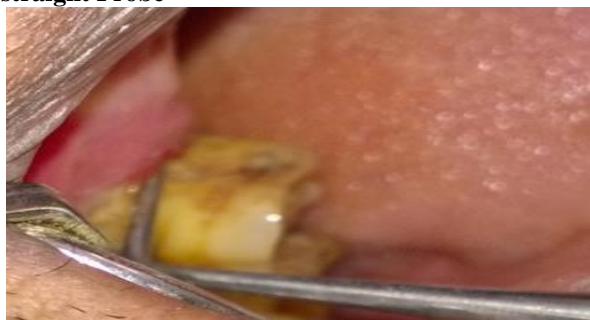A 54-year-old male patient reported to Our outpatient Department of oral medicine and Radiology with a chief complaint of bleeding in the upper right back tooth region in relation to 16 tooth region while brushing his teeth for past 3 months. History revealed his adjacent upper right second premolar tooth was extracted three months back. Intraoral examination revealed a single, sessile, nodular, bright red growth on the alveolar ridge mucosa in relation to mesial aspect of 16. No supra gingival calculus seen in relation to 26 gingival recession seen in 26. On palpation, the growth was firm and characteristic blanching seen on applying the pressure with a straight probe and the bright red colour reappears when the applied pressure is relieved (Diascopy test) and slight bleeding even on slight provocation present. No other abnormal discharge was seen. A provisional diagnosis of pyogenic granuloma was made. Pyogenic Granulomas are acute onset friable vascular papules that bleed frequently. Pyogenic granulomas are 5-10 mm soft red papules that bleed easily with minor trauma or even slight provocation.⁽³⁾

Intraoral Clinical Photograph

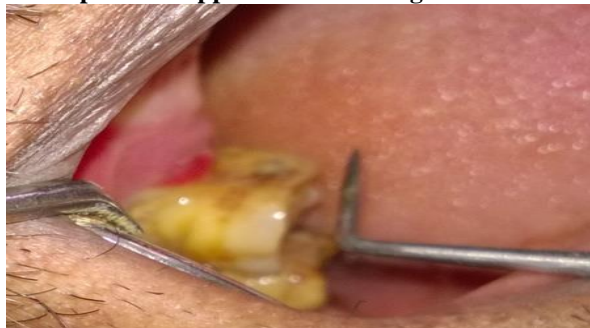

Diascopy Test

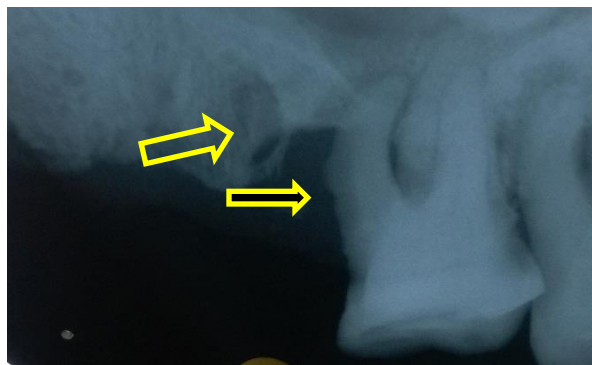
Lesion Blanches on application of Pressure with a straight Probe



Bright red colour reappears on relieving of the pressure applied from a straight Probe



Intraoral Periapical Radiograph



Intraoral Periapical Radiograph: IOPA (Intraoral Periapical Radiograph) reveals a discrete area of calcification, suggestive of a Phlebolith and cupping of the cortical border of the Maxillary alveolar bone in relation to 16.

Pretreatment Screening Investigations for Hemangiomas: Bleeding time (BT), Clotting time (CT) Blood glucose, Blood Urea Nitrogen(BUN), Thyroid function tests, Electrocardiogram (ECG) and Echocardiogram (ECHO) or Cardiac Ultrasound tests must be advised before operating Haemangiomas.

Treatment Modalities: Dentist must be very cautious in treating such Hemangiomas due to risk of severe bleeding. The treatment modality for this case includes the minimal invasive approach with the use of low wavelength Pulse diode laser, KTP (Potassium Titanyl Phosphate) or Nd-YAG (Neodymium-Yttrium-Aluminium-Garnet) laser therapy.

Discussion

Haemangioma is a benign tumor of capillary endothelium. This tumor presents at age 2-8 weeks and then goes through a rapid growth phase during the first year of life. It then begins to regress with complete regression in 50% of patients by age 5. Regression does not necessarily imply return of the skin to normal.⁽¹⁾

Hemangioma is a term that encompasses a heterogeneous group of clinical benign vascular lesions that have similar histologic features. It is benign lesion, which is a proliferating mass of blood vessels and do not undergo malignant transformation. Although a few cases are congenital, most develop in childhood. Occasionally, older individuals are affected. Although hemangioma is considered one of the most common soft tissue tumors of the head and neck; it is relatively rare in the oral cavity.⁽¹⁾

In 1962, David I Abramson classified Haemangiomas as follows
 Capillary hemangioma (strawberry mark), Cavernous hemangioma, Mixed cavernous and capillary angioma Hypertrophic or angioblastic hemangioma, Racemose hemangioma Port-wine stain or nevus vinosus Spider angioma (nevus araneus) Nevus flammeus (DeMorgan’s spot), Systemic hemangiomatosis or hemangioma unilateris, infectious hemangioma, pyogenic granuloma, Special regional hemangiomas of

the brain, tongue, gastrointestinal tract, liver, skeletal muscle and bone.

Congenital neurocutaneous syndromes associated with angiomatosis.

- i. Von Recklinghausen’s neurofibromatosis with angiomatosis
- ii. Bourneville’s syndrome with tuberous sclerosis
- iii. Sturge-Weber’s disease (encephalofacial angiomatosis)
- iv. Lindau-Von Hippels disease (hemangiomatosis of retina and cerebellum).

In 1982, Mulliken and Glowacki proposed a binary classification system of vascular anomalies.

International Society for the Study of Vascular Anomalies (ISSVA) system, classifies vascular anomalies into two broad biologic categories: vascular or vasoproliferative neoplasms and vascular malformations. A vascular malformation is a developmental error which remain static and grow proportionately with the Patient whereas Vascular tumors grow at a rate greater than the patient does.⁽²⁾

Vascular Tumors	Vascular Malformations
Glucose Transporter 1 Positive	Slow flow
Infantile Haemangioma	Capillary malformations Venous malformations Lymphatic malformations (Lymphangioma/ Cystic Hygroma)
Glucose Transporter 1 Negative	Fast flow
Congenital Haemangiomas	Arterial abnormalities
a)Rapidly involuting congenital Haemangiomas (RICH)	Arterio-venous Fistula
b)Non-involuting congenital Haemangiomas(NICH)	Arterio-venous malformations (AVM)
Tufted Angiomas (TA)	
Kaposiform Haemangioendothelioma Spindle cell Haemangioendothelioma Epithelioid Haemangioendothelioma	Combined vascular malformations (Various combinations of the above)
Angiosarcomas	
Dermatologically acquired -Lobular capillary Haemangioma (Pyogenic Granuloma)	

Clinical subtypes of Haemangioma: Based on its Location

Superficial: Bright Red Papules, Deep: Soft Blue nodule, Mixed: combination of the above.

Hemangiomas are often classified on the basis of their histological appearance and two main types are described: capillary and cavernous.^(3,4) Capillary hemangiomas are composed of many small capillaries lined by a single layer of endothelial cells supported in a connective tissue stroma of varying density. Cavernous hemangiomas are formed by large, thin-walled vessels or sinusoids lined with a single layer of endothelium which are separated by thin septa of connective tissues. Mixed hemangiomas consisting of both components may also occur.

The most common capillary malformations are Port-wine stain that appear as red macular stain on the skin and darkens over years.

Rapidly Involuting Congenital Hemangioma:

Rapidly involuting congenital hemangiomas undergo rapid proliferation in utero and are grossly visible at birth. They usually start involuting weeks after birth and fully involute around 2 years of age. They present as a raised, violaceous tumor with ectatic (dilated & distended) veins surrounded by a pale rim of vasoconstriction. Involution usually starts just after birth centrally and progresses toward the periphery, leaving behind a region of thin atrophied skin with little subcutaneous fat.

Noninvoluting Congenital Hemangioma: Non-involuting congenital hemangiomas always appear fully formed at birth as a solitary tumor and are more common in males. They demonstrate proportional growth with the child and will never involute. Typical lesions are round, average from 5 to 10 cm in diameter, with coarse overlying telangiectasias. Most are warm to palpation with a component of fast arterial flow that can demonstrated by Colour Doppler Ultrasound US. Histology reveals lobular collections of small, thin-walled vessels with a large, often stellate central vessel. Interlobular areas contain dilated dysplastic veins. Surgical excision is treatment of choice since they are solitary and do not involute

Infantile hemangiomas as unique vascular tumors that arise after birth during infancy, and undergo a characteristic proliferative phase followed by spontaneous involution. Infantile Haemangiomas (IH) are distinct from congenital hemangiomas, which are fully-formed at birth.

Angiosarcomas are rare and aggressive vascular tumors, rapidly proliferating with extensively infiltrating anaplastic cells derived from blood vessels and lining irregular blood-filled spaces. They can occur at any age, and in any part of the body, but most commonly arise on the skin, liver, breast, and spleen. Lymphedema, radiation, and exposure to carcinogens, such as vinyl chloride, arsenic, and thorium dioxide, have been indicated as possible risk factors. Angiosarcomas can resemble a skin infection, a bruise, or a nonhealing wound. They form distinct vascular channels that are irregular in size and shape. Initially, they can resemble infantile hemangiomas.⁽¹⁶⁾

Kaposiform hemangioendotheliomas frequently occur outside the cervicofacial region, affecting the trunk, extremities, and retroperitoneum before the age of 2. Clinically, they present as deeply seated, often bulging, indurated mass with a deep red-purple in color, edematous, and warm, with ecchymosis over and around the tumor.

Tufted angiomas can present as solitary tumors, large infiltrated macules, or plaques with overlapping papules. Onset is during infancy or early childhood (before 5 years), but occasionally is present at birth (15%). The characteristic histology is vascular tufts of tightly packed capillaries dispersed throughout the dermis in a cannonball pattern.

Clinically hemangiomas are characterized as a soft mass, smooth or lobulated, sessile or pedunculated and may be seen in any size from a few millimeters to several centimeters. The color of the lesion ranges from pink to red purple and tumor blanches on the application of pressure, and hemorrhage may occur either spontaneously or after minor trauma. They are generally painless. These tumors are mostly seen on the face, fingers and occasionally seen on oral mucosa.^(4,5)

The clinical subtypes of Hemangioma based on its location include Superficially located Hemangiomas as Bright red Papules, Deep seated Hemangiomas as Soft Bluish Nodule or as Mixed color of the above if a Hemangioma is located both superficial and also deeply seated.

They may occur as isolated lesions in the oral cavity, as multiple lesions affecting different parts of the body or in association with other developmental anomalies in the various angiomatous syndromes such as Osler-weber –Rendu syndrome or Hereditary Haemorrhagic Telangiectasia which is an autosomal dominant disease in which gastrointestinal telangiectasias are common and Genitourinary, Pulmonary, central nervous system and Hepatic lesions may also occur. Such Patients clinically present with epistaxis. Kasabach-Meritt Phenomenon where Platelet trapping and consumption coagulopathy thrombocytopenia (<10,000/mm³) and low fibrinogen levels and Hematologic abnormalities like anemia, elevated D-dimers, prothrombin time, and partial thromboplastin time may present associated with a vascular tumor such as Kaposiform hemangioendothelioma and tufted angioma.⁽⁶⁾ Klippel –trenaunay syndrome in which there is an overgrowth of an extremity secondary to a vascular malformation such as a capillary hemangioma(portwine stain or a venous malformation or a combination of the two. Park-weber syndrome, servelle martorell syndrome, proteus syndrome, clove syndrome, Mafucci syndrome, PHACES.

CLOVE Syndrome: CLOVES congenital lipomatous (fatty) overgrowth, vascular malformations, epidermal nevi and scoliosis/skeletal/spinal anomalies. Such

patients clinically present with asymmetric head, abnormal size of the digits along with portwine stain distributed in the extremities of the skin. Wilms tumor is noted in some patients affected with Cloves syndrome.⁽¹⁷⁾

Angio-osteohypotrophic syndrome (Servelle-Martorell angiodysplasia): Angio-osteohypotrophic syndrome (Servelle-Martorell angiodysplasia). It is characterized by venous or rarely arterial malformations, which may result in limb hypertrophy and bony hypoplasia.⁽¹⁸⁾

PHACES association*: Posterior fossa abnormalities, Hemangiomas in 5th cranial nerve region, Arterial intracranial anomalies, Cardiac anomalies/coarctation of the aorta, Eye anomalies, Sternal defects.

LUMBAR association: Lower body hemangioma, Urogenital anomalies and ulceration, Myelopathy, Bony deformities.

Anorectal and arterial malformations, Renal anomalies acronyms used to describe the LUMBAR association include "SACRAL" and "PELVIS." SACRAL, spinal dysraphism (neurological disorders related to malformations of spinal cord), anogenital anomalies, cutaneous anomalies, renal and urological anomalies, angioma (hemangioma) of the lumbosacral region; PELVIS, perineal hemangioma, external genitalia malformations, lipomyelomeningocele, vesicorenal abnormalities, imperforate anus, skin tag.

Maffucci syndrome: Multiple enchondromas and spindle cell hemangioendotheliomas

Regional syndromes with associated vascular malformations

Sturge-Weber: facial capillary malformation with intracranial capillary malformation, venous malformation, or AVM.

Klippel-Trenaunay: limb/ trunk capillary venous lymphatic malformations with overgrowth.

Parkes Weber: Combined Arterio-venous Malformations (CAVM) with skeletal or soft tissue hypertrophy affecting commonly lower extremities and Head and trunk.

Diffuse syndromes associated slow-flow malformations

Proteus syndrome: vascular malformations (capillary or venous), hamartomatous syndrome with overgrowth (hemihypertrophy and macrodactyly), lipomas, pigmented nevi.

Blue rubber bleb nevus (Bean) syndrome: Multiple cutaneous, musculoskeletal, and gastrointestinal tract venous malformations.

Epidermal nevus syndrome (Solomon syndrome): Vascular malformations (intracranial AVM), epidermal nevi, various developmental abnormalities of the skin, eyes, nervous, skeletal, cardiovascular, and urogenital systems.

Bannayan-Riley-Ruvalcaba syndrome: Vascular malformations (cutaneous, intracranial), macrocephaly, ectodermaldysplasia, lipomatous masses, and intestinal hamartomatous polyps, PTEN (Phosphatase and Tensin), a new guardian of the genome which plays an essential role in the maintenance of chromosomal stability and that loss of PTEN leads to massive alterations of chromosomes suppressor gene mutation association.⁽¹⁹⁾

Diffuse syndromes associated fast flow malformations

Hereditary hemorrhagic telangiectasia (Osler-Weber-Rendu): telangiectasias (skin, mucous membranes, gastrointestinal mucosa) and AVMs (lungs, liver, brain, spinal cord).

Clinically hemangiomas of the oral soft tissues often appear as a soft mass, smooth or lobulated, sessile or pedunculated and may be seen in any size from a few millimeters to several centimeters. They are usually deep red or bluish red in colour. Hemorrhage may occur either spontaneously or after minor trauma. They are generally painless. Periodontally these lesions often appear to arise from the interdental gingival papilla and to spread laterally to involve adjacent teeth.⁽⁵⁾

Diascopy is the technique of applying pressure to a suspected vascular lesion to visualize the evacuation of coloration, a finding that supports the fact that patent blood-filled spaces constitute the lesion⁽⁵⁾ and hemangioma may blanch on the application of pressure. Soft tissue hemangiomas may produce a cupped-out type of resorption of the bony cortex. Although these lesions do not undergo involution, they develop calcifications via phlebolith formation. These dystrophic calcifications in organized thrombi are often first seen on a radiograph. Those that occur in the parotid region are well-known to show multiple small, round radiodensities superimposed over the ramus and posterior body.⁽⁴⁾

If superficial lesions are not an esthetic problem and are not subject to masticatory trauma, they may be left untreated. Small and superficial lesions may be completely excised with relative ease. However, excision of more deeply seated lesions usually involves a wider surgical approach, which may result in a disfigurement that is difficult to accept for the treatment of these lesions. In addition, emergency surgery may become mandatory when arterial bleeding arises from intraosseous hemangiomas of the jaw following simple tooth extraction.

Central Hemangioma occur more frequently in the body of mandible with a peak incidence during the second decade of life.

Central Hemangiomas can lead to facial asymmetry, derangement of occlusion, displacement of teeth, supraeruption, premature exfoliation of Primary

teeth, early eruption of Permanent teeth, radiating pain to ear, TMJ or condyle.⁽²²⁾

Central Hemangiomas of bone arise from blood vessels within marrow spaces and may compromise arterial and venous vessels. Microscopically engorged vascular sinuses are present with an endothelial lining supported by connective tissue stroma interspersed by bony trabeculae, which are usually arranged at right angles to the surface giving a characteristic Honey comb appearance on Conventional orthopantomograms of central Hemangiomas.⁽²²⁾

Clinically central Hemangioma may mimic aneurysms, arterio-venous fistula or shunts. Radiographically central hemangioma can be confused with radiographic appearance of ameloblastoma, dentigerouscyst, multiple myeloma, osteosarcoma, fibrous dysplasia.⁽²²⁾

Management of oral hemangiomas varies considerably depending on the age of the patient and the size, extent and type of Haemangioma. The range of treatment includes the use of Lasers with a wavelength ranging between 400 nm and 1100 nm (PDL –Pulsed diode Laser, Nd: YAG (Neodymium-Yttrium-Aluminium-Garnet) and KTP (Potassium Titanyl Phosphate) are better absorbed by the hemoglobin chromophore, and penetrates deeply into the tissues and emits heat determining coagulation down to the depth of about 2-10 mm (it depends from the laser wavelengths), with approach called photocoagulation. Pulsed diode laser has a shallow penetration depth of ~1 mm, making it effective in treating relatively flat, and superficial hemangiomas. Nd:YAG and PTP lasers have been used successfully for deeper and thicker vascular tumors (> 1.5 mm), but are associated with a higher risk of scarring and ulceration. Co2 lasers are used to treat haemangiomas affecting vocal cords.⁽⁸⁾ Lasers are contraindicated in the treatment of Arterio-venous malformation, Cryotherapy. Very large Haemangiomas require Embolisation with the use of sclerosing agents such as sodium morrhuate, Polidoconal foam before surgical intervention.^(5,9,10) Most hemangiomas in infancy should be left alone, allowing for natural involution to occur. Exceptions to this may include psychological reasons and Haemangiomas at eyelids affecting vision such as infantile Haemangiomas which most commonly affect the skin, especially of the head and neck (60%), trunk (25%), and extremities (15%).⁽⁴⁾ Haemangiomas occurring on the liver does not require any treatment unless when they grew large and produce a mass effect. Haemangiomas can also occur in the synovial fluid of the knee joint, characterised by the presence of recurrent swellings and Pain in the affected knee joint.

Ultrasound with colour Doppler study using linear high frequency probes (8-17 MHz) helps in evaluating the presence, quantity and velocity of blood flow within such vascular lesions.⁽¹²⁾ Angiography, MRI helps in demonstrating characterisation between different

vascular lesions MRI with gadolinium contrast result in contrast-enhancement of vascular lesions. Peripheral-enhancement progressing to the center is typical of Low-flow venous malformation, whereas rapid enhancement throughout the mass characterizes an arterial malformation and, if accompanied by flow voids, an arteriovenous malformation computerized tomography are helpful in evaluation of calcification (phlebolith) especially in venous haemangiomas and when haemangiomas progress in its size and results in cupping of the involved alveolar bone.

Contrast enhanced Computed tomography scans, Hepatic angiography, Nuclear medicine study (Technetium) Tc 99-m labelled RBC scan are helpful in identifying Haemangiomas occurring on the liver. A Tc-99m RBC flow study demonstrating decreased perfusion and a late blood-pool study indicating increased blood volume are characteristic of hepatic hemangiomas.⁽¹⁵⁾

Immunostaining patterns of monoclonal antibody D2-40 that may help distinguishing Tufted Angiomas (TA) from Kaposiform Haemangioendothelioma (KH). D2-40 is a useful monoclonal antibody for immunohistochemical discrimination between KHE and TA. In addition, the difference of immunostaining pattern of D2-40 is limited to the peripheral area of capillary proliferation and surrounding dilated vessels; therefore, it is suggested that KHE and TA may reflect different stages in the evolution of a single entity. Namely, they may originate from stem cells possessing the characteristics of both lymphatic and blood vessel endothelial lineages.⁽²⁰⁾ Tufted angiomas are immunoreactive for lymphatic markers, such as podoplanin, LYVE-1, a member of the Link protein superfamily, was identified recently as a lymphatic-specific receptor for the extracellular matrix glycosaminoglycan found on the surface of endothelial cells of lymphatic vessels and Prox 1, but also negative for GLUT 1.

Management of such extensive Haemangiomas often requires a team approach consisting of an interventional radiologist, maxillofacial surgeon, Vascular surgeon and plastic surgeon.⁽²⁶⁾ If severe blood loss is anticipated, the operation must be performed in hospital setting where blood transfusion facilities are available. Various treatment modalities used in the management of hemangiomas include intralesional injection of sclerosing agents such as sodium morrhuate, cryotherapy, Nd-YAG laser. Surgical embolization with the help of Polidoconal foam.⁽¹²⁾ Gelfoam torpedoes are often used for facial artery embolization. Injuries to the carotid artery with dissections and pseudoaneurysm formation are often treated with stenting, occasionally combined with coil placement, although without proven efficacy.⁽¹²⁾

Propranolol, a beta blocker is useful in treating infantile haemangiomas. The standard initial dose is 1mg/kg/day in three divided doses per day. The

possible beneficial mechanisms include vasoconstriction, inhibition of angiogenesis and induction of apoptosis.⁽¹³⁾

The topical β -blocker timolol is now an alternative to oral propranolol for smaller Infantile Haemangiomas. Subcutaneous Injection of Interferon- α results in inhibition of endothelial, fibroblast, and smooth muscle cell proliferation in infantile hemangiomas at a dosage of 3×10^6 IU/m²/d as a subcutaneous injection.⁽¹⁴⁾

Conclusion

A vascular lesion is an all-encompassing term used to describe a wide range of conditions consisting of an abnormal number, structure, or position of blood vessels.

Hemangiomas can cause obstruction of vital function depending on organ it is located such as vision (orbital cavernous Haemangiomas), strabismus, breathing (Haemangioma occurring in the lungs), eating, defaecation (in case of gastrointestinal telangiectasia in sturge weber syndrome) or urination (Vertebral cavernous Haemangiomas), ulceration followed by bleeding and infection if haemangioma is located in pressure areas. Oral Hemangiomas are rare and such lesions should be carefully evaluated and must not be surgically intervened unless it causes severe facial disfigurement, bleeding or interfere with function.

Regression of Haemangiomas results in hypopigmentation, telangiectasia, fibrofatty deposits, ulceration, scar. Dentists must therefore be aware of such lesions when making diagnosis and attempts at excision of apparently innocent lesions may result in serious bleeding.⁽¹³⁾

References

- Altman RS, Schwartz RA: Childhood cutaneous hemangiomas. *Cutis* 72:201-205,2003.
- Mulliken JB, Glowacki J. Hemangiomas and vascular malformations in infants and children: a classification based on endothelial characteristics. *Plast Reconstr Surg* 1982;69:412-422
- Lin RL, Janniger CK: Pyogenic Granulomas. *Cutis* 74:229-233,2004.
- Marx RE, Stern D. Oral and maxillofacial pathology: a rationale for diagnosis and treatment, 1st Ed. Illinois: Quintessence Publishing; 2003. 442 p.
- Greenberg M, Glick M, Ship JA. Burkett's oral medicine. 11th Ed. Ontario: PMPH; 2008. 145 p.
- Maguiness S, Guenther L: Kasabach Merritt syndrome. *J Cutan Med Surg* 6:335-339,2002.
- Barak S, Katz J, Kaplan I. The CO₂ laser in surgery of vascular tumors of the oral cavity in children. *ASDC J Dent Child.* 1991;58(4):293-6.
- Chin DC. Treatment of maxillary hemangioma with sclerosing agent. *Oral Surg Oral Med Oral Pathol.* 1983;55:247-9.
- Greene LA, Freedman PD, Friedman JM, et al. Capillary hemangioma of the maxilla. A report of two cases in which angiography and embolization were used. *Oral Surg Oral Med Oral Pathol* 1990;70(3):268-73.
- Burstein FD, Simms C, Cohen SR, Williams JK, Paschal M. Intralesional laser therapy of extensive hemangiomas in 100 consecutive pediatric patients. *Ann Plast Surg.* 2000;44:188-194. doi: 10.1097/0000637-200044020-00011.
- Vlachakis I, Gardikis S, Michailoudi E, Charissis G. Treatment of hemangiomas in children using a Nd: YAG laser in conjunction with ice cooling of the epidermis: techniques and results. *BMC Pediatrics.* 2003;3:2. doi:10.1186/1471-2431-3-2.
- Daniel Cooke, Basavaraj Ghodke, Sabareesh Kumar Natarajan, Danial Hallam, Embolization in Head and Neck, *Semin Intervent Radiol.* 2008 Sep;25(3):293-309. doi: 10.1055/s-0028-1085929PMCID: PMC3036447.
- McGee P, Miller S, Black C, Hoey S. Propranolol for infantile haemangioma: A Review of Current Dosing Regime in a Regional Paediatric Hospital. *The Ulster Medical Journal.* 2013;82(1):16-20.
- Püttgen KB, Diagnosis and management of infantile hemangiomas. *Pediatr Clin North Am.* 2014 Apr;61(2):383-402. doi: 10.1016/j.pcl.2013.11.010. Epub 2014 Feb 18.
- Dov Front, Henry D. Royal, Ora Israel, J. Anthony Parker, and Gerald M, Scintigraphy of Hepatic Hemangiomas: The Value of Tc-99m-labeled Red Blood Cells: Concise Communication.
- Coldwell D M, Baron R L, Charnsangavej C. Angiosarcoma. Diagnosis and clinical course. *Acta Radiol.* 1989;30(6):627-631.
- Sapp JC, Turner JT, van de Kamp JM, van Dijk FS, Lowry RB, Biesecker LG. Newly delineated syndrome of congenital lipomatous overgrowth, vascular malformations, and epidermal nevi (CLOVE syndrome) in seven patients. *Am J Med Genet.* 2007;143A:2944-2958. <http://www.ncbi.nlm.nih.gov/pubmed/17963221>.
- Karuppall R, Raman RV, Valsalan BP, Gopakumar T, Kumaran CM, Vasu CK. Servelle-Martorell syndrome with extensive upper limb involvement: a case report. *Journal of Medical Case Reports.* 2008;2:142. doi:10.1186/1752-1947-2-142.
- Y Yin and W H Shen, PTEN, a new guardian of the genome, *Oncogene* (2008) 27, 5443-5453; doi:10.1038/onc.2008.241.
- Arai E, Kuramochi A, Tsuchida T, Tsuneyoshi M, Kage M, Fukunaga M, Ito T, Tada T, Izumi M, Shimizu K, Hirose T, Shimizu M, Usefulness of D2-40 immunohistochemistry for differentiation between kaposiform hemangioendothelioma and tufted angioma.
- Gianfranco G, Eloisa F, Vito C, Raffaele G, Gianluca T, Umberto R. Color-Doppler Ultrasound in the Diagnosis of Oral Vascular Anomalies. *North American Journal of Medical Sciences.* 2014;6(1):1-5. doi:10.4103/1947-2714.125852.
- Marwah et al, Central Hemangioma, *Pediatric Dentistry,* 28:5,2006.