

## Non-ulcerative Peripheral ossifying fibroma: A rare case report and review of literature

Saloni<sup>1</sup>, Princy Mahejan<sup>2</sup>, Sarfaraz Padda<sup>3</sup>, Pradhuman Verma<sup>4,\*</sup>

<sup>1,2</sup>PG Student, <sup>3</sup>Professor & HOD, <sup>4</sup>Associate Professor, Dept. of Oral Medicine & Maxillofacial Radiology,

**\*Corresponding Author:**

Email: pradhuman\_verma@rediffmail.com

### Abstract

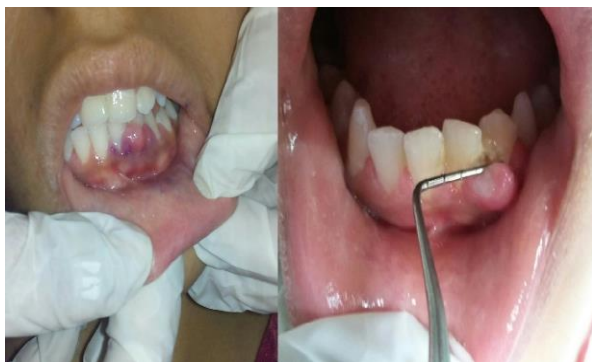Localized gingival enlargements are more commonly seen and it becomes sometimes difficult to differentiate between them clinically. In order to identify these localized gingival lesions, histopathology examination is the key of diagnosis. The Peripheral ossifying fibroma (POF) is one such reactive lesion described with various synonyms and is believed to arise from periodontal ligament comprising 9% of all gingival growths. POF is a focal, non-neoplastic, relatively uncommon reactive tumor that often arises from the interdental papillae and is more common in maxillary anterior region with more female predilection and most common in children and young adults. The treatment of choice is surgical excision of the lesion, including periosteum, to prevent recurrence. Here is a rare case of POF reported in 16 year old female in mandibular anterior region.

**Keywords:** Epulis, Histopathology, Peripheral ossifying fibroma

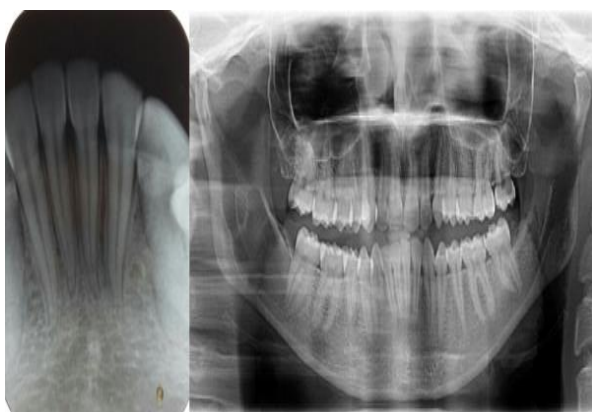
### Case Report

A 16 year old female patient, reported to Department of Oral Medicine and Radiology, Surendera Dental College & Research Institute Sriganaganagar with a chief complaint of mildly painful and gradually enlarging soft tissue growth over the gums in lower front teeth region since 15 days. [Fig. 1]. History of presenting illness revealed that growth was gradual in onset, initially small in size and increased over time to attain the present size. It was painful causing difficulty in chewing food and unaesthetic appearance on smiling. Past dental history revealed that same lesion was present at same site, which was excised surgically one month back. There was history of recurrence after 15 days with associated pain and swelling which aggravates on touching the lesion and relieved on its own after sometime. The lesion was interfering with her mastication and felt uncomfortable. Also there is history of spontaneous bleeding while brushing and sometimes during eating and spitting. The medical and familial history was non-contributory. General physical examination revealed that all the vital signs were in normal limits. No gross facial asymmetry was appreciated on extra oral examination. Intraoral examination revealed well defined, reddish pink lobulated gingival growth with sessile base on labial aspects of 31 32 and 33. The growth extended anteroposteriorly from distal aspect of 31 to mesial aspect of 33 and superoinferiorly from middle of coronal portion of 31 32 upto lower labial vestibule inferiorly. The maximum dimensions of 5mm x4mm were noted. There was a solitary whitish indentation surrounded by slightly erythematous area present on superior margin of mesial aspect of growth due to chronic trauma from 21. On palpation, all the inspectory findings were confirmed regarding size, shape & extent. It was soft to firm in consistency,

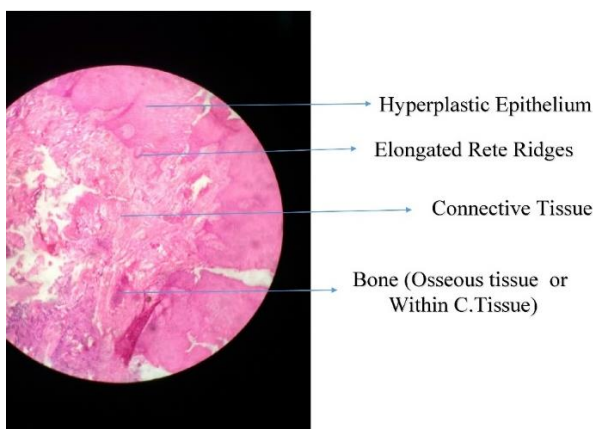
tender and mobile. On probing, pseudo pockets were found irt 31 32 with 5mm, 4.5mm in length respectively. There was no visible discharge seen on palpating the growth. Based on clinical findings, a provisional diagnosis of Epulis was made and differential diagnosis of pyogenic granuloma, irritational fibroma, peripheral ossifying fibroma, peripheral giant cell granuloma and localized gingival hyperplasia were considered. The intraoral periapical radiograph 31 32 33 and orthopantomographic examination showed no visible osseous changes [Fig. 2]. All the hematological reports were in normal limits except ESR (16mm/hr.) which was slightly raised. Later with patient consent, excision of the lesion was done under local anesthesia and the specimen was sent for histopathological examination. The histopathological examination revealed hyperplastic epithelium, parakeratinised stratified squamous in nature along with elongated rete-ridges. Underlying connective tissue stroma was loose, cellular, and fibrous with interlacing collagen fibers and fibroblast cells. The mineralized tissue in the form of bone was present in some areas of the stroma. Presence of marked chronic inflammatory cell infiltrate, chiefly consisting of lymphocytes & numerous small and medium sized blood vessels with extravasated RBCs were evident. These features were suggestive of non-ulcerative POF [Fig. 3]. The patient presented for follow-up examination 20 days postoperatively. The surgical site appeared to be healing well [Fig. 4]. There was no evidence of recurrence of the lesion, and the patient was asymptomatic and still on follow up.



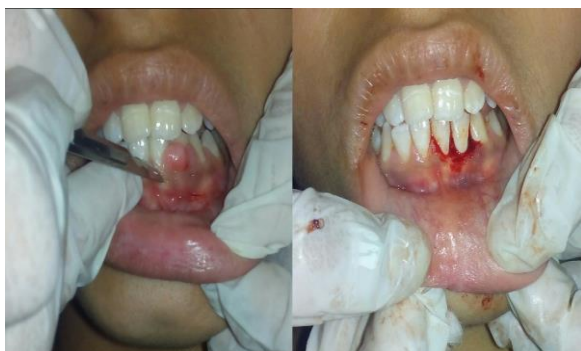**Fig. 1: Pre-operative Photographs**



**Fig. 2: Intraoral Radiographs showing IOPA & OPG**



**Fig. 3: Histopathological Examination**



**Fig. 4: Postoperative photographs**

## Discussion

Peripheral ossifying fibroma (POF) is a slowly growing benign tumor with a high recurrence rate.<sup>(1)</sup> The term “Epulis” coined by Eversole and Robin in 1972 includes a series of reactive gingival lesions often produced by irritating agents.<sup>(2)</sup> POF is a lesion of the gingival tissues representing up to 2% of all oral lesions that are biopsied.<sup>(3)</sup> Lesions occurring on gingiva include POF, peripheral giant cell granuloma (PGCG), focal fibrous hyperplasia, calcifying fibroblastic granuloma, peripheral cementifying fibroma, and peripheral fibroma with cementogenesis, peripheral cemento-ossifying fibroma and pyogenic granuloma. The latter condition could represent an early, immature form of POF.<sup>(4)</sup> Usually, maxilla is more affected than mandible with 50% of maxillary growth occurs in the anterior region.<sup>(5)</sup> POF sometimes represents maturation of a pre-existing pyogenic granuloma or peripheral giant cell granuloma.<sup>(6)</sup> Zahang *et al*, in a study of 2,439 cases of Epulis, recorded the prevalence of 61.05% peripheral fibromas, 19.76% pyogenic granulomas, 17.67% POF, and 1.52% peripheral giant cell granulomas.<sup>(7)</sup> Buchner and Hansen hypothesized that early POF is present with ulcerated nodules having little calcification, which may allow a misdiagnosis as pyogenic granuloma.<sup>(8)</sup> Shepherd first reported and described POF as ‘alveolar exostosis’.<sup>(4)</sup>

POF as observed in present case, is a focal, non-neoplastic, reactive tumor-like growth of soft tissue that often arises from the interdental papilla, relatively uncommon lesion, comprising nearly 3% of oral lesions. Definitive etiology of POF remains unknown. The inflammatory hyperplasia originating in the superficial periodontal ligament is considered to be a factor in the histogenesis of the POF. These lesions originate in the cells of the periodontal ligament, is evident due to following reasons: 1. POF exclusively appears in the gingival tissue, close to the periodontal ligament. 2. Oxytalan fibers are present within the mineralized matrix of some lesions. 3. The age distribution of the lesions is inversely proportional to the number of permanent teeth lost. 4. POF fibrocellular response is similar to that of other reactive gingival lesions originating in the periodontal.<sup>(4)</sup>

Histologically, POF can exhibit either ulcerated or intact stratified squamous epithelium. In a typical ulcerated lesion, three zones could be identified: Zone 1: The superficial ulcerated zone covered with the fibrinous exudates and enmeshed with polymorphonuclear neutrophils and debris. Zone 2: The zone beneath the surface epithelium composed almost exclusively of proliferating fibroblasts with diffuse infiltration of chronic inflammatory cells mostly lymphocytes and plasma cells. Zone 3: More collagenized connective tissue with less vascularity and high cellularity; osteogenesis consisting of osteoid and bone formation is a prominent feature, which can even reach the ulcerated surface in some cases. The calcified

material can generally take one or more of the following 4 forms: (a)Mature lamallated trabecular bone; (b) immature, highly cellular bone; (c) circumscribed amorphous, almost acellular, eosinophilic, or basophilic bodies; (d)minute microscopic granular foci of calcification.<sup>(9)</sup> The non-ulcerated lesions are typically identical to the ulcerated type except for the presence of surface epithelium. Recurrence rate of POF is said to be high.<sup>(10)</sup> Cementum like material is found in less than one fifth of the lesions and dystrophic calcifications are more prevalent in ulcerated lesions.

Treatment includes proper surgical intervention that ensures thorough excision of the lesion including the involved periosteum and the periodontal ligament. Thorough scaling and root planning should be accomplished. Recurrence rate of POF is said to be high probably occurs due to incomplete removal of lesion, repeated injury or persistence of local irritants. So regular follow up is necessary as was done in present case.

### Conclusion

POF is an uncommon slow growing reactive lesion of gingival which may be symptomatic or asymptomatic. Many cases will progress for long periods before patients seek treatment because of the lack of symptoms associated with the lesion. A slowly growing pink soft tissue nodule in the anterior teeth region of an adolescent should raise suspicion of a POF. Close postoperative follow-up is required because of the growth potential of incompletely removed lesions and the 8%–20% recurrence rate.

### References

1. Koregol AC, Kalburgi N, Kamat A, Mary J, Kotecha A.A Peripheral ossifying fibroma in a rare site: A clinicopathological report. *J Health Sci Res* 2015;6(2):60-4.
2. Eversole LR, Robin S. Reactive lesions of gingiva. *J Oral Pathol* 1972;1(1):30-8.
3. Marcos JAGD, Marcos JGDM, *et al.* Peripheral ossifying fibroma: a clinical and immunohistochemical study of four cases. *J oral sci*.vol 52,No.1,95-99,2010.
4. Sairam V, Padmaja K, Parveen Kumar B, Naresh G, Vikas Reddy G. Peripheral ossifying fibroma. *Adv Dent & Oral Health*, vol 1,Issue 3,2016.
5. Vijayan V, Paul K A, Manoj M, Babu SK. Peripheral ossifying fibroma. *Univ Res J Dent* 2015;5:99-102.
6. Jain A, Deepa D. Recurrence of Peripheral Ossifying Fibroma: A Case Report .*People's J of Sci Research*, vol 3 (1), 2010.
7. Farquhar T, MacLellan J, Dymont H, Anderson RD. Peripheral ossifying fibroma: A case report. *J Canadian Dent Assoc* 2008;74(9):809-12.
8. Buchner A, Ficarra G, Hansen LS. Peripheral odontogenic fibroma. *Oral Surg Oral Med Oral Pathol* 1987;64:432-8.
9. Poonacha KS, Shigli AL, Shirol D. Peripheral ossifying fibroma: A clinical report. *Contemp Cli Dent* 2010;1(1):54-6.
10. Nazareth B, Arya H, Arora SAR, Arora R (2011) Peripheral Ossifying fibroma A Clinical Report. *Int. J Odontostomat* 5(2):153-156.