

Meigs Syndrome: A paradoxical presentation

Bharathi KR^{1,*}, Vijayalakshmi S², Divya K³

¹Assistant Professor, ²Professor & HOD, ³PG Student, Adichunchanagiri Institute of Medical Sciences, Mandya, Karnataka

***Corresponding Author:**

Email: bharathikr84@gmail.com

Abstract

Meigs disorder an uncommon, particularly fascinating disorder of the old, which is portrayed by a triad of a benign ovarian tumor (fibroma, fibrothecoma, Brenner tumour, and occasionally granulosa cell tumour), hydrothorax, ascites.

The possible conclusion of this pathology is fundamentally clinical regardless of the precious esteem that imaging strategies have. It also creates a condition of perplexity in the determination by impersonating ovarian tumours and in this manner turns into a diagnosis of exclusion. Hence, precise diagnosis gets to be distinctly important to differentiate it from ovarian malignancy considering the reality of it having a good prognosis.

The case herein concerns a 65-year-old postmenopausal woman coming with history of mass per abdomen with acute pain abdomen, with clinical and radiological examination revealing a large pelvic tumour of size 15*12 cm with cystic and solid components associated with bilateral pleural effusion with moderate ascites.

Keywords: Fibroma, Ascites, Meigs Syndrome

Introduction

Meigs syndrome has a classical triad of features: a benign ovarian tumor combined with ascites and a pleural effusion.⁽¹⁾ The condition is seen in association with less than 1% of ovarian tumors and is very rare in younger women.⁽²⁾ The clinical presentation is most frequently related to the ascites and generally right-side pleural effusion, while there may also be history of non-specific symptoms such as abdominal discomfort, fatigue, and weight loss and a tumor arising from the pelvis which may be palpable.

Case Report

A 65-year-old postmenopausal woman presented to us with history of acute pain abdomen with vomiting. She also complained of mass per abdomen since 2 months with a gradual increase in size. She had attained menopause 20 years back with no postmenopausal symptoms. She was para 3 with 3 living children, with marital life of 50 yrs, tubectomised with last childbirth being 39 yrs back. No other significant history of any comorbidity seen. Upon clinical examination, she appeared pale with associated platyonychia. Was diagnosed to be hypertensive with grade 3 hypertensive retinopathy changes after admission. Respiratory system examination revealed decreased air entry on the left basal areas. Per abdominal examination revealed a large irregular mass with a bosselated surface of about 24 to 26 gravid uterine size, firm in consistency occupying the quadrants of the abdomen as shown in Fig. 1.

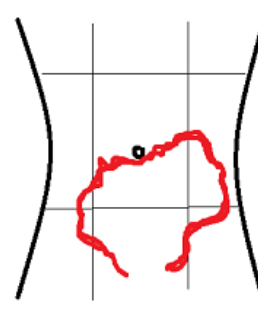


Fig. 1

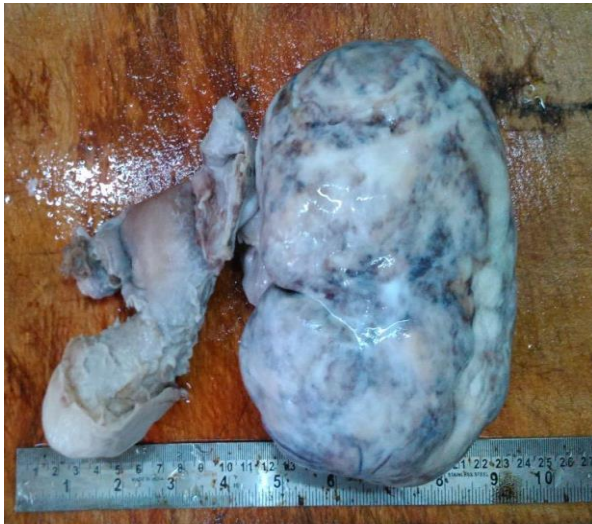All borders of the mass were well made out except for the lower border suggesting pelvic origin. Mass had restricted mobility in all quadrants. Shifting dullness positive. On per speculum examination third-degree uterovaginal prolapse was present. On per vaginal examination left forniceal fullness was felt with right fornix appearing free. Bimanual examination revealed uterus being felt separately from the mass. No transmitted mobility felt.

Ultrasonography revealed left sided moderate pleural effusion with a hypoechoic mass of 15*12 cm in left lumbar region with few cystic changes without any evidence of vascularity.

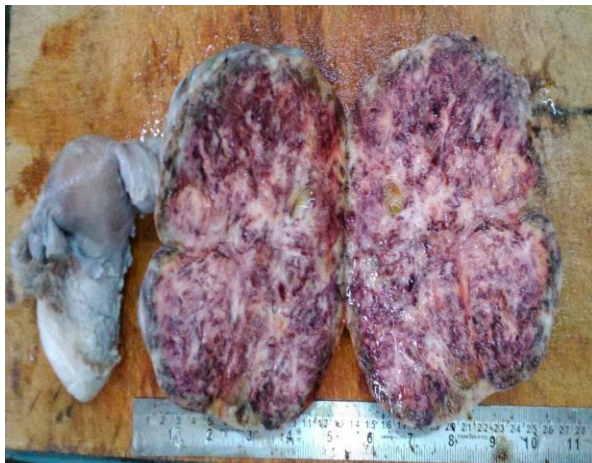CT scan revealed a large pedunculated isodense space occupying lesion with hypodense areas within arising from left adnexa of approximate size 9.6*14.7*12.9 cms, extending superiorly up to level of L3 and abutting superior surface of bladder inferiorly with moderate enhancement of solid components with few non-enhancing cystic /necrotic areas within associated with bilateral pleural effusion (left > right) and moderate ascites. No evidence of significant abdominal lymphadenopathy. Differential diagnosis considered were

- Neoplastic left ovarian lesion
 - Pedunculated broad ligament fibroid.
- CA-125 level was 152.6 U/ml.

The lady was then taken up for staging laparotomy after control of hypertension in view of ovarian tumour. On laparotomy, a left sided ovarian mass of about 15*12*7 cm was noted. Total abdominal hysterectomy with bilateral salpingo-oophorectomy was done. Uterus was atrophic with cervical elongation, and weighing about 100 gms. Right sided tube and ovary appeared atrophic. Left sided ovarian mass weighed 1 kg. All other intraabdominal organs appeared normal.

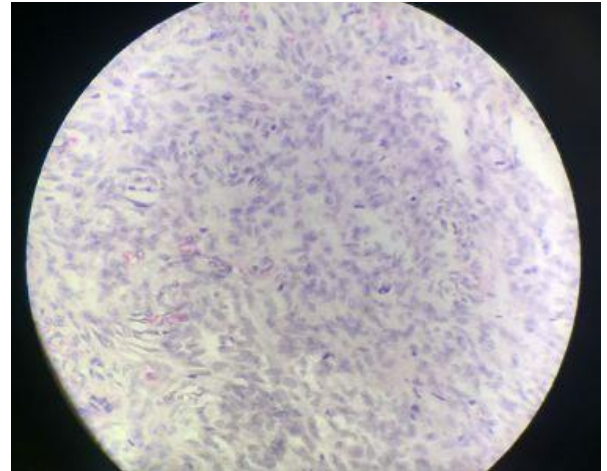


Gross specimen showing uterus & cervix with normal appearing right fallopian tube & ovary with left sided ovarian mass



Gross appearance of the cut section of ovarian

Histopathological examination revealed the mass being ovarian fibroma.



Histopathological section of ovarian mass- Fibroma

The postoperative period was uneventful, with regression of pleural effusion postoperatively. Postoperative chest x-ray and ultrasonography did not reveal any abnormality.

Discussion

Meig's syndrome presents as a triad of ovarian tumour, ascites, and pleural effusion. It usually occurs in an elderly female. The First report of this condition was in Dame Mary Page, wife of Sir Gregory Page, England, who died in 1728 at her 56th year. Otto Spiegelberg in 1866 described a patient with fibroma, ascites, hydrothorax and erroneously concluded diagnosis of ovarian pregnancy.⁽³⁾

In 1934, Salmon described the association of pleural effusion with benign pelvic tumors, and Meig's described the condition.⁽⁴⁾ In 1937, Meigs and Cass described 7 cases of ovarian fibromas associated with ascites and pleural effusion.⁽⁵⁾ In 1954, Meigs proposed limiting true Meigs syndrome to benign and solid ovarian tumours accompanied by ascites and pleural effusion, with the condition that removal of the tumour cures the patient without recurrence. It is also known as Demon-Meig's syndrome, Meig's- Cass syndrome. Histologically, the benign ovarian tumor may be a fibroma, thecoma, cystadenoma, or granulosa cell tumor.

Ovarian Fibromas which are seen mostly in fifth or 6th decade accounts for 4% of all ovarian neoplasms. These tumours are known to have a very low malignant potential. When associated with Meigs syndrome these mimic ovarian carcinomas, with nearly 10-15% of all fibromas being associated with ascites. Meig's is overall seen in less than 1% of ovarian fibromas, less than 10% of these cases present in women under the age of 30 years.⁽⁶⁾ The key diagnostic differential is to distinguish the low malignancy potential fibroma from the aggressive malignancy of ovarian fibrosarcoma. This differentiation can be established using a mitotic proliferation index. An index with less than three mitoses per 10 HPF is usually linked to benign disease

and those with four to 25 mitoses per 10 HPF are associated with malignant fibrosarcoma.⁽²⁾

Meigs syndrome is a diagnosis of exclusion.

Ascitic fluid and pleural fluid in Meigs syndrome can be either transudative or exudative. Meigs suggested that the fluid in the abdomen originated from the edematous fibroma that can leak fluid.⁽¹⁾ Meigs performed electrophoresis on several cases and determined that pleural and ascitic fluids were similar in nature. Tumor size, rather than the specific histologic type, is thought to be the important factor in the formation of ascites and accompanying pleural effusion. A discrepancy between the arterial supply to large mass of tumor tissue and its limited venous and lymphatic drainage may contribute to stromal edema and transudation.⁽⁷⁾

CA-125 levels is usually seen to be elevated in 80% of patients with ovarian cancer. It is said to be elevated as a result of peritoneal irritation rather than direct production from tumour.⁽⁸⁾ The CA 125 tumor marker is generally elevated in patients with malignant ovarian tumor. It can, however, be elevated in benign disorders, such as endometriosis, pelvic inflammatory disease and uterine leiomyoma. Serum CA 125 levels can also increase in pericardial, pleural and peritoneal irritation or inflammation.^(7,9) At this point, it must be underlined that an ovarian mass combined with pleural and peritoneal effusions does not always represent an advanced malignancy, even with an elevation of CA 125 value.^(9,10) Laparotomy and histopathological examination are required for the correct diagnosis and treatment of ovarian tumors, since elevated serum CA 125 levels can be falsely positive for ovarian malignancy.⁽⁷⁾

Conclusion

This case draws attention to the perplexity involved in clinical diagnosis and management of complications of benign ovarian disease like ascites and pleural effusion as in Meigs syndrome. Elevated CA 125 levels though also seen in Meigs syndrome creates confusion leading to a misdiagnosis of malignant ovarian tumour. A proper diagnosis with the removal of the tumor is curative of this syndrome with a very good prognosis.

References

1. Meigs JV, Cass JW: Fibroma of the ovary with ascites and hydrothorax with a report of seven cases. *Am J Obstet Gynecol* 1937, 33:249–267.
2. Prat J, Scully RE: Cellular fibromas and fibrosarcomas of the ovary: a comparative clinicopathologic analysis of seventeen cases. *Cancer* 1981,47:2663–2670.
3. Salah IA & Elfadil M E: Ascites is not necessarily an ominous sign in women with a pelvic tumour. *Sudan JMS* 2006; vol 1(2).
4. J. V. Meigs: Tumors of the female pelvic organs. New York, Macmillan, 1934:262-263.
5. J. V. Meigs; J. W. Cass: Fibroma of the ovary with ascites and hydrothorax, with a report of seven cases. *American Journal of Obstetrics and Gynecology*, St. Louis, 1937;33:249-267.
6. Samanth KK, Black WC 3rd: Benign ovarian stromal tumors associated with free peritoneal fluid. *Am J Obstet Gynecol* 1970, 107:538–545.
7. Abad A, Cazorla E, Ruiz F, Aznar I, Asins E, Llixiona J. "Meigs' syndrome with elevated CA 125: case report and review of literature" *Eur J Obstet & Gynecol reprod Biol* 1999,82:97-99.
8. Lin JY, Angel C, Sichel JZ: Meigs syndrome with elevated serum CA 125. *Obstet Gynecol* 1992,80:563-566.
9. Sommela L, Triggiani E. [Meigs syndrome: Its clinical picture and treatment]. *Ann Ital Chir* 2000;71(1):115-119.
10. Domingo P, Montiel JA, Monill JM, Prat J. Pseudo-Meigs syndrome with elevated CA 125 levels. *Arch Intern Med* 1998;158(12):1378-1379.