

## IDENTIFICATION OF HUMAN LIMBAL STEM CELL BY P63, A SPECIFIC STEM CELL MARKER IN CADAVERIC LIMBAL TISSUE AND IN *in-vitro* LIMBAL STEM CULTURE

Rohitkundap,<sup>1</sup> Diksha Prakash,<sup>2</sup> Amit Rai,<sup>3</sup> Shashikant Patne,<sup>4</sup> Samir Kumar,<sup>5</sup> OPS Maurya,<sup>6</sup> Abhishek Chandra<sup>7</sup>

1. & 2 . Ex. M.S. Student, Department of Ophthalmology, IMS, BHU

3. Assistant Professor, Department of Genetic, Faculty of Sciences, BHU

4. Assistant Professor, Department of Pathology, IMS, BHU

5. Jr. Resident, 6. Professor, 7. Ex-Consultant, Department Ophthalmology, IMS, BHU.

### Corresponding Author:

OPS Maurya

### ABSTRACT

**Aim:** Identification of human limbal stem cell by p63, a specific stem cell marker in cadaveric limbal tissue and in *in-vitro* limbal stem culture. **Methods:** Identification of limbal stem cell was done on cadaveric limbal biopsy sample using immuno-histo-chemistry analysis with p63 staining and a secondary anti mouse (GOAT) Fab fragment antibody staining. *In-vitro* cultured limbal stem cells over amniotic membrane were also stained by p63 marker. **Results:** Basal layer of limbus shows intense staining for p63. Stained cells showed brown color (due to DAB chromogen). There was no uniform staining of basal layer. Some cells showed intense staining while other cells did not show stain. This indicates that limbal stem cells are not uniformly distributed in basal limbal layer but are present in small groups. The time taken by human limbal epithelial cells to form a monolayer on denuded amniotic membrane was 2-3 week and 4-6 layers sheet was obtained after 4 weeks. **Conclusion:** p63 was maximally expressed in limbal basal layer which is highly mitotic layer and is responsible for epithelial cell proliferation. Similarly p63 also stained cultured stem cells over denuded amniotic membrane which proves that cultured limbal cells have high mitotic activity and therefore are true stem cells rather than differentiated epithelial cells.

### Introduction

The ocular surface consists of the cornea, the conjunctiva, and the corneoscleral junction which is known as limbus. Cornea serves two important functions as a major refractive surface to focus light on the retina, and other as a protective barrier for the inner tissues. The cornea is transparent structure composed of stratified non-keratinized squamous epithelium, Bowman's membrane, stroma, Descemet's membrane and endothelium.

Epithelial cells undergo constant renewal and regeneration with a turnover period of 5-6 days. This renewal and regenerative process is depends on stem cells which reside within limbus.

The limbus harbours the stem cells of the corneal epithelium in a very protective environment. Limbal epithelium consists of several organized layers, devoid of goblet cells and populated by Langerhans cells and melanocytes. The melanocytes are supposed to guard the limbal stem cells

(LSCs) from harmful ultraviolet rays. They also quench UV-induced oxidant formation in the corneal epithelium by their anti-oxidative activity. The deep projections into vascularized limbal epithelium are called "palisades of Vogts". Limbal epithelial stem cells are slow cell cycling and label retaining cells. It maintains the corneal epithelium by giving birth to transient amplifying cells (TAC), which give rise to post mitotic cells and terminally differentiated cells. Limbus serves as a barrier which prevents migration of conjunctival epithelial cells of on to the corneal surface.

### Identification of limbal stem cells:

Unfortunately, there are no definitive markers for the identification of adult stem cells in general and corneal stem cells in particular. Rather, the presence and absence of various morphological features, proteins and gene expression are used in combination to attentively identify the stem cell and transient amplifying cells (TAC) populations from the fully differentiated cell population. Recent studies have identified putative stem cell markers. These can be divided into two major categories: negative and positive markers. Negative markers are those that are absent or poorly expressed in the limbal basal cells include K3/K12, Cx43, and Cx50 etc. Positive markers would include molecules that are highly expressed in the limbal region versus the other regions of ocular surface includes  $\beta 1$  integrin,  $\beta 4$  integrin, p63, Cyclin D etc.

Limbal stem cell deficiency (LSCD) is characterized by triad of conjunctivalization (conjunctival epithelial in growth over cornea), vascularization, and chronic inflammation. Such ocular surface disorders results in ocular discomfort and reduced visual acuity. Limbal stem cells are deficient in congenital or acquired ocular surface disorders like chemical or thermal burns, Stevens-Johnson syndrome, ocular cicatricial phemphigoid, aniridia, ectodermal dysplasia and multiple surgical interventions. Penetrating keratoplasty

done for vascularised corneal scars with conjunctivalization invariably failed. This was because the transplanted donor epithelium consisted of transient amplifying cells (with limited proliferative potential) and lacked corneal epithelial stem cells.

Treatment modality in such cases is restoration of limbal stem cells. Limbal tissue obtained from autologous (in case of unilateral LSCD) or allogeneic (in case of bilateral LSCD) limbal epithelial graft. Allogeneic limbal epithelial stem cell transplantation can be done by either keratolimbal allograft (KLAL) obtained from cadaveric donor eye or by living related conjunctival limbal allograft (1rCLAL). The main drawback of such procedures is that it provides highly antigenic allogeneic limbal tissue rich in langerhans cells which are responsible for immune rejection of graft. Conjunctival limbal auto graft (CLAU) can be used in unilateral limbal stem cell deficiency but stem cell deficiency in the fellow eye is a major concern. These problems can be overcome by in vitro expansion of human limbal epithelial stem cells and transplantation to the affected eye. This restores the vision in such patient.

The main focus of this study was to identify limbal epithelial stem cells by a marker. This would enable isolation and growth of limbal epithelial stem cell very easy and will help in reconstruction of ocular surface in patients with limbal stem cell deficiency (LSCD). Limbal Stem cell deficiency is one of the major causes of corneal blindness. In the present scenario, there are various stem cell markers. The present study has been designed to recognize potential of p63 as stem cell marker.

### Aim of Study:

Aim of our study is "Identification of human limbal stem cell by P63, a specific stem cell marker in cadaveric limbal tissue and in in-vitro limbal stem culture".

## Material and Method

The present study was conducted in the Department of Ophthalmology, Institute of Medical Sciences, Banaras Hindu University, in collaboration with Centre for Genetic Disorder, Faculty of Science and Department of Pathology, Institute Of Medical Sciences, Banaras Hindu University.

Total 18 corneo-scleral rim samples were collected over a period of two years in which 5 were discarded due to infection. Limbal biopsy was obtained from corneo-scleral rim of cadaveric donor cornea remaining after penetrating keratoplasty. Corneoscleral rims of cadaveric donor cornea were divided into two parts. One part was used for immuno-histochemistry staining and the other part was used for in-vitro culture.

### Primary and immuno-histochemistry stains were used

- Haematoxylin and Eosin staining.
- Primary antibody: mouse anti p63 antibody.
- Secondary antibody: anti-mouse (GOAT) Fab fragment antibody
- DAB (3, 3'-diaminobenzidine tetrahydrochloride) chromogen.

### Culture carried out by use following material

- Human amniotic membrane (HAM).
- Human corneal epithelium medium with 10% fetal bovine serum
- 35 mm petri dish and 5% CO<sub>2</sub> incubator.
- Human corneal epithelium medium with 10% fetal bovine serum.
- Nikon inverted phase contrast microscope.

### Haematoxylin and Eosin (H & E) staining:

Segments of the rim were embedded in either optimum cuffing frozen in liquid nitrogen, fixed in formalin, and embedded in paraffin or fixed in glutaraldehyde and embedded in resin. The tissue blocks were then cut into serial 5-7

mm sections. These were stained with haematoxylin and eosin and those fixed in glutaraldehyde were stained with toluidine blue. Every section was examined by light microscopy using a Nikon microscope.

### Immunohistochemistry staining:

- Sections were stained with the panel of monoclonal antibodies
- Primary antibody: mouse anti p63 antibody.
- Secondary antibody: anti mouse (GOAT) Fab fragment antibody

### Procedure of Immunohistochemical staining:

Paraffin-embedded limbal sections were fixed with 10% neutral buffered formalin. Deparaffinization with xylene was done for 10 minutes followed by rehydration with alcohol (100%, 95%, 70%, 50%), 3 minutes each. Antigens were retrieved in microwave oven. Slides were kept in Citrate Buffer-working solution (Kept it in an oven). Under Power 450 for 5 times-3 minutes each at the same time buffer added. Then the slides were kept in room temperature for 30 minutes. Slides were washed with PBS (Phosphate buffered saline) for 3 times 3 minutes each. Wiped with tissue paper (peroxide block was added for 15 mm in moist chamber). Slides were again washed with PBS for 3 times 3 minutes each. Power block added and incubated for 15 minutes. Primary antibody P63 then added for 1 hour in moist chamber at room temperature or overnight incubation in refrigerator at 4-8°C. Washed with PBS for 3 times 3 minutes each, super enhancer added and incubated in moist chamber for 25 minutes, then washed with PBS for 3 times 3 minutes each. Secondary antibody (SS Label) added, incubated for 30 minutes then washed with PBS for 3 times 3 minutes each. Diaminobenzidine-tetrahydrochloride (DAB) chromogen was added for 30 seconds to 3 minutes (2 drops chromogen DAB+ 1 ml of DAB buffer). Washing done with distilled water for 5 minutes. Slides were dipped in Haematoxylin for 30 seconds, then in running tap water for 5 minutes. Slides were kept in 70% alcohol for 2 minutes in 80% alcohol for 2 minutes then in 100% alcohol for 2 minutes then in Xylene for

2minutes and lastly in Xylene for 1 minute. Mounted with DPX (Distrene, Plasticiser and Xylene). Then slides are ready for microscopic examination.

### Procedure of *In-vitro* culture

Human amniotic membrane measuring 4x3 mm was pre warmed at 37 degree Celsius with 5% CO<sub>2</sub> incubation on 35 mm peritridish. De-epithelialization of Amniotic membrane was done by use of 0.25%. Trypsin EDTA solution for 15 minutes and mechanically scraping with the help of two glass slides. Limbal tissues were washed in Ringer lactate solution containing 50µg/mL penicillin 50µg/ml gentamicin and 1.25µg/ml amphotericin-B, then limbal tissues were dissected out aseptically and was shredded into tiny bits and explanted in the center of membranes. The culture was nurtured using human corneal epithelium medium with 10% fetal bovine serum on alternate days. Growth was observed under inverted phase contrast microscope.

The human corneal epithelium medium was prepared using 9.7 g/L modified Eagle's Minimal Essential medium with addition of 16.2 g/L Ham F12 serum, 0.001 mg/L epidermal growth factor, 0.25 mg/L insulin, cholera toxin, 50µg/ml Gentamicin, benzyl penicillin 100 units/ml and 1.25 µg/ml amphotericin B and hydrocortisone. The sterile medium was supplanted with 10% fetal calf serum. Cultures were incubated at 37°C under 5% carbon dioxide and 95% air and the

medium was changed every 2-3 days while the extent of each outgrowth was monitored with a phase contrast microscope. The culture was nurtured upto 28 days.

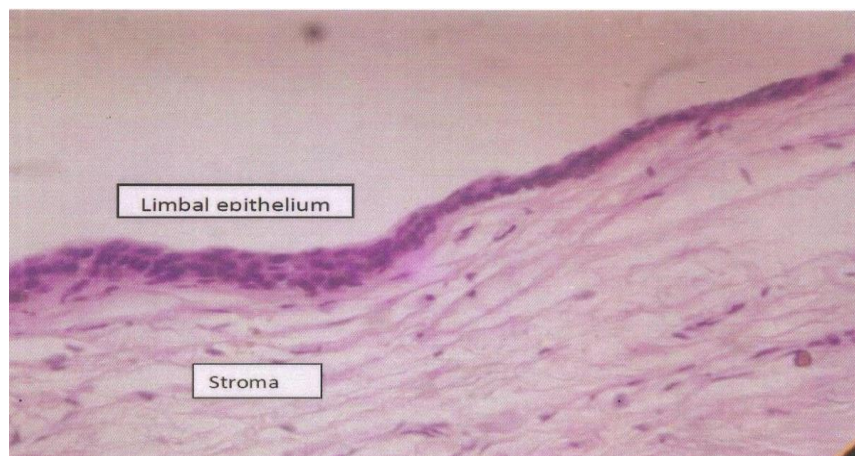
### Observation and Result

These corneoscleral rims were used for immuno-histochemistry staining and for limbal stem cell culture. Donor tissues were preserved in MK media for maximum up to 3 days. The time intervals between death and corneal tissue removal, corneal tissue removal to preservation, preservation to utilization or the total duration between death and utilization of the tissues did not make any difference in the growth potential and immuno-staining of preserved tissues.

**Staining:** In this study we first stained limbal tissue with haematoxylin and eosin followed by staining with primary antibody (mouse anti p63 antibody). This was followed by Secondary antibody (anti-mouse (GOAT) Fab fragment antibody) and finally DAB chromogen used.

### Haematoxylin and eosin staining

**(H&E):** Knowledge of histology of limbus is very important before immuno-histochemistry staining. Histology of limbus is easily understood by use of Haematoxylin and eosin staining.

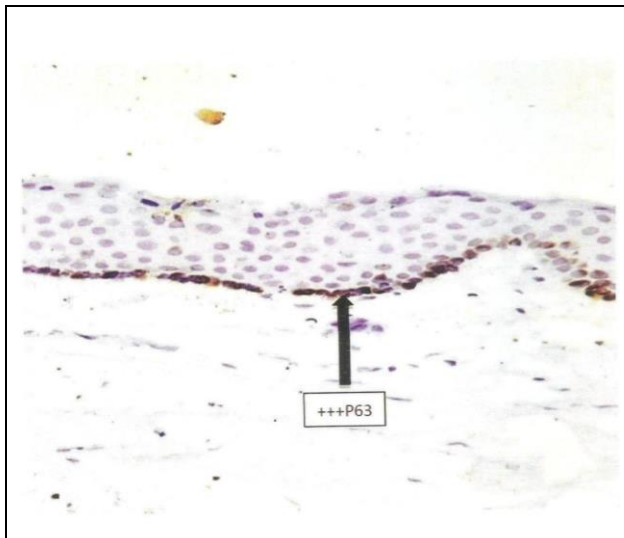


**Fig.-1:** Haematoxylin and eosin staining of human limbal epithelium showing stratified epithelium with stroma

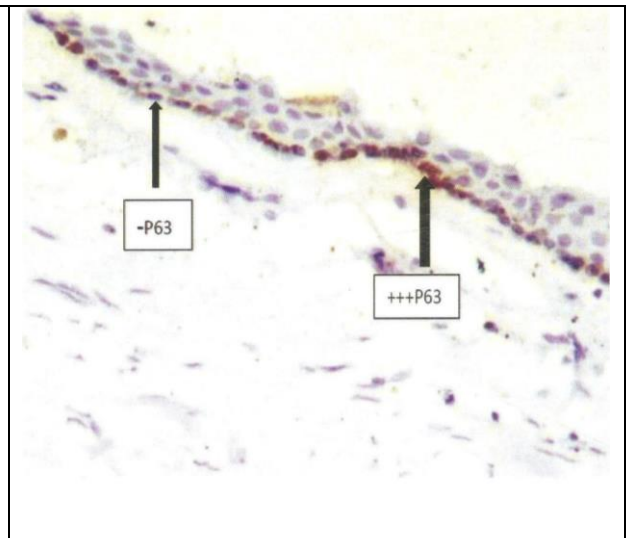
**Immunohistochemistry:**

After understanding histology of limbus, we stained cross sections slides of limbus with immunohistochemistry marker p63 to identify exact location of human limbal stem cells. In our study we got following immunohistochemistry pattern of limbal tissue.

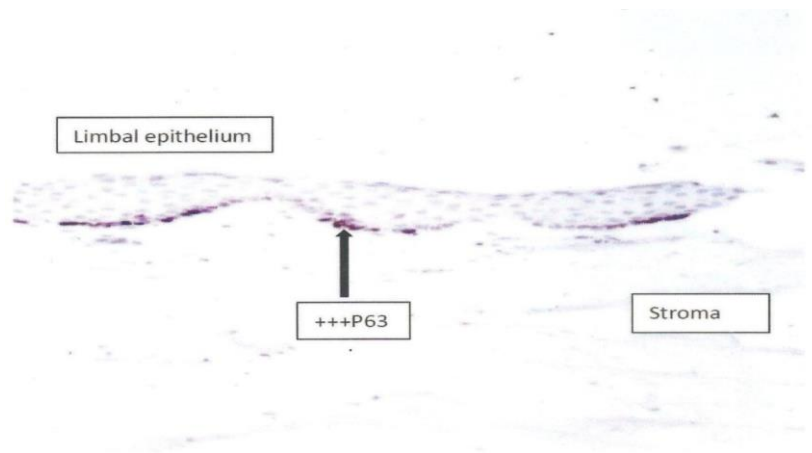
Basal layer of limbus shows intense staining for p63 (Fig.-2). Stained cells showed brown color (due to DAB chromogen). There was no uniform staining of basal layer. Some cells showed intense staining while other cells did not show stain. This indicates that limbal stem cells are not uniformly distributed in basal limbal layer but are present in small groups (Fig.-3). The intensity of staining decreases from limbus to peripheral cornea as seen in Fig.-4]. This indicates that stem cells are mainly present in basal layer of limbus.



**Fig.-2:** Under 40x magnification microscopy: Basal limbal layer showing strong positivity for p63



**Fig.-3:** Under 40x magnification microscopy: Basal layer of limbus shows positivity for p63, some cells show intense staining (p63+ve) while some cells are unstained (p63-ve).



**Fig.- 4:** Under 20x magnification Basal layer of limbus showing intense staining for p63.

Based on the intensity of immunohistochemistry staining of cells in culture and cadaveric tissues, we score the quality of the stained cells as follows

**Scoring of immunohistochemistry staining:**

-	Undetectable
+	Weak positivity
++	Moderate positivity
+++	Strong positivity

**Table- 1 :** Staining pattern of limbus and Peripheral corneal epithelium for p63

Samples	Limbal Epithelium		Peripheral epithelium	Corneal
	Supra basal	Basal	Supra basal	Basal
1	-	+++	-	-
2	+	+++	-	-
3	+	++	-	+
4	-	++	-	-
5	+	+++	-	+
6	-	++	-	+
	+	+++	-	-
8	-	++	-	+
9	-	++	-	-
10	-	+++	-	-
11	+	+++	-	-
12	-	+++	-	-
13	-	++	-	-

**Staining pattern of limbus and Peripheral corneal epithelium for p63 showed following results:**

For studying efficacy of p63 as an immunohistochemistry marker samples divided into two groups, limbal epithelium and peripheral cornea epithelium. Further Limbal epithelium divided into suprabasallimbal region and basal limbal region. Similarly peripheral corneal epithelium grouped into suprabasal and basal epithelium.

Suprabasal region of limbus showed 5 out of 13 samples weak positivity for p63. This indicates that suprabasal region

contains very less number of limbal epithelial stem cells (p63 positive) and more number of terminally differentiated. In all 13 samples, basal region of limbus showed strong positivity for p63. This indicates that basal region of limbus contains more number of limbal stem cells (p63 positive) and very less number of terminally differentiated epithelial cells.

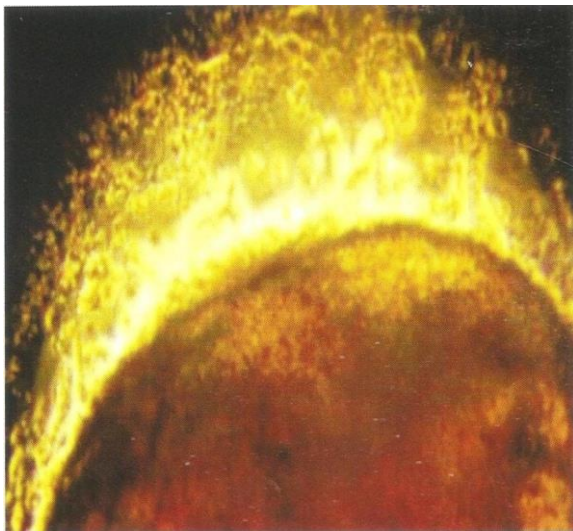
Suprabasal region of peripheral cornea showed negativity for p63 in all 13 samples. This indicates that suprabasal region of limbus contains more number of terminally differentiated epithelial cells which do not take p63 stain. Basal region of

peripheral cornea shows 4 out of 13 samples were weak positivity for p63. This indicates that basal region of peripheral cornea contains very less number of limbal stem cells (p63 positive).

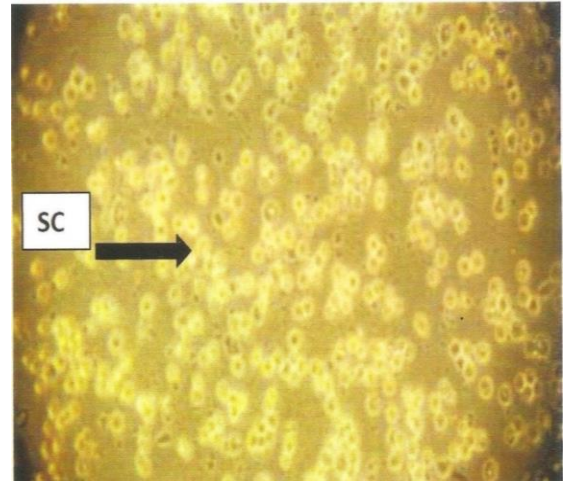
Thus basal layer of limbus is strongly positive for p63 in comparison with peripheral cornea. This indicates limbus is a storehouse of stem cells for corneal epithelium.

### ***In-vitro* culture on denuded amniotic membrane:**

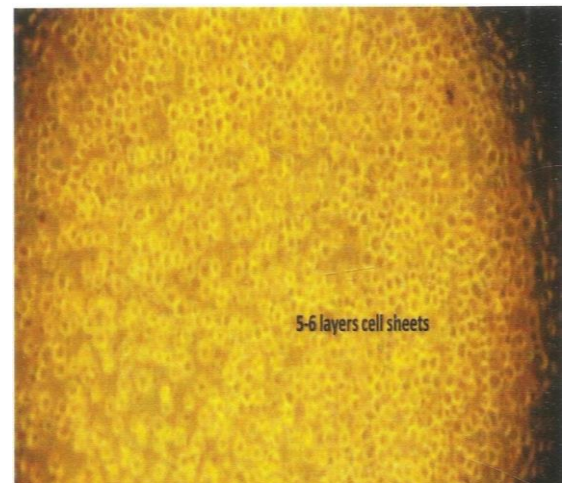
In this study, to know proliferative capacity of tissue biopsies to grow limbal stem cells, we carried out limbal stem cell proliferative assay under inverted phase contrast microscope. For this we had done three limbal stem cells cultures by use of limbal biopsies. Cellular outgrowth was observed under inverted phase contrast microscope after 5 days of incubation. Inspection of these cultures showed that growth of corneal explants on denuded amniotic membrane was considerably quicker. Also migration of human epithelial cells from the explants was more rapidly beginning on the second day of culture. p63 staining of cultured stem cells showed staining of cultured stem cells, which indicated that these were true stem cells and not differentiated stem cells.



**Day 1 showing limbal explant placed on denuded amniotic membrane.**



**Day 17 showing daughter stem cell (SC) on denuded amniotic membrane**



**Day 28 showing 5-6 layer of daughter stem cell on denuded amniotic membrane**

### **Discussion**

Limbal epithelial stem cells are responsible for renewal of corneal epithelium. In the light of the development of strategies for reconstruction of the ocular surface in patients with limbal stem cell deficiency, a major challenge in corneal stem cell (SC) biology remains the ability to identify stem cells in situ and in vitro. Until recently, the identification of limbal stem cells mainly has been based on general properties of stem cells, e.g. lack of differentiation, prolonged label-retaining, indefinite capacity of proliferation exemplified by the clonogenic assay as well as their special role in corneal wound

healing. During the last few years, a number of molecular markers for the limbal SC compartment have been proposed; however, their role in distinguishing limbal SC from their early progeny is still under debate.

We know human limbal stem cells are few in number and reside deeply in basal layer of limbus in small groups.[1,2] Thus identification of limbal stem cells is difficult job but it can be identified by use of immuno-histochemistry marker. Accordingly we planned study in search of efficient immunohistochemistry marker for identification of limbal stem cells. P63 transcription factor and ATP binding cassette transporter G2 (ABCG2) are considered to be most reliable markers for stem and transient amplifying cells (TACs).[3]

The p63 transcription factor belongs to a family that includes two structurally related proteins, p53 and p73. Whereas p53 plays a well-established role in tumor suppression, p63 and p73 play unique roles in morphogenesis. P63 the first gene product, definitely distinguishing stem cells from their TA progeny in stratified squamous epithelia.[4,5] Pellegrini et al 2001 showed that within the cornea, nuclear p63 is specifically expressed by the basal cell of the limbal epithelium, but not by Transient Amplifying (TA) cells covering the corneal surface.<sup>6</sup> TA keratinocytes, immediately after their withdrawal from the stem cell compartment (meroclones), have greatly reduced p63, even though they possess very appreciable proliferative capacity. Cytoskeleton consists of eukaryotic cell consists of at least three types of filaments, which are microtubules, microfilaments and intermediate filaments. Here are five subclasses of intermediate filaments, of which Cytokeratins (CK) is the one type. Cytokeratins can be further divided into acidic (type I) and basic (type II) and are immuno reactive so can be identified by immuno-histochemistry. In 1986, Schirmer and associates showed

presence of cytokeratin CK3 and Cytokeratin CK12 in suprabasallimbal cell layers and throughout the entire thickness of corneal epithelium.<sup>7</sup>

Pellegrini et al., 2001 showed in-vitro holoclones contained high levels of p63, whereas paraclones did not contain detectable p63 as determined by Western blotting. It was also noted that most cells expressing p63 in the limbal basal layer also expressed proliferating cell nuclear antigen (PCNA), a specific marker of proliferating cells. However, some PCNA-expressing cells did not produce p63 and these cells were often located next to p63-positive cells. In addition, cells expressing high levels of p63 did not often express PCNA. These observations led the authors to suggest that p63 is expressed by basal epithelial cells that have the ability to proliferate, and to propose that p63 is a nuclear marker for corneal epithelial SC.[8]

In 2003, Dua showed positive staining of p63 was observed not only in the limbal region but also among most of the basal cells of the peripheral and central corneal epithelium in both frozen and formalin-fixed specimens.[9] In 2004, Wang and Hsueh were found p63-positive signals specifically in basal and suprabasal cells of the limbal epithelium in rabbit eyes, whereas the corneal epithelium was negative.[10] Similar results we found in our study; p63 is consistently positive in basal layer of limbus suggesting that limbus contains stem cell population. In comparison with peripheral basal cell population, limbus contains more strong positivity for p63 immuno-histochemistry stain indicating that limbus is source of stem cells.

In 2004, DG Harkin performed a study on analysis of p63 and cytokeratin expression in a cultivated limbal auto graft used in the treatment of limbal stem cell deficiency. They found that cultures grown on amniotic membrane displayed positive staining for keratins 14 and 19, and p63, but poor staining for keratin 3 (K3) and also document for the first time the co-expression



of cytokeratins 14 and 19 with p63 in a cultivated limbal graft.[11]

Mariappan et al. in 2010 showed that amniotic membrane is an ideal substrate that preferentially expands the outgrowth of limbal stem cells. Study by Grueterich et al. 2002 showed that limbal epithelial cells expanded on intact HAM while retaining their limbal phenotype and allowing little differentiation of the limbal cells to cornea phenotype. These limbal stem cells were shown to exhibit markers like ABCG2 and p63.[12]

Grueterich et al. in 2002 showed the ability of intact HAM to preserve and preferentially expand limbal stem cells. However other study by Li et al. 2006 showed that ex vivo expansion on intact HAM preserves the limbal epithelial phenotype, whereas that on denuded HAM promotes a corneal epithelial phenotype. [13] Other authors such as Koizumi et al. (Koizumi et al. 2006)[14] successfully cultivated well-stratified and differentiated LSCs on denuded HAM, while on the intact HAM limbal cells failed to stratify and in places formed only a monolayer of cells.. The limbal cells cultivated on denuded HAM shows superior attachment to the HAM stroma and also they were morphologically superior to the limbal epithelium on intact HAM. Baharvand et al. (2007) showed that epithelium-denuded HAM provides a superior niche for Limbal Stem Cell proliferation and phenotype maintenance in vitro.[15]

In our study growth of Human limbal epithelial stem cells on denuded amniotic membrane was significantly faster. The outwardly migrating limbal epithelial cells on denuded amniotic membrane revealed a smooth, uniform leading edge. Positive staining of these

newly cultured cells with p63 shows their stem cell nature and not differentiated cells. We demonstrated in our study that stem cells are not distributed uniformly but are present in clusters along the basal epithelium. Few stem cells were also found in basal layer of corneal epithelium using p63 staining.

### **Conclusion**

P63 maximally expressed in limbal basal layer and is a definitive marker for identification of limbal epithelial stem cell. Stem cells are responsible for renewal of corneal epithelium resides in the basal layer of limbus. Denuded amniotic membrane is a good substrate for growth of Human limbal epithelial cells which provide microenvironment for limbal stem cells. After culture in HAM, these cells retain good stem cell characteristics and well stained with ideal stem cell markers like p63.

Rapid advancement in the successful clinical application of in vitro expanded limbal epithelial cells anticipates our knowledge on Stem Cell biology. However, the success of the clinical approaches could be further advanced as we increase our understanding of the molecular characteristics of SC and their in vivo environment. What is needed is a better understanding of the internal and external signals that determine the SC phenotype or induce differentiation as well as of the degree of plasticity of adult.

### **References**

1. Townsend WM. The limbal palisades of Vogt. *Trans Am Ophthalmol Soc* 1991; 89:721-56.
2. Wei L, Hayashida Y, Chen YT, Tseng SC. Niche regulation of cornea! Epithelial stem cells at the limbus. *Cell Res.* 2007;17 : 26-36.
3. Lohrum MA, Vousden KH. Regulation and function of the p53-related proteins: same family, different rules. *Trends cell Biol* 2000; 10:197-202.

4. Yang A, Kaghad M, Wang Y, et al. p63, a p53 homolog at 3q27-29, encodes multiple products with transactivating, death-inducing, and dominant-negative activities. *Mol Cell* 1998 ; 2 : 305-16.
5. Chee KY, Kicic A, Wiffen SJ. Limbal stem cells: the search for a marker. *Clin Experiment Ophthalmol* 2006; 34: 64- 73.
6. Rama P, Bonini 5, Lambiase A, Golisano O, Paterna P, De Luca M, Pellegrini G. Autologous fibrin-cultured limbal stem cells permanently restore the corneal surface of patients with total limbal stem cell deficiency. *Transplantation* 2001;15: 1478-85.
7. Schermer A, Galvin S, Sun TT .Differentiation-related expression of a major 64 K corneal keratin in vivo and in culture suggests limbal location of corneal epithelial stem cells. *J Cell Biol* 1986; 103:49-62.
8. C. Pellegrini, E. Dellambra, O. Golisano, E. Martinelli, I. Fantozzi, S. Bondanza, D. Ponzin, F. McKeon, M. de Uuca. p63 identifies keratinocyte stem cells; *Proc. Natl. Acad. Sci. USA*, 98 (2001), pp. 3156-3161.
9. H.S. Dua, A. Joseph, V.A. Shanmuganathan, R.E. Jones. Stem cell differentiation and the effects of deficiency ; *Eye*, 17 (2003), pp. 877-885.
10. YJ Hsueh D.Y. Wang C. C. Cheng, J. K Chen. Age-related expressions of p63 and other keratinocyte stem cell markers in rat cornea; *J. Biomed. Sci.*, 11 (2004), pp. 641-651.
11. D C Harkin, Z Barnard, P Gillies, S U Ainscough, AJG Apel. Analysis of p63 and cytokeratin expression in a cultivated limbal autograft used in the treatment of limbal stem cell deficiency; *Br J Ophthalmol* 2004;88:1154-1158.
12. Mariappan I, Maddileti S et al. *In vitro* culture and expansion of human limbal epithelial cells. *Nat Protoc* 2010; 5: 1470–1479.
13. Grueterich M, Tseng SC. Human limbal progenitor cells expanded on intact amniotic membrane ex vivo. *Arch Ophthalmol*, 2002; 120:783–790.
14. Koizumi N, Rigby H et al. Comparison of intact and denuded amniotic membrane as a substrate for cell-suspension culture of human limbal epithelial cells. *Graefes Arch Clin Exp Ophthalmol* 2007; 245(1):123–134 [Epub 2006 Apr 13].
15. Baharvand H, Heidari M et al. Proteomic analysis of epithelium-denuded human amniotic membrane as a limbal stem cell niche. *Mol Vis* 2007; 13:1711–1721.

