

## Wound healing activity of topical formulation of *Lantana camara* Linn flower water distillate in Wistar rats

Satyajit Samal<sup>1,\*</sup>, Bhabagrahi Rath<sup>2</sup>, Swagatika Pradhan<sup>3</sup>, Smaranika Pattnaik<sup>4</sup>

<sup>1</sup>Assistant Professor, <sup>2</sup>Associate Professor, Dept. of Pharmacology, VSS Institute of Medical Sciences & Research, Burla, <sup>3</sup>Ph. D Scholar, <sup>4</sup>Assistant Professor, Laboratory of Medical Microbiology, School of Life Sciences, Sambalpur University, Sambalpur

**\*Corresponding Author:**

Email: dr\_satyajitsamal@yahoo.com

### Abstract

**Objective:** To evaluate the wound healing effect of topical formulation of *Lantana camara* Linn flower water distillate in Wistar rats.

**Materials and Methods:** The water distillate of *Lantana camara* Linn flowers were made into oil based pro-formulation and tested for the 'wound healing' activity on excision and incision wound models in albino rats of Wistar strain. Animals were divided into four groups, containing 6 animals each. Group I (control) received no treatment. Group II animals were treated with 5% w/w Povidone iodine (positive control). Group III & Group IV treated with 5% & 10% ointment prepared from *Lantana* essential oil. The process of wound healing was observed with naked eye till complete healing of wounds, substantiated with histopathological studies. The wound healing parameters like rate of wound contraction and period of epithelialization were observed for excision model, whereas tensile strength (skin breaking strength) was observed in the incision model. Results were analyzed by using One-way ANOVA followed by Tukey's multiple comparison test.

**Results:** The degree of contraction of wound, period of epithelialization as well as tensile strength in incision model for different groups were compared and correlated. The test drug showed significant pro-wound healing potential in terms of all the parameters studied as compared to control and standard drug. The histopathological findings also correlated with the observed wound healing.

**Conclusion:** *Lantana* oil formulation can be better alternative of Povidone iodine, which has some delayed wound healing action. Further research in terms of long term dermal toxicity and determination of active principle of the extract is warranted.

**Keywords:** Epithelialization, Excision wound, Incision wound, Tensile strength, Wound contraction.

### Introduction

Wound infections are one of the most common hospital acquired infections and are an important cause of morbidity and account for 70-80% mortality.<sup>(1,2)</sup> A wound provides a moist, warm, nutritive environment conducive to microbial colonization and proliferation.<sup>(3)</sup> Wound healing is a dynamic self-recovery body mechanism, which involves a series of events like clotting, inflammation, granulation tissue formation, re-epithelialization, collagen synthesis and wound contraction.<sup>(4)</sup> Healing of a clean uninfected surgical incision closed by surgical sutures, is referred to as healing by primary union or by first intention. Re-epithelialization to close the wound occurs with formation of a relatively thin scar.<sup>(4)</sup> In case of excision wounds, large defects on skin is created causing extensive loss of tissue. The healing of these wounds occurs by secondary union or by second intention, which involves a more intense inflammatory reaction with formation of abundant granulation tissue and extensive collagen deposition, leading to the formation of a substantial scar, which generally contracts.<sup>(4)</sup>

Reducing the risk of infection through effective management of wound bio-burden is thus an essential aspect of wound care.<sup>(5)</sup> Herbal products may be considered due to their decolonizing activity against a number of microbes. Soni *et al* had reviewed the herbal active constituents (tannins and flavonoids) as regards

their wound healing activity.<sup>(6)</sup> From time immemorial, it was well documented that weeds were the favourite alternative herbal medicaments for the mankind. Weeds produce secondary metabolites to protect themselves or produce allelopathic chemicals to inhibit growth of other plants.<sup>(7)</sup> *Lantana camara* is a significant weed comprising an array of active metabolites like alcohols, alkaloids, terpenes and terpenoids.<sup>(8)</sup> Several authors have reported antibacterial efficacy of *Lantana camara*, but no study had been carried out about its wound healing potential. Moreover, the *Lantana* weed extract used in this study was sourced from the local area which may be different from other reported varieties because of a geographical impact on variation of synthesis of active constituents due to disparity in genetic architecture of plants. In this background, this work was conducted to screen the wound healing activity of *Lantana camara* flower water distillate on rat models.

### Materials and Methods

**Experimental Animals:** The study was conducted during December 2016 and February 2017 in Department of Pharmacology, VIMSAR, Burla in collaboration with Department of Life Sciences, Sambalpur University. The experimental protocol was approved by the Institutional Animal Ethics Committee, VIMSAR, Burla bearing registration number

553/GO/Re/s/02/CPCSEA. Animal care was carried out as per CPCSEA guidelines. A total number of 48 adult Wistar rats of either sex weighing between 150-200gm were used in the study. During the whole period of experiment, they were kept in separate polypropylene cages with normal laboratory diet and water ad libitum.

**Plant Material Collection and Extraction:** The flowers of *Lantana* plants [TSN 32125 (ITIS database, www.itis.gov)] were plucked in morning hour from the flowering twigs growing in Sambalpur University campus (21.48°N, 83.88°E), Sambalpur, India. The flowers were cleaned and subjected to water distilled by using Clevenger Apparatus (Clevenger, 1928), which conducts the distillation process by boiling, condensing and decantation to separate the oil.<sup>(9)</sup>

**Formulation of drug:** The *Lantana* oil based ointment was prepared by using the method of Phase inversion temperature (Emulsification) method with slight modification.<sup>(10)</sup> The ingredients (5% wool fat, 5% hard paraffin, 5%  $\beta$  sitosterol alcohol, 85% white soft paraffin) were mixed and heated (60-65°C) in a beaker and the mixture was stirred by using a glass rod with a constant rotation for proper emulsification. Further the system was allowed to come down to 40°C temperature resulting in white colored soft emulsion. Then the *Lantana* water distillate was mixed (maintaining 5% and 10% strength) with the emulsion with constant stirring till the formation of a uniform emulsion.

**Drugs and Chemicals:** 5% w/w Povidone iodine ointment (Betadine) was used as standard drug. Sterilized surgical scalpel, ether and stitching materials were also used in this study. All were purchased locally.

**Grouping and Drug Treatment:** For each wound model, the animals were divided into four groups (containing 6 animals each) as follows:

- Group I: Control group, received no treatment.
- Group II: Treated with 5% w/w Povidone iodine ointment (Reference standard drug).
- Group III: Treated with 5% w/w ointment prepared from *Lantana* essential oil.
- Group IV: Treated with 10% w/w ointment prepared from *Lantana* essential oil.

#### *Infliction of wounds*

Two methods namely; (a) Excision wound method and (b) Incision wound method were used in this study.

#### *(a) Wound Healing study by using 'Excision Wound' Method*

Method described by Morton and Malone was used for Excision wound model.<sup>(11)</sup> Prior to skin excision, particular skin area was shaved. Wounds were made by excising the full thickness circular skin (approx. 200 mm<sup>2</sup>) from the nape of the neck under ether anesthesia and wounds were left undressed to the open environment. The rats were grouped and kept individually in separate cages. Group I received no treatment and considered as the control. Group II received 5% w/w Povidone iodine. Group III & Group

IV received 5% & 10% ointment prepared from *Lantana* essential oil respectively. Treatment was continued till complete closure of wound. The "Wound closure" was assessed by tracing the wound on polythene paper on wounding day, followed by 4th, 8th, 12th, 14th day and subsequently on every alternate day till complete closure of wounds. Falling of the scab without any raw area was taken as to calculate the time span for the complete epithelialization.<sup>(12)</sup> Wound contraction was expressed as the percentage of the original wound size.

The percentage wound contraction was determined using the following formula:

$$\% \text{ Wound contraction} = (\text{Initial wound area} - \text{Unhealed wound Area}) / \text{Initial wound area} \times 100.$$

Morphology of scars was also observed. The round-oval and larger scars were considered as indicator of poor contraction while stellate shaped or linear scars were indicative of enhanced wound contraction.<sup>(13)</sup> One rat in each group was randomly selected and circular scar of 100 mm<sup>2</sup> was excised from each rat for histopathological study.

**Histopathological study:** For histological studies, skin tissues were fixed in 10% neutral formalin solution for 24 hours and dehydrated with a sequence of ethanol-xylene series of solutions. The materials were then filtered and embedded with paraffin (40-60°C). Microtome sections were taken at 10 $\mu$  thickness. The sections were processed in alcohol-xylene series and stained with hematoxylin-eosin dye. The histological changes were observed under a microscope.<sup>(14)</sup>

#### *(b) Wound Healing study by using 'Incision Wound' Method:*

The wounds for 'Incision method' were made by using modified method of Ehrlich et al.<sup>(15,16)</sup> For this purpose particular skin area was shaved. Two numbers of long paravertebral parallel incisions of six centimetres, one centimetre away (laterally) from the vertebral column was made under mild ether anesthesia. Then the wounds were sealed with sutures made up of non-absorbable sterilized silk suture (size 1). The rats were grouped and kept individually in separate cages. Each group was applied with respective ointments up to 10 post-wounding days. Sutures were removed on 8th day. On 11th day post wounding, the animals were anaesthetized under light ether anesthesia. Breaking tensile strength was measured by continuous water flow technique with a tensiometer designed in our laboratory.<sup>(15)</sup> Two readings were taken from two wounds and the mean was calculated. The wounds are then resutured, treated by topical ointments and animals were kept under observation.

**Statistical analysis:** Data were analyzed by using Graph Pad Prism Software Version 1.0. All values were expressed as mean  $\pm$  standard error of mean (SEM). The statistical significance was assessed using one-way analysis of variance (ANOVA) followed by Tukey's multiple comparison test. Difference was considered statistically significant when  $P < 0.05$ .

## Results

**Excision wound model:** As seen from Table 1, the mean percentages of wound contraction in Group III (5 % *Lantana camara* ointment treated rats) are  $6.76 \pm 0.14$ ,  $29.89 \pm 0.91$ ,  $43.88 \pm 0.86$  &  $86.47 \pm 1.37$  on 4<sup>th</sup>, 8<sup>th</sup>, 12<sup>th</sup> and 16<sup>th</sup> days of observation respectively, which were significantly higher than both Group I (control group) and Group II (Povidone iodine) treated group. In Group IV (10 % *Lantana camara* ointment treated rats), the mean percentages of wound contraction are  $8.13 \pm 0.17$ ,  $35.18 \pm 0.86$ ,  $54.46 \pm 0.91$  and  $98.67 \pm 0.66$  on 4<sup>th</sup>, 12<sup>th</sup>, 8<sup>th</sup> and 16<sup>th</sup> days of observation respectively. These were also significantly higher than both Group I and Group II. The mean time for epithelialization in Gr I, II, III & IV were  $20.17 \pm 0.3$ ,  $22.33 \pm 0.21$ ,  $19.83 \pm 0.3$ ,  $17.67 \pm 0.21$  respectively. These decreases observed in both *Lantana* oil treated groups in comparison to control and

Povidone iodine treated group are statistically significant. Fig. 1 displays wound contraction in animals in Group I, II, III & IV on 0, 4, 8, 16 and 20 day of observation. Fig. 2 displays the histopathological sections of newly formed skin scar after complete epithelialization in Group I, II, III & IV. As evident from histopathological study, the *Lantana camara* ointment treated groups showed hyperkeratosis, with increased granulation tissues, lymphocytes and few plasma cells at the dermo-epidermal junction and in the superficial dermis along with plenty of normal appearing dermal appendages.

**Incision wound model:** As seen from Table 2, *Lantana camara* ointment treated rats in both the groups showed significantly increased wound breaking strength ( $184.7 \pm 2.45$ ,  $196.3 \pm 2.33$  g/cm) when compared to that of the control ( $166.5 \pm 3.7$  g/cm) & Povidone iodine ( $164.7 \pm 2.71$  g/cm).

**Table 1: Effect of drugs on percentage of wound contraction and epithelialization period on excision wound in rats**

Group	Percentage of wound contraction on different days				Mean epithelialization time in days
	4th day	8th day	12th day	16th day	
Control	$5.32 \pm 0.17$	$20.08 \pm 0.58$	$37.61 \pm 0.88$	$68.39 \pm 1.12$	$21.67 \pm 0.5$
Povidone iodine 5% w/w	$5.05 \pm 0.14$	$17.53 \pm 0.81$	$34.50 \pm 0.88$	$65.17 \pm 2.22$	$22.33 \pm 0.21$
<i>Lantana camara</i> ointment 5% w/w	$6.76 \pm 0.14^{***/###}$	$29.89 \pm 0.91^{***/###}$	$43.88 \pm 0.86^{***/###}$	$86.47 \pm 1.37^{***/###}$	$19.83 \pm 0.3^{**/###}$
<i>Lantana camara</i> ointment 10% w/w	$8.13 \pm 0.17^{***/###}$	$35.18 \pm 0.86^{***/###}$	$54.46 \pm 0.91^{***/###}$	$98.67 \pm 0.66^{***/###}$	$17.67 \pm 0.2^{***/###}$

The values are expressed as Mean  $\pm$  SEM, n=6 in each group.

\*P<0.05, \*\*P<0.01 and \*\*\*P<0.001 vs. Control

# P<0.05, ## P<0.01, ### P<0.001 Vs Povidone iodine

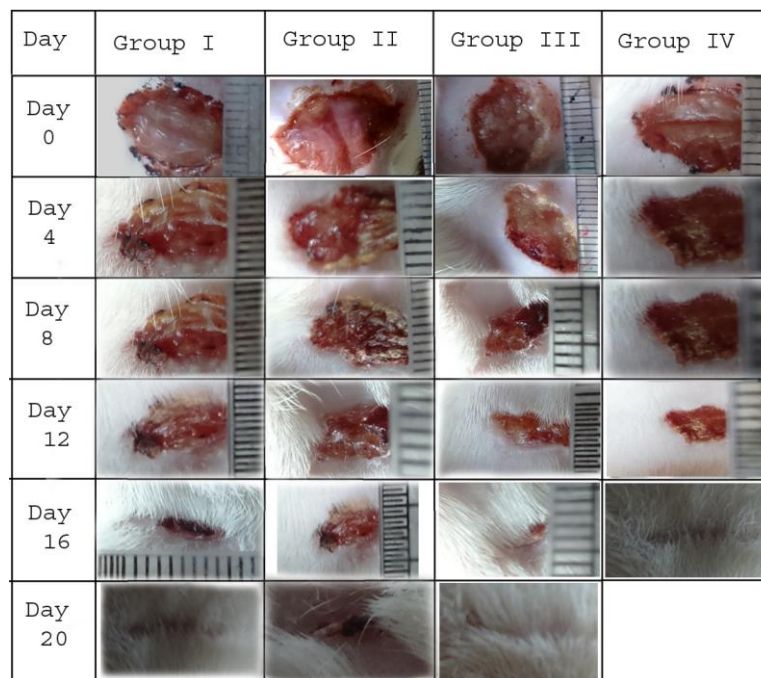
**Table 2: Effect of drugs on 'Tensile breaking strength' on incision wound in rats**

Tensile breaking strength (g/cm)			
Control	Povidone iodine 5% w/w	<i>Lantana camara</i> ointment 5% w/w	<i>Lantana camara</i> ointment 10% w/w
$166.5 \pm 3.7$	$164.7 \pm 2.72$	$184.7 \pm 2.46^{**/###}$	$196.3 \pm 2.33^{***/###}$

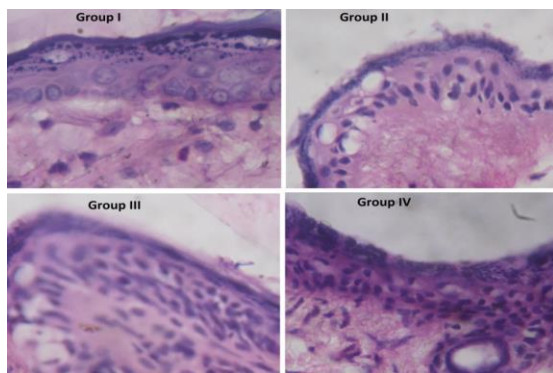
The values are expressed as Mean  $\pm$  SEM, n=6 in each group.

\*P<0.05, \*\*P<0.01 and \*\*\*P<0.001 vs. Control

# P<0.05, ## P<0.01, ### P<0.001 Vs Povidone iodine



**Fig. 1: Effect of *Lantana camara* Linn flower water distillate on excision wound in rats**



**Fig. 2: Histopathological examination of healed skin of excision wound of rat of Group I, II, III & IV (100×)**

## Discussion

In this study, the *Lantana camara* flower water distillate showed significant wound healing activity in both excision and incision wound models as evidenced by increased wound contraction percentage, decreased mean epithelialization period and increased tensile breaking strength. The wound healing process consists of a sequence of events like formation of blood clots, granulation tissue, cell proliferation, collagen deposition, collagen maturation and scar maturation. In a clean, uninfected surgical incision approximated by surgical sutures, healing is by primary union. Re-epithelialization to close the wound occurs with formation of a relatively thin scar. Excision model wounds create large defects on the skin surface, healing involves a more intense inflammatory reaction with formation of abundant granulation tissue, extensive collagen deposition followed by wound contraction.

The recovery of tensile strength results from the excess of collagen synthesis over collagen degradation during initial period of healing.

In the present study, two different wound models were used to determine the healing actions of oil based formulation of *Lantana camara* Linn flower water distillate. In the incision wound model, a significant increase in the skin tensile strength of *Lantana* oil treated group was observed, at both (5% and 10%) proformulations. In studies using the excision wound model, animals treated with *Lantana* oil showed a significant increase in wound contraction with decrease in epithelialization time as compared to control (Untreated) and Povidone iodine treated groups. The histopathological images of this study were also demonstrating increase formation of granulation tissues participating in healing of wounds.

Therefore, *Lantana* oil can be a better alternative than Povidone Iodine ointment, an antiseptic agent, which according to some literatures may have some delayed wound healing action due to cytotoxic action.<sup>(17)</sup> So there is always a need for alternate agents having both antibacterial as well as activity as well as wound healing activity. *Lantana* oil possess both these actions. Besides, the antiseptic agent should have least cytotoxic activity. Again *Lantana* flower water distillate-pro formulation can be considered a safe drug because of its natural source.

So topical formulation of *Lantana camara* Linn flower water distillate demonstrated significant wound healing effect in rats. This may be due to its both antibacterial properties along with promotion of collagen synthesis. However, phytochemical studies are required to isolate the active compounds responsible for this

activity. Further research regarding its antibacterial effect, effects on collagen synthesis, dermal toxicity, acute and subacute toxicity studies in animal models are needed before suitable trial in human wounds.

## References

1. Gottrup F, Melling A, Hollander D. An overview of surgical site infections: aetiology, incidence and risk factors. *E.W.M.A. Journal*, 2005,5(2):11-15.
2. Wilson APR, Gibbons C, Reeves BC, Hodgson B, Liu M, Plummer D *et al.* Surgical wound infections as a performance indicator: agreement of common definitions of wound infections in 4773 Patients. *B.M.J.*, 2004,329:720-722.
3. Bowler PG, Duerden BI, Armstrong DG. Wound Microbiology and Associated Approaches to Wound Management. *Clin Microbiol Rev*, 2001, Apr,14(2):244-269.
4. Kumar V, Abbas AK, Nelson F, Aster JC, James AP. Tissue renewal, regeneration and repair. In: Robbins and Cotran, editor. *Pathologic Basic of Disease*, 8<sup>th</sup> ed. Philadelphia: Elsevier Saunders, 2010:79-110.
5. Butcher M. PHMB: an effective antimicrobial in wound bioburden management. *Br J Nurs*, 2012, Jun 28-Jul 11;21(12):16-21.
6. Soni H, Singhai AK. A recent update of botanicals for wound healing activities. *Int Res J Pharm*, 2012,3(7):1-7.
7. Cheng F, Cheng Z. Research Progress on the use of Plant Allelopathy in Agriculture and the Physiological and Ecological Mechanisms of Allelopathy. *Front Plant Sci.*, 2015,6:1020.
8. Jain S, Itoria P, Joshi A, Dubey BK. Pharmacognostic and phytochemical evaluation and antipyretic activity of leaves of *lantana camara linn.* *International Journal of Biomedical and Advance Research IJBAR*, 2011,02:270-280.
9. Clevenger JF. Apparatus for the determination of volatile oil. *American Pharmaceutical Association*, 1928, Apr:17(7):345-349.
10. Forster T, Schambil F, Tesmann H. Emulsification by the phase inversion temperature method: the role of self-bodying agents and the influence of oil polarity. *Int J Cosmet Sci*, 1990, Oct,12(5):217-227.
11. Morton JJ, Malone MH. Evaluation of vulnerary activity by an open wound procedure in rats. *Archives Internationals de Pharmacodynamie et de Therapie*, 1972,196(1):117-126.
12. Pastar I, Stojadinovic O, Yin NC, Ramirez H, Nusbaum AG, Sawaya A *et al.* Epithelialization in Wound Healing: A Comprehensive Review. *Adv Wound Care (New Rochelle)*, 2014, Jul 3(7):445-464.
13. Sharpe JR, Martin Y. Strategies Demonstrating Efficacy in Reducing Wound Contraction *In Vivo*. *Adv Wound Care (New Rochelle)*, 2013,2(4):167-175.
14. Histopathology techniques and routine staining. In: Harsh Mohan, editor. *Pathology practical book*, 2<sup>nd</sup> ed. New Delhi: Jaypee brothers, 2007:6-10.
15. Ehrlich HP, Hunt TK. The effect of Cortisone and Anabolic Steroids on the tensile strength of healing wound. *Ann Surg*, 1969,170(2):203.
16. Khan AM, Saxena A, Fatima FT, Sharma G, Goud V, Husain A. Study of wound healing activity of *Delonix regia* flowers in experimental animal models. *Am. J. Pharm Tech Res*, 2012,2(2):381-390.
17. Kramer SA. Effect of povidone-iodine on wound healing: a review. *J Vasc Nurs*, 1999, Mar;17(1):17-23.