

## Significance of van herick test and its comparison with gonioscopy grading

Anil Kumar Srivastava<sup>1,\*</sup>, Vivek Kumar Gupta<sup>2</sup>, Ratendra Kumar Misra<sup>3</sup>

<sup>1</sup>Assistant Professor, <sup>2</sup>Senior Resident, <sup>3</sup>Professor, Dept. of Ophthalmology, Hind Institute of Medical Sciences, Ataria, Sitapur

**\*Corresponding Author:**

Email: asrivastavalko@rediffmail.com

### Abstract

Van Herick test is done to assess the occludability of anterior chamber angle by estimating peripheral anterior chamber depth in fraction of corneal thickness during a routine slit lamp examination. This method is also relevant in diagnosing very shallow anterior chambers, and concurrent risk of angle closure glaucoma and where dilatation of pupils may be relatively risky by resulting in precipitation of acute congestive glaucoma attack. In this study on 222 eyes of patients attending glaucoma clinic in ophthalmology department of a medical college in a district of North India, Van Herick test was performed and was followed by gonioscopy and the grading of both tests compared for occludability of anterior chamber angle. In our study the Van Herick method for estimation of peripheral anterior chamber depth very closely coincided with Gonioscopy findings and was found very useful method for quick and easy evaluations of eyes with narrow angle. However, gonioscopy must not be avoided for final assessment and management of patients.

**Keywords:** Angle Closure Glaucoma; Corneal Thickness (CT); Gonioscopic Grading; Peripheral Anterior Chamber Depth (PACD); Occludability of Angle; Van Herick Test.

### Introduction

The Van Herick test,<sup>(1)</sup> which allows a quick and easy assessment of anterior chamber angle during basic slit lamp examination, does not require any additional aid, and does not cause any discomfort to the patient. From this technique one can infer a nearly accurate assessment for occludable angles for diagnosis of Primary Angle Closure Glaucoma. This method is also significantly important in deciding safety of mydriasis in routine ophthalmic examination or before its therapeutic use in conditions such as infectious keratitis and iridocyclitis.

All of us routinely examine anterior segment by flashlight (Torch Light). By directing the torchlight from temporal side at the level of pupil, we see that whole of the iris is illuminated in normal or deep anterior chamber, but only temporal iris is illuminated and nasal iris is darkened in shallow anterior chamber. The gold standard method for assessing angle is Gonioscopy.<sup>(2,3)</sup> But this technique of gonioscopy is not easy to master, is based on subjective assessment and shows some amount of inter observer variability.

Van Herick method being quick and noncontact method, various authors have commented on its sensitivity and specificity for identifying narrow and occludable angles with contrasting views.<sup>(3-7,9,10)</sup> Several authors have also compared its results with gonioscopy and anterior segment OCT (Optical Coherence Tomography).<sup>(7)</sup> In this study we have evaluated usefulness of Van Herick technique for diagnosing and ruling out narrow (occludable) angle

during routine ophthalmic examination by comparing its results with gonioscopy in a part of northern India.

### Materials & Methods

Van Herick test was performed by projecting a narrow slit beam of light on the peripheral cornea as near as possible to the limbus at angle of 60 degrees, resulting in formation of a slit image on the cornea. The width of this illuminated corneal slit is used as reference (Corneal Thickness = CT). After traveling through the cornea the slit beam falls on iris. Now the width of peripheral anterior chamber can be judged by the distance (space) between corneal and iris slit in fraction of corneal thickness.

In Van Herick Grade 0, 1 or 2 when peripheral AC depth was less than  $\frac{1}{4}$ , or  $\frac{1}{4}$ , or less than  $\frac{1}{2}$  Corneal Thickness, the angle closure was very likely or possible, but when it was more than  $\frac{1}{2}$  or 1 CT, it was considered unlikely to develop angle closure (Table 1). During gonioscopy if posterior  $\frac{2}{3}$  of trabecular meshwork or more was visible, then angle was considered non-occludable (Table 2 Shaffer Classification).

A total of 222 eyes of 111 patients were examined, above age of 40 years, both sex, who were attending glaucoma clinic. Patients with any ocular surgery, trauma or ocular inflammation were excluded. Van Herick assessment of peripheral anterior chamber was done using halogen slit lamp as described above. Subsequently gonioscopy by 3 Mirror Goldmann Gonioscope was performed using Shaffer Classification by the same observer.

**Table 1: Grading According to Van Herick**

Grade	Relation between corneal Thickness & Ant. Chamber Depth	Interpretation
4	1 : 1 or higher	Angle closure very unlikely Angle approx. 35 .....45 degrees
3	1 : ½ (or higher)	Angle closure unlikely Angle approx. 20 – 35 degrees
2	1 : ¼ (or higher)	Angle closure possible, Angle approx. 20 degrees
1	1 : less than ¼	Angle closure very likely, Angle approx. 10 degrees
0	Closed	Angle closure, Angle approx. 0 degrees

**Table 2: Angle Classification on Gonioscopy (Shaffer)**

Grading	Angle Width	Findings	Angle Closure Risk
0	0	No angular structures are visible	Closed
1	10	Schwalbe's line is visible, Even the most anterior portion of the trabecular meshwork may be visible	High Risk
2	20	Trabecular meshwork is entirely visible	Possible
3	20-35	Scleral spur is visible	Impossible
4	35-45	Ciliary body is clearly visible	Impossible

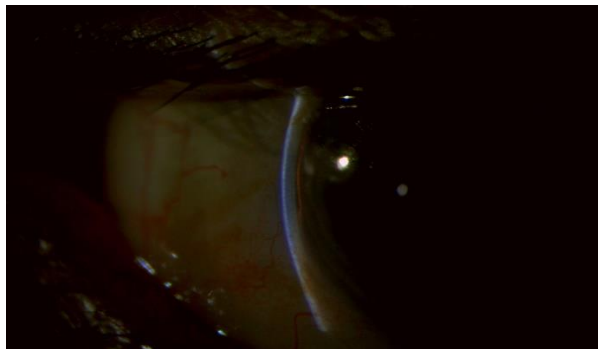
## Results

In 22 eyes with Van Herick grade 0 (slit angle), when no space was visible between cornea slit and iris slit (Fig. 1), gonioscopy showed closed angle (no angle structure visible) in all 22 eyes, showing 100% agreement. In 46 eyes with Van Herick grade 1 (angle closure very likely, Fig. 2), 43 eyes showed occludability on gonioscopy, where only 1/3 or less of anterior trabecular meshwork visible, showing 93% agreement. In 48 eyes with Van Herick grade 2 (angle closure possible), 38 eyes showed occludability on gonioscopy showing 79% agreement. In 58 eyes with Van Herick grade 3 (angle closure unlikely, Fig. 3), only 18 eyes showed angle to be occludable on gonioscopy depicting agreement of 70%. In 48 eyes of Van Herick grade 4 (angle closure not possible, Fig. 4), only 2 eyes showed angle to be occludable on gonioscopy showing agreement of 96%.

**Table 3: Observations & Results**

Van Herick Grade	Occludability according to Van Herick	No. of eyes	Number of eyes showing Occludability on gonioscopy	% of agreement
0	Closed	22	22	100
1	Very Likely	46	43	93
2	Possible	48	38	79
3	Unlikely	58	18	70
4	Very unlikely/ Not Possible	48	2	96
Total		222		Average Agreement 87.6%

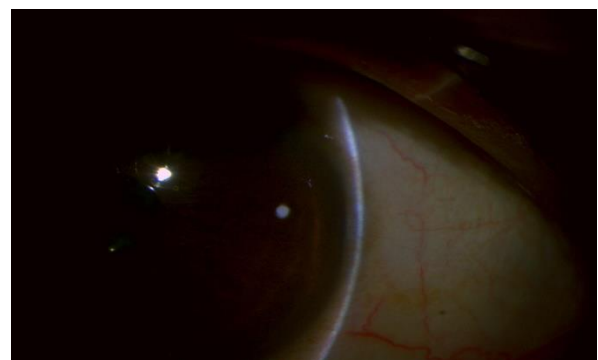
**Fig. 1: Van Herick Grade 0**



**Fig. 2: Van Herick Grade 1**



**Fig. 3: Van Herick grade 3**



**Fig. 4: Van Herick Grade 4**

## Discussions

In our study conducted, in eyes with seemingly narrow angles (Van Herick grade 0, 1 and 2), diagnosis of occludable angle was made on gonioscopy in 103 eyes out of 116 eyes (agreement 88.8%). On the other hand, in eyes with seemingly open angle (Van Herick grade 3 and 4), 86 were found non-occludable on gonioscopy out of 106 eyes (agreement 81.1%). The overall agreement seen in this study was 87.6%, which showed the test to be fairly accurate.

Several authors have studied significance, specificity and sensitivity of Van Herick test in several ways. A Japanese study on 923 eyes by Kenji Kashiwagi et al<sup>(8)</sup> in 2005 found good agreement between Van Herick grading and gonioscopy findings. However Shibal Bhartiya and Terek Sharaawy<sup>(11)</sup> in

2013 on 36 patients in African population a 77.78% disagreement between these. Thomas et al<sup>(3)</sup> in 1996 opined that flash light Van Herick tests are poor predictors for angle occludability. In 2011, a study by Park et al,<sup>(7)</sup> on 148 subjects, comparing these two and Anterior segment OCT, showed good agreement. In year 2000 study by Bonomi L et al<sup>(5)</sup> in Egna-Neumarket study of Epidemiology of angle closure glaucoma Van Herick and gonioscopy grading association was found useful.

In 1996 Wade Walls et al,<sup>(12)</sup> studied results of Van Herick grading and UBM (Ultrasound Biomicroscope) in 55 patients and UBM sub tense was found to be within the ranges found via van herick in 90.91% of subjects. In our series of 111 patients (222 eyes) of North India, an agreement of 87.6% between Van Herick grading and gonioscopy grading for assessing occludability of anterior chamber angle.

## Limitations of Van Herick Test

1. Results not readily reproducible because of difference in subjective assessment of thickness of cornea and its fraction as depth of peripheral anterior chamber.
2. If observer moves the slit beam too quickly, he assesses the depth of anterior chamber away from the most peripheral limbus and wrongly denotes high Van Herick grade.
3. In very dense arcus, there is difficulty in judging the most peripheral AC depth.
4. In patients who are blinking rapidly and not keeping the eyes steady, it is difficult to ascertain the depth. During gonioscopy, there is no issue of blinking and eyeball is also stabilized, allowing observation at ease.
5. In Van Herick grading only temporal and nasal angle depth can be observed, whereas in gonioscopy provides all around view of the angle.
6. During Van Herick observation, PAS, foreign body, vascularization, angle recession or other anomalies cannot be seen.

## Conclusion

In our study conducted on 222 eyes, the Van Herick method for estimation of peripheral anterior chamber depth very closely coincided with Gonioscopy findings and was found very useful method for quick and easy evaluations of eyes with narrow angle in population of north India. However gonioscopy must not be avoided for final assessment and management of patients.

## References

1. Van Herick W, Shaffer RN, Schwartz A. Estimation of width of angle of anterior chamber. Incidence and significance of the narrow angle. *Am J Ophthalmol.* (1969) 68, 626-629.

2. Friedman DS, He M. Anterior chamber angle assessment techniques. *Surv Ophthalmol.* (2008) 53, 250-273.
3. Thomas R, George T, Braganza A, Muliylil J. The flashlight tests and van Herick's test are poor predictors for occludable angles. *Aust NZ J Ophthalmol.* (1996) 24, 251-256.
4. Kashiwagi K, Tokunaga T, Iwase A, Yamamoto T, Tsukahara S. Usefulness of peripheral anterior chamber depth assessment in glaucoma screening. *Eye (Lond)* (2005) 19, 990-994.
5. Bonomi L, Marchini G, Maraffa M, Bernardi P, De Franco I, Perfetti S, Varotto A. Epidemiology of angle closure glaucoma: prevalence, clinical types, and association with peripheral anterior chamber depth in the Egna-Neumarkt Glaucoma Study. *Ophthalmology.* (2000) 107, 998-1003.
6. Salmon JF. Predisposing factors for chronic angle-closure glaucoma. *Prog Retin Eye Res.* (1999) 18, 121-132.
7. Alsbirk PH. Anatomical risk factors in primary angle-closure glaucoma. A ten year follow-up survey based on limbal and axial anterior chamber depths in a high risk population. *Int Ophthalmol.* (1992) 16, 265-272.
8. Park SB, Sung KR, Kang SY, Jo JW, Lee KS, Kook MS. Assessment of narrow angles by gonioscopy, Van Herick method and anterior segment optical coherence tomography. *Jpn J Ophthalmol.* (2011) 55, 343-350.
9. Kashiwagi K, Tokunaga T, Iwase A, Yamamoto T, Tsukahara S. Agreement between peripheral anterior chamber depth evaluation using the van Herick technique and angle width evaluation using the Shaffer system in Japanese. *Jpn J Ophthalmol* (2005) 49,134-136.
10. Devereux JG, Foster PJ, Baasanhu J, Uranchimeg D, Lee PS, Erdenbeleg T, Machin D, Johnson GJ, PH. Anterior chamber depth measurement as a screening tool for primary angle closure glaucoma in an East Asian population. *Arch Ophthalmol.* (2000) 118, 257-263.
11. Shibal Bhartiya, Tarek Shaarawy. Evaluation of the Van Herick Technique for Screening for Occludable Angles in an African Population. *J Curr Glaucoma Pract* (2013) 7, 88-90.
12. Wade Wall, Dawn Pewitt, Paul Williams, Eric Newberry, Terry Bush. A Comparison of Evaluation of the Anterior Chamber Angle via Van Herick Technique and the Ultrasound Biomicroscope. *American Academy of Optometry, Northeastern State University* (1996), Poster 53.