

## Periodontal considerations in orthodontic treatment

Vasu Kumar<sup>1,\*</sup>, Vijayta Yadav<sup>2</sup>, Mani Dwivedi<sup>3</sup>, Kusum Lata Agarwal<sup>4</sup>, Saquib Ahmad Asrar<sup>5</sup>

<sup>1,3,4,5</sup>PG Student, <sup>2</sup>Senior Lecturer, Dept. of Orthodontics, Career PG Institute of Dental Sciences, Uttar Pradesh

**\*Corresponding Author:**

Email: vashuabc@gmail.com

### Abstract

Harmonious cooperation of the general dentist, the periodontist and the orthodontist offers great possibilities for the treatment of combined orthodontic–periodontal problems. Orthodontic treatment along with patient's compliance and absence of periodontal inflammation can provide satisfactory results without causing irreversible damage to periodontal tissues. Orthodontic treatment carries with it the risks of tissue damage, treatment failure and an increased predisposition to dental disorders. The dentist must be aware of these risks in order to help the patient make a fully informed choice whether to proceed with orthodontic treatment. The aim of this study is to discuss the principles of orthodontic treatment in patients with reduced periodontium, its indications and limitations, as well as current views concerning retention of orthodontic result.

**Keywords:** Periodontal tissues, Retention, Periodontium, Orthodontics

### Introduction

Certain malocclusion traits are associated with difficulties in maintaining good oral hygiene and as a consequence to poor periodontal condition.<sup>(1)</sup> Therefore, proper alignment of the teeth provided by orthodontic treatment may promote good control of soft deposit and calculus and subsequent periodontal inflammation. It has been known that orthodontic appliances have been a local etiologic factor contributing to periodontal problems. Uprighting and extrusion are two movements that are used to aid in the treatment of difficult periodontal and restorative problems.<sup>(2)</sup> In order to conduct orthodontic therapy most effectively it is essential that orthodontists and periodontists utilize a coordinated approach. The development of new treatment options in periodontics and orthodontics, e.g., guided tissue regeneration or orthodontic implants for temporary skeletal anchorage, offer new ways in treatment of periodontally affected patients.<sup>(3)</sup>

**Periodontal Diagnosis before Orthodontic Treatment:** Before starting the orthodontic treatment a careful assessment of periodontal health condition should be assessed, as several studies have reported that if orthodontic is performed in persisting periodontal disease it may aggravate the situation. Zachrisson et al<sup>(13)</sup> reported an increase in gingival pocket depth after orthodontic treatment with edgewise appliance due to edematous swelling in the gingiva and by tissue accumulation during tooth movement but not by deepening of the pocket. Hence, special emphasis should be given on the following:

### Literature Review

The following questionnaires should be kept in mind while taking the history of the patient. The patient should be asked about:

- a. The occurrence of any previous periodontal disease
- b. Drug history, e.g. use of long-term corticosteroids, phenytoin, etc.
- c. Systemic diseases or physiological conditions, e.g. pregnancy, diabetes, asthma, chronic renal failure, etc.

### Clinical Examination:

Check for the following:

1. Bleeding on probing
2. Tooth mobility
3. Thin fragile gingiva
4. Pockets.

**Biological And Molecular Basis of Orthodontic Tooth Movement:** Tooth movement by orthodontic force application is characterized by remodeling changes in dental and paradental tissues. The periodontium consists of the periodontal ligament (PL), alveolar bone (AB), cementum and gingiva. The PL is a specialized matrix rich, mixed cellular/ fibro-connective tissues. It plays a pivotal role in signal transduction pathways, involving repair and remodeling of the PL, cementum and alveolar bone. Fibroblasts, osteoblasts, osteocytes, osteoclasts, odontoblasts, cementoblasts, chondrocytes and immune cells are the major cell types involved in the remodeling process. The PL contains primarily the Type I and Type III collagen fibers and the Type I is the dominant collagen. The principal and oxytalan fibers are the predominant elastic fibers, which provide elasticity to the ligament during the tension related force on the ligament. The PL extracellular matrix (ECM) contains a large quantity of glycoproteins, and proteoglycans (biglycans, decorins), fibromodulin, and fibronectin. These molecules perform multiple functions including cell migration and cell proliferation. They also readily respond to the mechanical forces. Fig. 1 presents a sagittal graphic

view of the anatomical and vascular structures of the periodontium.

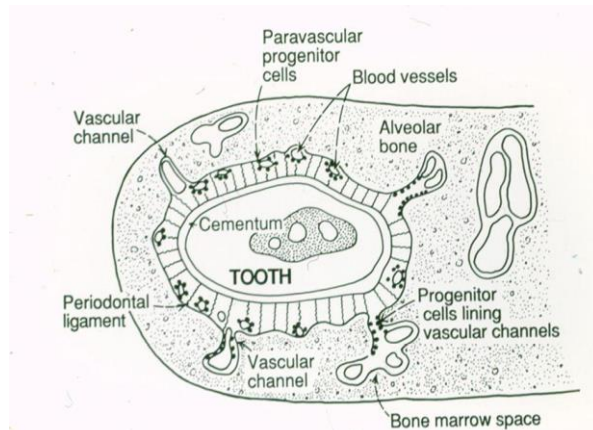


Fig. 1: Shows the anatomical and cellular structures of the periodontium (By Dr. Lekic)

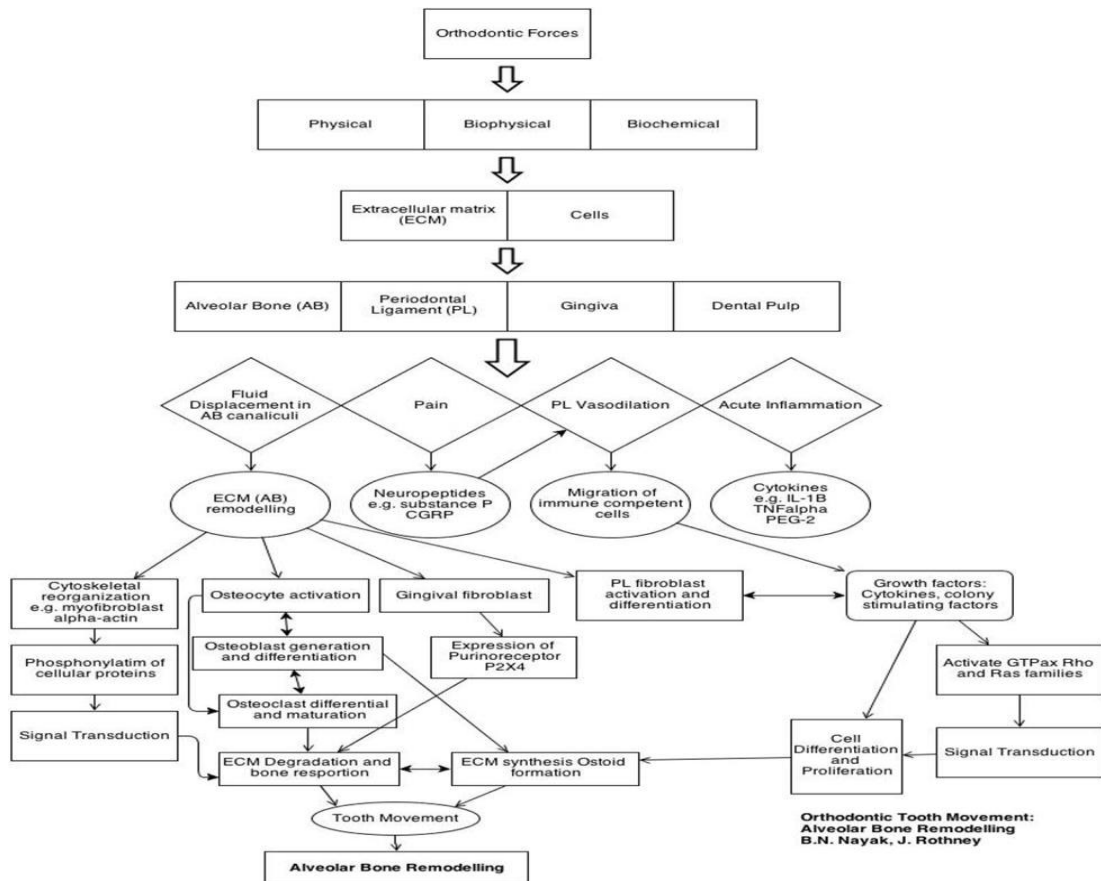


Fig. 2: Orthodontic tooth movement & sequence of molecular event

The various tooth movements that occur during orthodontic tooth movement are:

1. Extrusion
2. Intrusion
3. Tipping
  - Uncontrolled
  - Controlled
4. Bodily movement.

**Extrusion:** Extrusion or eruption of a tooth, or several teeth, along with reduction of the clinical crown height is reported to reduce infrabony defects and decrease pocket depth and this tooth movement even causes formation of new bone at the alveolar crest as the tooth erupts with no occlusal factor present. Raymond yukna et al (1985)<sup>(6)</sup> studied the effects of extrusion of teeth with advanced periodontal disease.

**Intrusion:** Intrusion alters the cements enamel junction and angular crest relationships, and creates only epithelial root attachment; therefore, a periodontally susceptible patient is at greater risk of future periodontal breakdown. When this tooth movement is properly executed, it improves the periodontal condition and is beneficial to periodontal health.

**Tipping:**

- a. **Uncontrolled tipping:** When heavy forces applied at the alveolar crest while performing uncontrolled tipping tooth movement, severe destruction of the epithelial attachment and crestal bone loss takes place. The crestal bone loss shifts the center of resistance apically, thus a large amount of moment will be generated on application of a very small amount of orthodontic force.<sup>(11)</sup>
- b. **Controlled tipping:** Controlled tipping produces high force on the periodontal ligament, as the fulcrum shifts more and more apically with increasing amounts of bone loss.

**Bodily Movement:** Recently studies<sup>(4)</sup> have shown that bodily movement causes an improved connective tissue attachment and worsens the bony defect. Hence, this movement is contraindicated when there is a periodontally compromised patient.

**Periodontal Surgery Associated With Orthodontic Therapy**

**Gingival Curettage:** Curettage means scraping of the gingival wall of a periodontal pocket to remove infected and necrotic tooth substance. The aim of the curettage is to reduce pocket depth by enhancing gingival shrinkage and new connective tissue attachment.

**Gingivectomy:** Gingivectomy means excision of gingiva.<sup>(14)</sup> The gingivectomy technique is useful in improving orthodontic results, especially in cases with missing maxillary central or lateral incisors, after premolar autotransplantation or in gummy smiles.

**Gingivoplasty:** Gingivoplasty<sup>(9)</sup> is the reshaping of gingiva to create physiologic gingival contours, for the sole purpose of recontouring the gingiva in the absence of pockets.

**Crown Lengthening:** Crown lengthening<sup>(14)</sup> is a simple localized gingivectomy to the bottom of the clinical gingival sulcus will increase the crown length.

**Fibrotomy:** Methods to reduce the relapse of orthodontically treated rotated teeth could be the use of fibrotomy technique. Periodontal fiber bundles that influence stability are the principal fibers of PDL and the supra-alveolar fibers.

**Frenotomy:** Frenotomy with only partial removal of the frenum with the purpose of relocating the attachment in a more apical direction is currently undertaken.

**Gummy Smile Management:** When considering soft tissue, an excessive gingival display and asymmetry of the gingival margins can impair the esthetic value of the smile. Any band of gingiva, other than the papillary

tips, that appears at rest is unnecessary. Thus 2mm of gingival display above the tooth margin upon smiling is considered to be excessive, and called a “Gummy smile”. Amongst all the causes most common is altered passive eruption.

**Orthodontic Treatment of Periodontal Problems**

a. Orthodontic Treatment of Gingival Discrepancies

1. **Uneven Gingival Margins:** If a gingival margin discrepancy is present but the discrepancy is not exposed, it does not require correction. If the shorter tooth has a deeper sulcus, excisional gingivectomy may be appropriate to move the gingival margin of the shorter tooth apically. If the shortest central is still longer than the lateral incisors, the other possibility is to extrude the longer central incisor and equilibrate the incisal edge. If one incisal edge is thicker labiolingually than the adjacent tooth, this may indicate that it has been abraded and the tooth has overerupted. In such cases, the best method of correcting the gingival margin discrepancy is to intrude the short central incisor.
2. **Open Gingival Embrasures:** The presence of a papilla between the maxillary central incisors is a key esthetic factor in any individual. This open space is usually due to one of three causes: tooth shape, root angulation, or periodontal bone loss.

b. Orthodontic Treatment of Osseous Defects

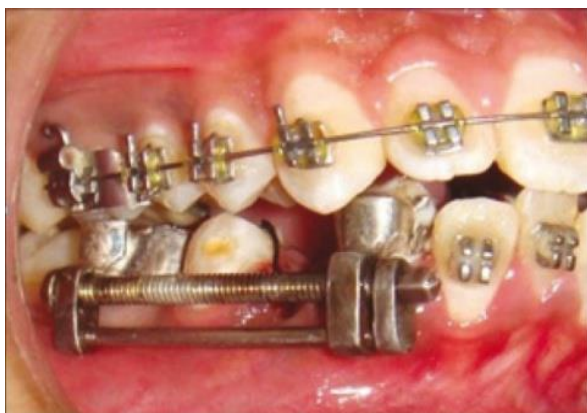1. **Hemiseptal Defects:** Hemiseptal defects are one- or two-wall osseous defects that often are found around mesially tipped teeth or teeth that have supraerupted. Usually, these defects can be eliminated with the appropriate orthodontic treatment.
2. **Advanced Horizontal Bone Loss:** If patient has underlying periodontal problems and significant alveolar bone loss around certain teeth, using the anatomy of the crown to determine bracket placement is not appropriate.<sup>(5)</sup>
3. **Furcation Defects:** Furcation defects can be classified as incipient (Class I), moderate (Class II), or advanced (Class III). These patients need to be maintained on a 2 to 3 month recall schedule. Detailed instrumentation of these furcations helps minimize further periodontal breakdown.<sup>(5)</sup>

**Maxillary Midline Frenum:** A U- or V-shaped roentgenographic appearance of the interproximal bone between the maxillary central incisors is a diagnostic key to the persistent midline diastema. Generally, surgical removal of a maxillary labial frenum should be delayed until after orthodontic treatment, unless the tissue prevents space closure or becomes painful and traumatized.

**Current Concepts**

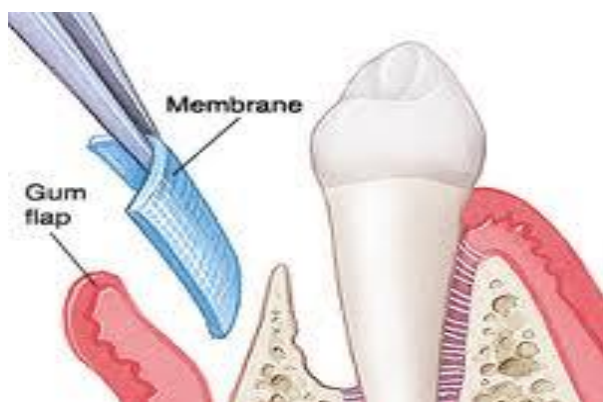**Distraction osteogenesis of the periodontal ligament:**

Distraction osteogenesis is the process of growing new bone by mechanical stretching of pre-existing bone tissue. A new concept of distracting the PDL is proposed to elicit canine retraction in 3 weeks. This is called dental distraction. The PDL acts as a suture between the bone and the tooth. Fig. 3

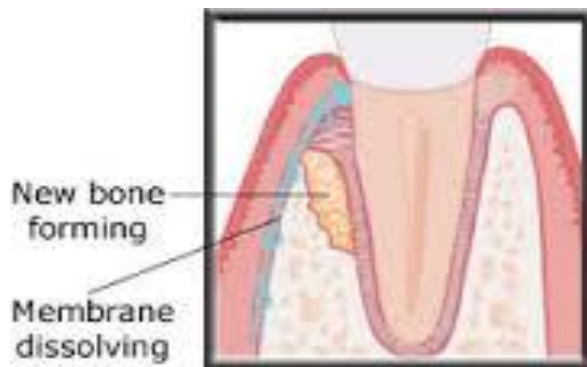


**Fig. 3: Distraction Osteogenesis**

**Guided Tissue Regeneration:** The fundamental change in the healing of periodontal lesions is the use of a barrier membrane to prevent cells of the gingival connective tissue and the epithelium from colonizing the decontaminated root surface. Cells of the residual periodontal ligament and from bone marrow spaces are allowed to initiate genuine periodontal regeneration and a new cementum layer with inserting collagen fibres and new alveolar bone. There is still controversy as to the role of additional bone grafting materials to support the formation of the new attachment.<sup>(8)</sup> Fig. 4 and Fig. 5

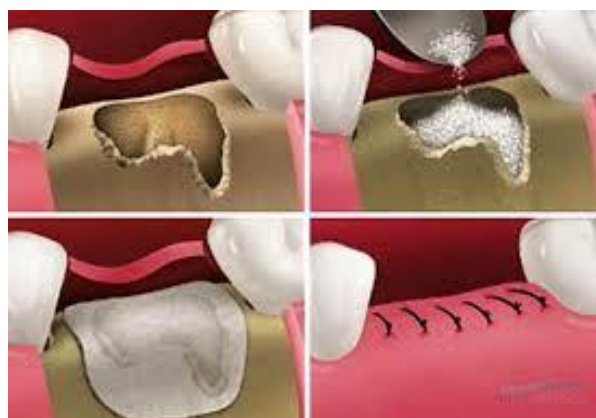


**Fig. 4**



**Fig. 4, 5: Guided tissue Regeneration**

**Guided bone regeneration:** A variant of GTR is the restoration of lost bone around implants or in constricted bone areas in preparation for implantation. This guided bone regeneration (GBR) introduced by **Dahlin et al 1988,**<sup>(7)</sup> might also be useful for an orthodontic movement of teeth into long-standing atrophied alveolar process.<sup>(7)</sup> Fig. 6



**Fig. 6: Guided Bone Regeneration**

**Preventive Programme for Orthodontic Patients with Fixed Appliances**

**Before Orthodontic Treatment:**

1. Initial **diagnosis** and **referral** for treatment to control active periodontal disease and caries
2. Informed consent of the risks during orthodontic treatment and responsibilities of the patients and clinician
3. All general dental and periodontal treatment completed before orthodontic treatment

**During Orthodontic Treatment**

1. Provide the patient with initial **brushing instruction** with orthodontic tooth brush when the appliances are first placed. The patient should use fluoride toothpaste with that also has an antigingivitis effect.
2. Record plaque removal effectiveness in the patient's chart.
3. Use a positive reinforcement approach (praise) and avoid criticism.
4. Introduce additional methods to improve oral hygiene



such as flossing only when success is established with simple brushing.

5. If poor **compliance** persists (more often in adolescents), the following steps may be considered:
  - a. Schedule more frequent orthodontic visits (every 3 to 4 weeks) when the assistant can spend more time with the patient
  - b. Schedule the patient with an auxiliary who has the best motivational skills.
  - c. Send a letter describing the problems to the patient or parents as well as the general dentist.
  - d. If all this fails, consider the use of a chlorhexidine (Fig. 7) rinse treatment for 12 weeks



**Fig. 7: Mouthwash**

**After Orthodontic Treatment:** At the completion of orthodontic treatment the clinician should encourage the patient to maintain proper oral hygiene habits.

1. Make sure all children and adolescents are using fluoride toothpaste with an ADA seal of approval at least twice daily to promote remineralization.
2. Make sure that the patient has resumed routine dental care with the general dentist.
3. Send a post treatment report to the patient and to the general dentist. Outline future responsibilities and how well the goals of treatment have been achieved.<sup>(12,15)</sup>

### Conclusion

Treatment of periodontal disease is a complex and multidisciplinary procedure, requiring periodontal, surgical, restorative, and orthodontic treatment modalities. The aim of this review was to describe, with the help of recent research information's, the possible interactions between orthodontics and periodontics. It is well-known that the periodontal structures of a tooth play an important role during its orthodontic movement; this should therefore be considered before, during and after any orthodontic treatment.

### References

1. Evidence-based care in orthodontics and periodontics: a review of the literature: J Am Dent Assoc 1999;130:521-7.
2. Wagenberg BD; The role of orthodontics in periodontics and restorative dentistry: Compendium. 1993;14:1180.
3. Reichert C, Kasaj A, Willershausen B; Orthodontics--periodontics: yesterday and today; a review of the

- literature: Schweiz Monatsschr Zahnmed. 2009;119:784-91.
4. Eliasson LA, Hugoson A, Kurol J, Siwe H. The effects of orthodontic treatment on periodontal tissues in patients with reduced periodontal support. Eur J Orthod 1982;4:1-9.
5. Socransky S.S. New concept of destructive periodontal disease J. Clinical periodontal 1984;2:11-21.
6. Venrooy JRV, Yukna RA. Orthodontic extrusion of single rooted teeth affected with advanced periodontal disease. Am J Orthod 1985;87:67-9.
7. Dahlin C, Linde A, Gottlow J & Nyman S. Healing of bone defects by guided tissue regeneration. Plastic and Reconstructive Surgery. 1988;81:672-6.
8. Schallhorn RG, McClain PK: Combined osseous composite grafting, root conditioning, and guided tissue regeneration. Int J Periodontics Restorative Dent. 1988;8:8-31.
9. Huser MC, Baehni PC, Lang R. Effects of orthodontic bands on microbiological and clinical parameters. Am J Orthod Dentofac Orthop 1990;97:213-8.
10. Carranza' Clinical periodontology. 7<sup>th</sup> edition 1990 ch. 53;704-18.
11. Proffit WR. Biologic basis of orthodontic therapy. In: Proffit WR, Fields HW. Contemporary orthodontics (3rd ed). St Louis: Mosby 2000:331-58.
12. Kalia S, Melsen B. Interdisciplinary approaches to adult orthodontic care. Journal of Orthodontics 2001;28:191-6.
13. Zachrisson BU. Orthodontics and periodontics. In: Lindhe J, Karring T, Lang NP (Eds). Clinical periodontology and implant dentistry (4th ed). Oxford: Blackwell Munksgaard 2003:744-80.
14. Sonick M, Hwang D. Periodontal plastic surgery II: Esthetic crown lengthening. Dept. Microsurgery 2008;2.
15. Liran Levin, Shmuel Einy, Hadar Zigdon, Dror Aizenbud, Eli E. Machtei; Guidelines for periodontal care and follow-up during orthodontic treatment in adolescents and young adults: J Appl Oral Sci. 2012;20:399-403.
16. BN Nayak, Galil KA, Wiltshire Wand Lekic PC; Molecular Biology of Orthodontic Tooth Movement: J Dent Oral Health 2013 Vol 1: 101.
17. Dr. Shilpa Choudhari et al; Esthetic Crown Lengthening: a Treatment for "Gummy Smile" – A Case Report 20114; 3 ISSN No 2277–8179.
18. Melsen B, Agerbaek N, Maekens G. Intrusion of incisors in adult patients with marginal bone loss. Am J Orthod 1989;96:232-7.