

## Orthodontic-surgical management of impacted maxillary central incisor

Ashish Kumar<sup>1,\*</sup>, Amit Nagar<sup>2</sup>, Pradeep Tandon<sup>3</sup>

<sup>1</sup>Senior Resident, <sup>2</sup>Professor, <sup>3</sup>Professor & HOD, Dept. of Orthodontics & Dentofacial Orthopaedics, FODS, Kings George Medical University, Lucknow, Uttar Pradesh

**\*Corresponding Author:**

Email: drashish01@gmail.com

### Abstract

Maxillary incisors and canine, often referred to as the social six are most prominent teeth in an individual's teeth. Impaction of maxillary central incisors are less frequently than third molars and canines because of several contributing factors. Treatment of impacted teeth requires a combined orthodontic and surgical perspective. In the presented case we have used Closed-eruption technique combined with alteration in biomechanics and this had resulted in good long-term esthetic results.

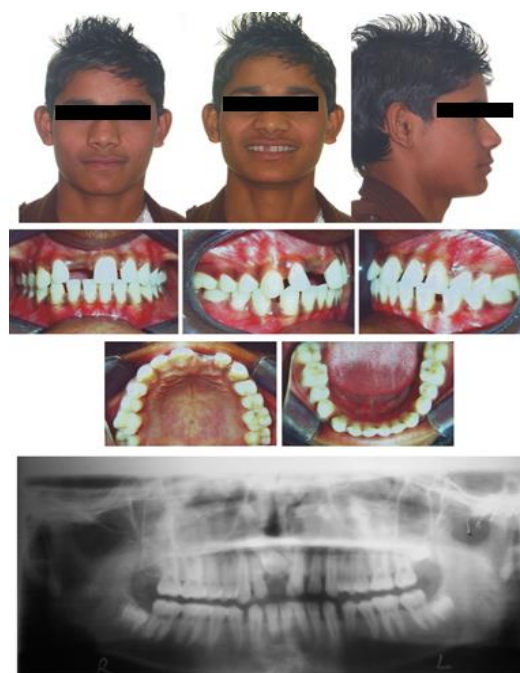**Keywords:** Maxillary incisor; Impaction; Closed eruption technique; Modified biomechanics.

### Introduction

Maxillary incisors and canine, often referred to as the social six are most prominent teeth in an individual's teeth. They are also the teeth that are on maximum display during speech so they are crucial to facial aesthetics and phonetics. Missing upper incisors are regarded as unattractive and they have an effect on self-esteem and general social interaction so it is important to detect and manage the problem as early as possible. Its prevalence has been estimated as 2.6%. Impaction of maxillary central incisors are less frequently than third molars and canines.<sup>(1,2)</sup> Several contributing factors have been suggested that impede tooth eruption. These could be supernumerary teeth in anterior maxillary region,<sup>(3,4)</sup> Tumors such as odontomas or cysts,<sup>(5)</sup> Any alteration in eruption path or formation of scar tissue due to trauma or premature loss of the primary incisors<sup>(6)</sup> and abnormal root angulation or dilacerations.<sup>(7)</sup> Treatment of impacted teeth requires a combined orthodontic and surgical perspective. Surgical exposure can be performed in 3 ways- Circular excision of oral mucosa covering the impacted tooth, Apically repositioning the raised flap that incorporates attached gingiva overlying the impacted tooth or Closed-eruption technique in which the raised flap that incorporates attached gingiva is fully replaced in its former position, after an attachment has been bonded to the impacted tooth. Vermette et al<sup>(8)</sup> compared the apically positioned flap with closed eruption technique and found better results in terms of gingival, periodontal, and pulp status with the closed-eruption technique. Adrian Becker et al<sup>(9)</sup> evaluated the post-orthodontic periodontal evaluation of closed eruption surgical technique and reported the quality of treatment outcome and demonstrated that overall good long-term esthetic results can be achieved by treating impacted maxillary incisors with a closed-eruption orthodontic surgical technique.

### Case Presentation

An 18 year old male patient reported to the Department of Orthodontics & Dentofacial Orthopedics, KGMU Lucknow with the chief complaint of missing permanent maxillary right central incisor. The facial profile was straight and Patient was having Angle's class I molar relationship on both left and right side with all the permanent teeth erupted in maxillary and mandibular arch except third molar and missing permanent right central incisor, spacing was present in both maxillary and mandibular incisor. The radiographic examination revealed an impacted permanent right central incisor as well as missing maxillary right third molar. No lateral cephalogram was taken as the facial profile was orthognathic.

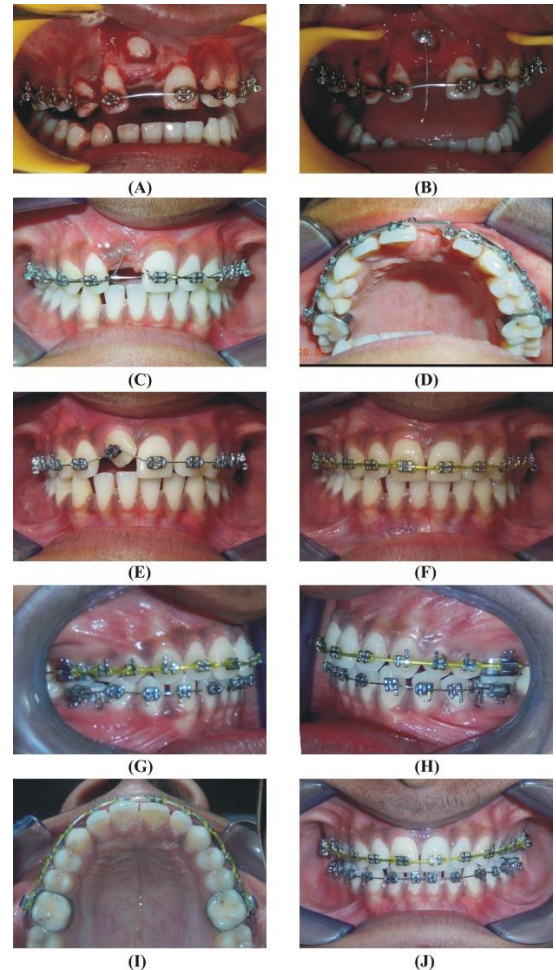


**Fig. 1: Pretreatment Photographs & Radiograph**

Objectives of treatment were:

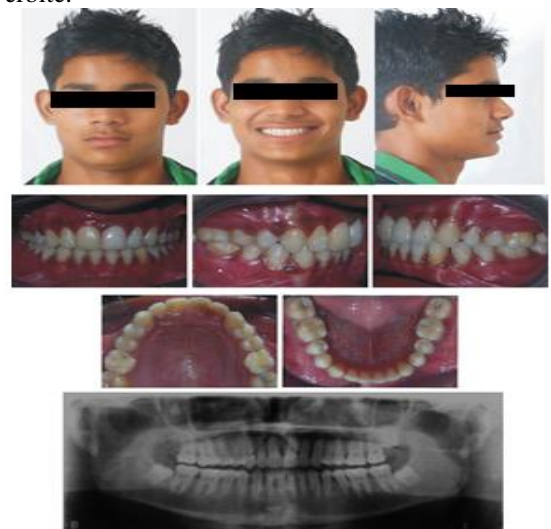- Orthodontic correction of maxillary right central incisor after surgical exposure and alignment in the maxillary arch
- Closing of space in maxillary and mandibular arch
- Achieve an optimum functional occlusion with acceptable aesthetics.

**Treatment progress:** A preadjusted 0.022x0.028 Roth prescription was banded and bonded in the maxillary arch. Alignment and levelling was started with .016 NiTi which was sequentially changed upto 0.019x0.025 SS wire. During this alignment phase the space for central incisor was preserved by joining the adjacent tooth with ligature wire tying. After the alignment and levelling, surgical exposure was done and a lingual button tied to ligature wire was bonded to the exposed surface and the flap was again closed with the help of sutures. The attachment ligature wire was adopted to bracket of adjacent tooth and the patient recalled after 7 days with prescribed medication for 3 days. After 7 days the sutures were removed and a new wire of 0.019x0.025 dimension in SS with a helix in palatal and distal direction was ligated and an elastic module was ligated to the helix and attachment wire and traction force was applied, the modules were changed every 15 days. After 4 months the incisor surface was exposed in the oral cavity. At that time a central incisor bracket was bonded and an 0.014 thermal NiTi overlay wire was ligated. For alignment and levelling wire was changed sequentially after 3 month the space closure was done with help of E chains. The mandibular arch was also banded and bonded for space closure. After these the arches were debonded and fixed retainor in maxillary and a Hawleys retainer in mandibular arch were delivered.



**Fig. 2: Biomechanics involved in case**

**Treatment results:** Total treatment duration was 12 months, the patient had a harmonious dental relationship, pleasing profile, competent lips with a good Class I buccal occlusion, positive overjet, and overbite.



**Fig. 3: One Year post retention photograph & radiograph**

## Discussion

Although the impacted maxillary Incisors occur less frequently than the maxillary canine, it concerns the parents in the early mixed dentition because of the non-eruption of the teeth. Several clinicians have successfully treated impacted maxillary anterior teeth by proper crown exposure surgery and orthodontic traction and indicated that an impacted tooth can be brought to proper alignment in the dental arch.<sup>(10-12)</sup>

The current treatment modality instead of extraction has used surgical crown exposure and orthodontic positioning of the tooth. Factors considered for successful alignment of an impacted tooth: The position and the direction of impacted tooth, degree of root completion and presence of space for impacted tooth. These factors were considered before planning treatment for this case. The present case was treated using the closed-eruption surgical technique as suggested by Vermette ME.<sup>8</sup> The technique induced natural tooth eruption of the impacted tooth rather than conventional design of the apically positioned flap. Another factor is the direction to which we wanted the tooth to be moved, a thorough knowledge of biomechanics is required to achieve the desired result with the lowest harm to other structures. In this case we have utilised a force vector which moves the tooth in disto-palatal and occlusal direction from the initial force application and we have achieved the result without any attachment loss. In this case, the periodontal status of the exposed incisor after orthodontic treatment revealed an acceptable gingival contour and attached gingiva. No further mucogingival surgery was recommended.

## Conclusion

Surgical exposure and orthodontic retraction of impacted incisor is a clinical challenge. Although a proper knowledge of biomechanics and treatment planning can help to a great degree in achieving the desired result with a good stability.

## References

1. Becker A. Early treatment of impacted maxillary incisors. *Am J Orthod Dentofacial Orthop* 2002;121:586-7.
2. Lin YT. Treatment of an impacted dilacerated maxillary central incisor. *Am J Orthod Dentofacial Orthop* 1999;115:406-9.
3. Giancotti A, Grazzini F, De Dominicis F, Romanini G, Arcuri C. Multidisciplinary evaluation and clinical management of mesiodens. *J Clin Pediatr Dent* 2002;26:233-7.
4. Ibricevic H, Al-Mesad S, Mustagrudic D, Al-Zohejry N. Supernumerary teeth causing impaction of permanent maxillary incisors. *J Clin Pediatr Dent* 2003;27:327-32.
5. Batra P, Duggal R, Kharbanda OP, Parkash H. Orthodontic treatment of impacted anterior teeth due to odontomas: a report of two cases. *J Clin Pediatr Dent* 2004;28:289-94.
6. Yocheved Ben Bassat, Ilana Brin, Anna Fuks, CD Yerucham Zilberman. Effect of trauma to the primary incisors on permanent successors in different developmental stages. *Pediatric Dentistry* 1985;7:37-40.
7. Yng-Tzer J. Lin. Treatment of an impacted dilacerated maxillary central incisor. *Am J Orthod Dentofacial Orthop* 1999;115:406-9.
8. Vermette ME, Kokich VG, Kennedy DB. Uncovering labially impacted teeth: apically positioned flap and closed eruption techniques. *Angle Orthod* 1995;65:23-32.
9. Adrian Becker, Ilana Brin, Yocheved Ben-Bassat, Yerucham Zilberman, and Stella Chaushu. Closed-eruption surgical tech-nique for impacted maxillary incisors: A postorthodontic periodontal evaluation. *Am J Orthod Dentofacial Orthop* 2002;122:9-14.
10. Bishara SE. Impacted maxillary canines: a review. *Am J Orthod Dentofacial Orthop* 1992;101:159-71.
11. Eiji Tanaka, Phdmineo Wata-nabe, Phdkeiko Nagaoka, Dskazunori Yamaguchi, Kazuo Tanne, Orthodontic Traction Of An Impacted Maxillary Central Incisor. *J Clin Ortho* 2001;35:375-78.
12. Thosar N.R, Vibhute P. Surgical and orthodontic treatment of an impacted permanent central incisor: A case report. *J Indian Soc Pedod Prev Dent* June 2006;100-103.