

## An evaluation of acrylic spherical implant in cases of evisceration

Ram Kumar<sup>1,\*</sup>, Akash Srivastava<sup>2</sup>, Deepti Yadav<sup>3</sup>

<sup>1</sup>Professor, <sup>2,3</sup>Junior Resident, Dept. of Ophthalmology, BRD Medical College, Gorakhpur, Uttar Pradesh

**\*Corresponding Author:**

Email: ramkumarjaiswal35@gmail.com

### Abstract

**Purpose:** To evaluate the acceptance of implant and cosmetic results achieved following evisceration operation with use of non integrated spherical acrylic implant.

**Method:** The patient included in the study were taken from the out patient department of upgraded department of ophthalmology B.R.D Medical College; Gorakhpur, from December 2015 to November 2016. Since the study involved mutilating surgery of eye only those patients were selected in whom either there was specific indication for sacrificing the eye or there was no chance of any visual recovery. In all, 40 patient formed the study group of whom, 32 cases were panopththalmitis; 4 were of endophthalmitis and 4 were of anterior staphyloma. Detailed history taken and examination done under (a) General examination (b) Systemic examination and (c) Detailed ocular examination. Procedure and its probable ultimate outcome along with complications was explained to patients and only those patients who willingly accepted for surgery were included in the study. Cases of Necrotizing scleritis and perforating injury of sclera are excluded from the study. Post surgery the patient was evaluated 3<sup>rd</sup> day, then after discharge on 1<sup>st</sup> week, 4<sup>th</sup> week and 6<sup>th</sup> months. During all follow up's; examination was done with emphasis on following parameters: (a) any complaints by patient i.e. pain, discharge, discomfort etc., (b) wound healing, (c)examination of prosthesis bed. (d) shape & formation of socket (e) fitness of eye prosthesis. (f) movement of prosthetic eye.

**Result:** Of the total study group, 80% of patient were of panophthalmitis (maximum), while those of endophthalmitis and anterior staphyloma comprising 10% each. Out of 40 patients, 24 (60%) underwent evisceration with acrylic spherical implant placement and in the rest 16 (40%) no implant was put. Of the 24 patient in whom evisceration was done with acrylic spherical implant placement, all complained of discomfort, discharge and pain on 3<sup>rd</sup> post op day. On routine follow up at 1<sup>st</sup> week, pain present in just 6(25%) cases, discomfort in 18(75%), and discharge in 21((87.5%) cases, at 4<sup>th</sup> week post op, only 2 (8.3%) cases complained of discomfort, with no discharge or pain. Of the 16 patient who underwent evisceration without implant placement, symptoms of discharge, discomfort and pain were present in all 100% on 3<sup>rd</sup> post op day. Discharge was seen only in 6(37.5%) cases with discomfort in 10(62.5%) and pain present only in 4(25%) cases each at 1<sup>st</sup> week follow up. At 6<sup>th</sup> month discharge was present in 20.8% cases in implant groups and 25% in without implant. Other prominent complication was conjunctival dehiscence seen in 4(16.6%) cases at 2<sup>nd</sup> week in implant group. Exposure of the implant occurred in 3(12.5%) at 2<sup>nd</sup> week follow up.

**Conclusion:** Socket complication like superior sulcus deformity and anophthalmic-enophthalmos following evisceration were bare minimum in patient with implant placement. Cosmetic result in terms of amplitude and range of movements of artificial eye in cases of evisceration with implant placement is much better in all four gazes as compared to those without implant placement. To achieve near natural cosmetic appearance in terms of "eye movement(prosthetic eye)" spherical implant placement is modality of choice.

**Keywords:** Acrylic sphere, Evisceration, Prosthetic eye, Superior sulcus deformity

### Introduction

For some obvious reasons an ophthalmic surgeon is reluctant to undertake the destructive operation<sup>(1)</sup> in the eye, but under compelling situations like painful blind eye and intraocular malignancy, one has no other alternative but to sacrifice the diseased eye. The two most commonly performed surgeries for removal of eye are evisceration and enucleation.<sup>(2)</sup> Evisceration is the complete evacuation of intraocular contents through an opening in sclera or through keratectomy while preserving the scleral shell and all of the extra ocular appendages.<sup>(3)</sup> Out of the total orbital volume<sup>(4)</sup> of 30cc, removal of an eye causes a loss of 7cc of orbital content. This volume deficit leads to a disfiguring condition called "post evisceration socket syndrome" (PESS),<sup>(5)</sup> and distortion of fornix following evisceration. Enophthalmos is directly caused by an orbital content volume loss by removal of intra ocular contents, which cannot be compensated alone by

prosthesis.<sup>(6)</sup> Therefore, after performing these operations, the cosmetic goals are: (1) to replace the lost volume of socket, (2) to restore near natural appearance and movements of/with an artificial eye. **Anophthalmic orbit syndrome**<sup>(7)</sup> the main complication of anophthalmic socket is anophthalmic orbit syndrome, characterised by, Anophthalmos, superior sulcus depression, upper lid ptosis, lower lid laxity & malposition of lids. Such maldevelopment of the socket can be prevented by implantation of orbital implants.

### Method

The patient included in the study were taken from the O.P.D of upgraded department of ophthalmology, B.R.D Medical College, Gorakhpur, from December 2015 to November 2016. Since the study involved mutilating surgery of eye only those patients were selected in whom either there was specific indication

for sacrificing the eye or there was no chance of any visual recovery. In all, 40 patient formed the study group of whom, 32 cases were panopnthalmitis; 4 were of endophthalmitis and 4 were of anterior staphyloma. Detailed history taken and examination done under (a) General examination (b) Systemic examination and (c) Detailed ocular examination. Procedure and its probable ultimate outcome along with complications was explained to patients and only those patients who willingly accepted for surgery were included in the study. **Cases of Necrotizing scleritis and perforating injury of sclera are excluded from the study. Pre-operative management include-** Xylocaine sensitivity, frequent instillation of broad spectrum plain antibiotic drop in diseased eye, started from the time of hospitalisation. I.V antibiotic (ceftazidime, ceftriaxone) started 24 hours prior to surgery. Injection diclofenac sodium 75mg and diazepam 10mg intramuscular 30min prior to surgery is given. **Per operative-** steps includes: placement of wire speculum, 360 degree conjunctival peritomy<sup>(8)</sup> is done, limbal incision given, corneal button is removed, intra ocular contents removed with evisceration spoon, acrylic spherical implant placed in scleral shell, interrupted 6-0, prolene suture placed in sclera shell, tenon’s capsule is closed with interrupted 6-0 chromic catgut, conjunctiva closed with continuous 6-0 silk suture, conformer placed in conjunctival sac and pressure dressing applied with plain antibiotic ointment. **Post –op management-I.V** antibiotics with oral serratiopeptidase 10mg b.d were given with anti-inflammatory & analgesics for 1 week, first dressing was done on 3<sup>rd</sup> post op day, conformer was left in place and broad spectrum topical antibiotic was strated with frequency of 4 times a day, conjunctival silk suture were removed on day 7 and pt was discharged with conformer in place. **Follow –up:** the patient were called 1 week after discharge for first routine check up.

Depending upon the condition of prosthetic bed, the patient was again called back after 4-6 weeks and conformer was removed. Taking into consideration the colour of normal eye, appropriate sized artificial eye prosthesis was given in the same visit. During later follow-up check up was don e with emphasis on following parameters: (a) any complaints by patient i.e. pain, discharge, discomfort etc. (b) wound healing, (c) examination of prosthesis bed. (d) shape & formation of socket. (e) fitness of eye prosthesis. (f) movement of prosthetic eye.

**Observation**

The present study included 40 patient of evisceration; of whom 24 patient were operated with acrylic implant placement and 16 patient were operated without implant. Cosmetic shell is given at 4<sup>th</sup> week. Thus the observations of present study are based on findings of 40 patient, who underwent evisceration surgery and evaluation.

**Table 1: Age Distribution/ Sex distribution**

Age group (years)	Male	Female	Total
10-20	3	0	3
20-40	2	2	4
40-60	7	11	18
>60	10	5	15
Total	22(55%)	18(45%)	40(100%)

**Table 2: Distribution of study cases**

Pathology	No. of Cases
Panophthalmitis	32 (80%)
Endophthalmitis	4 (10%)
Anterior Staphyloma	4 (10%)
Total	40 (100%)

**Table 3: Surgery performed: types of cases(%)**

Evisceration	Panophthalmitis	Endophthalmitis	Anterior Staphyloma	Total
With acrylic spherical implant	16 (40%)	4 (10%)	4 (10%)	24 (60%)
Without implant	16 (40%)	-	-	16 (40%)
Total	32 (80%)	4 (10%)	4 (10%)	40 (100%)

**Table 4: Post operative symptoms**

**4(a): With Implant: cases at**

Symptoms	3 <sup>rd</sup> day	1 <sup>st</sup> week	4 <sup>th</sup> week	6 <sup>th</sup> months
Discomfort	24 (100%)	18 (75%)	2 (8.3%)	2 (8.3%)
Discharge	24 (100%)	21 (87.5%)	-	5 (20.8%)
Pain	24 (100%)	6 (25%)	-	-

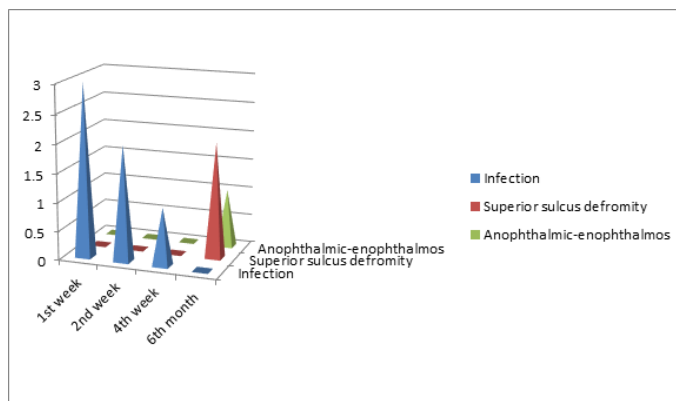
**4(b): Without Implant: cases at**

Symptoms	3 <sup>rd</sup> day	1 <sup>st</sup> week	4 <sup>th</sup> week	6 <sup>th</sup> months
Discomfort	16 (100%)	10 (62.5%)	-	-
Discharge	16 (100%)	6 (37.5%)	2 (12.5%)	4 (25%)

Pain	16 (100%)	4 (25%)	-	-
------	-----------	---------	---	---

**Table 5: Socket Complications**  
**5(a) With Implant: cases at**

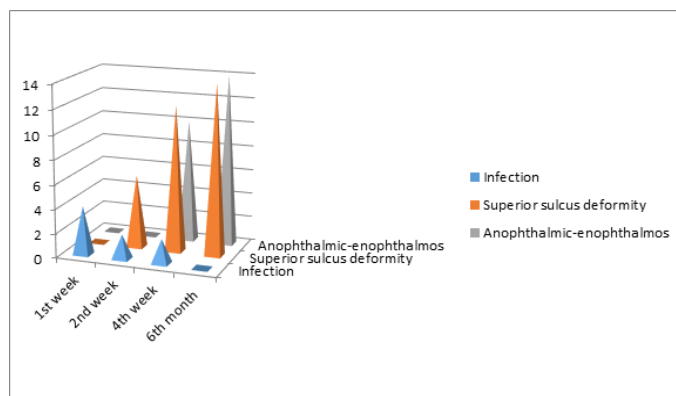
Complication	1 <sup>st</sup> week	2 <sup>nd</sup> week	4 <sup>th</sup> week	6 <sup>th</sup> month
Infection	3 (12.5%)	2 (8.3%)	1(4.7%)	-
Superior sulcus deformity	-	-	-	2 (8.3%)
Anophthalmic-enophthalmos	-	-	-	1 (4.1%)



**Fig. 1: Socket complications with implant group**

**5(b) Without Implant: cases at**

Complications	1 <sup>st</sup> week	2 <sup>nd</sup> week	4 <sup>th</sup> week	6 <sup>th</sup> month
Infection	4 (25%)	2 (12.5%)	2 (12.5%)	-
Superior sulcus deformity	-	6 (37.5%)	12(75%)	14 (87.5%)
Anophthalmic-enophthalmos	-	-	10 (2.5%)	14 (87.5%)



**Fig. 2: Socket complications in patients without implant**

**Table:6-Lid Complications**  
**6(a) With Implant: cases at:**

Complications	3 <sup>rd</sup> day	1 <sup>st</sup> week	4 <sup>th</sup> week	6 <sup>th</sup> month
Lid swelling	22 (91.6%)	5 (20.8%)	-	-
Ptosis	-	-	1 (4.1%)	2 (8.3%)
Lower lid laxity	-	-	3 (12.5%)	1(4.1%)
Entropion	-	-	-	-
Ectropion	-	-	-	1 (4.1%)

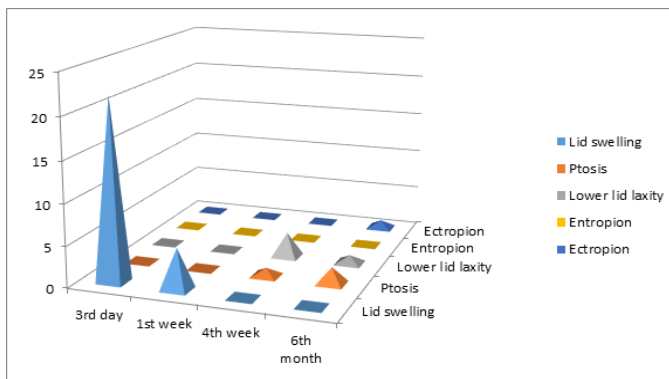


Fig. 3: Lid complications in patient with implant

6(b) Without Implant: cases at:

Complications	3 <sup>rd</sup> day	1 <sup>st</sup> week	4 <sup>th</sup> week	6 <sup>th</sup> month
Lid swelling	16 (100%)	4 (25%)	-	-
Ptosis	-	4 (25%)	6 (37.5%)	14 (87.5%)
Lower lid laxity	-	5 (31.2%)	6 (37.5%)	15 (93.7%)
Entropion	-	-	3 (18.7%)	5 (31.2%)
Ectropion	-	-	2 (12.5%)	7 (43.7%)

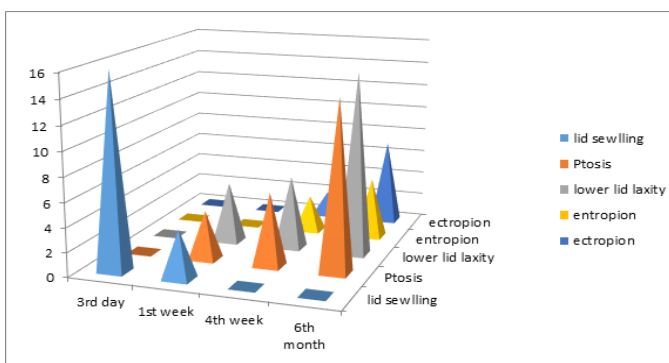


Fig. 4: Lid complications in patient without implant

Table: 7-Conjunctival Complications

7(a) With Implant: cases at:

Complications	3 <sup>rd</sup> day	1 <sup>st</sup> week	4 <sup>th</sup> week	6 <sup>th</sup> month
Congestion	24 (100%)	14 (58.3%)	2 (8.3%)	-
Chemosis	20 (83.3%)	6 (25%)	-	-
Dehiscence	-	-	4 (16.6%)	-
Giant papillary conjunctivitis	-	-	-	3 (12.5%)

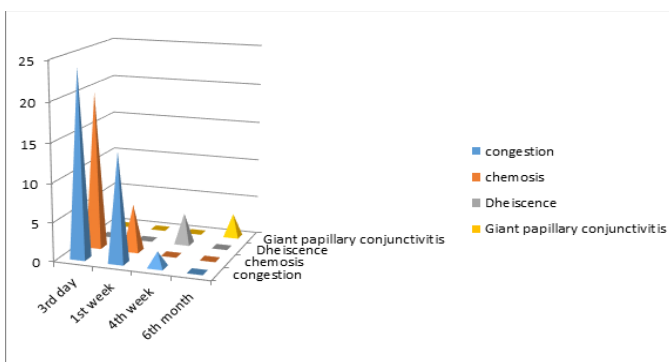
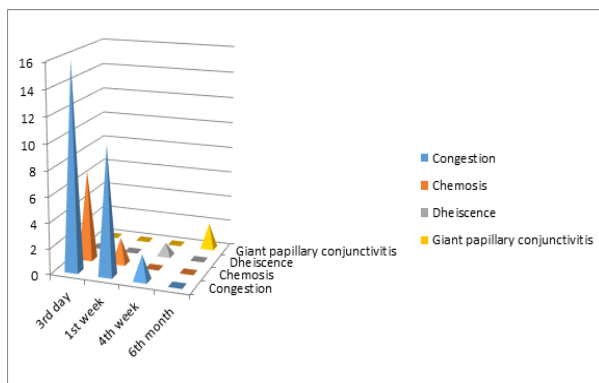


Fig. 5: Conjunctival complications in patient with implant

**7(b) Without Implant: cases at:**

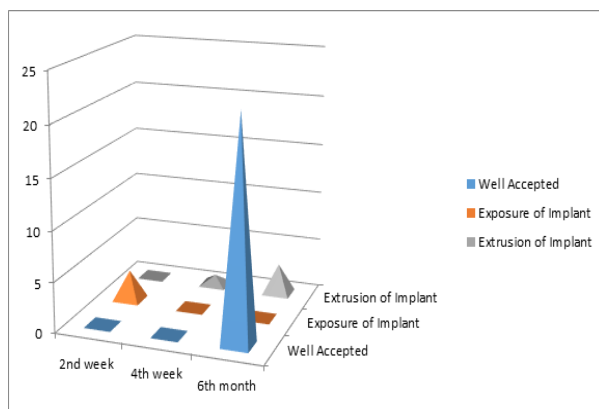
Complications	3 <sup>rd</sup> day	1 <sup>st</sup> week	4 <sup>th</sup> week	6 <sup>th</sup> month
Congestion	16 (100%)	10 (62.5%)	2 (12.5%)	-
Chemosis	7 (43.7%)	2 (12.5%)	-	-
Dehiscence	-	-	1 (6.25%)	-
Giant papillary conjunctivitis	-	-	-	2 (12.5%)



**Fig. 6: Conjunctival complications in patient without implant**

**Table 8: Acceptance of implant: cases at**

	2 <sup>nd</sup> week	4 <sup>th</sup> week	6 <sup>th</sup> month
Well accepted	-	-	22 (83.3%)
Exposure of implant	3 (12.5%)	-	-
Extrusion of implant	-	1 (4.1%)	-



**Fig. 7: Acceptance of implant**

In our study the maximum number of patients undergone evisceration surgery belongs to age group of 40-60 years, most of them were male 22(55%), while female figure is 18 (45%). In terms of pathology the most common indication of evisceration surgery is panophthalmitis 32(80%). Total number of patient in which implant was placed were 24 (60%), while 16 (40%) were operated without placement of the implant. Discomfort, discharge, & pain is the most frequent early symptom, faced by 100% patient, in both the groups. Socket complication i.e. superior sulcus

deformity & anophthalmic-enophthalmos is very common in patient without implant which is 14(87.5%) each at the end of 6<sup>th</sup> month, while in patient with implant it is only 2(8.3%) & 1(4.1%) respectively. At the end of 6<sup>th</sup> month Ptosis 14(87.5%), lower lid laxity 15 (93.7%), ectropion 7(43.5%) & entropion 5(31.2%) is more frequent in patient without implant group, as compared to patient with implant i.e. ptosis 2 (8.3%), lower lid laxity 1(4.1%), ectropion 1(4.1%) & entropion in none. Acceptance of the implant is excellent in 22 out of 24 patient (83.3%) cases, while exposure in 2<sup>nd</sup> week is encountered in 3 (12.5%) & extrusion<sup>(14)</sup> in 1 (4.1%) at the end of 4<sup>th</sup> week.

**Conclusion**

The socket related complications like superior sulcus deformity<sup>(9)</sup> and anophthalmic-enophthalmos<sup>(10)</sup> following evisceration were minimum in patient with implant placement. This results in better cosmetic appearance<sup>(11)</sup> when prosthetic eye is placed. Incidence of secondary changes in the lids like ptosis, entropion, ectropion & lower lid laxity is very little in cases with implant placement as compared to those without implant. In majority of the patients, the implant is well taken up. In terms of amplitude<sup>(12)</sup> and range of movements<sup>(13)</sup> of prosthetic eye in cases of evisceration with implant placement is much better in all the four gazes as compared to those without implant placement. To achieve near natural cosmetic appearance in terms of “eye movement (prosthetic eye)”,<sup>(15)</sup> spherical implant placement is the modality of choice.

**References**

1. Enucleation, Evisceration and Exenteration: The care of socket. The requisites in ophthalmology: oculoplastic surgery 2002;44:277-301.
2. Iliff CE, Iliff WJ, Iliff NT: Evisceration and Enucleation, Oculoplastic Surgery. Philadelphia, Saunders 2003;78:742.
3. Jordan DR, Parisi J: The sclera file technique for secondary orbital implantation surgery. University of Ottawa Eye Institute, Ont;2000;18(5):336-41.
4. Bite U, Jackson IT, Forbes GS et al: Orbital volume measurements in enophthalmos using three dimensional CT imaging. Plast Reconstr Surg. 1985;75:502-8.
5. Camezind P, Robert PY and Adenis JP: Post-enucleation or evisceration socket syndrome. Operative techniques in oculoplastic, Orbital and Reconstructive Surgery. 2001, vol.4,No.1pp.48-51.
6. De Voe AG: Experiences with the surgery of anophthalmic orbit. Am J Ophthalmol 1998;28:1346-51.
7. Bhattacharjee Kasturi, Bhattacharjee Harsha, Das Jayanta: Comparative analysis between hydroxyapatite

- and silicon implants in primary anophthalmic socket. AIOC proceedings. 2002.
8. Bullock JD. Dermis fat graft in socket reconstruction. Theoretical and experimental considerations. *Ophthalmology* 1984;91:204-6.
  9. Leone CR Jr: Correction of superior sulcus defects after evisceration. *Adv in Ophthalmic Plast Reconstr Surg.* 1990;8:209-13.
  10. Hill JC, Savar D: Silicon augmentation of enophthalmic socket. A 14 years review. *Can J Ophthalmol.*1978;13(4):294-8.
  11. Smerdon DL, Sutton GA: Analysis of the factors involved in cosmetic failure following excision of the eye. *Br J Ophthalmol.*1988;72:768-73.
  12. Thomas Colen P, Paridaens A Dion, Lemij G Hans et al: Comparison of artificial eye amplitudes with acrylic and hydroxyapatite spherical evisceration implants. *American Academy of Ophthalmology.* 2000;107(10).
  13. Shkromida MI: The results of cosmetic prosthesis in patients in relation to the method of formation of a movable base for the prosthesis following removal of the eyeball. *Ophthalmol Zh.* 1989;(6):357-9.
  14. Shore JW, Dieckert JP, Levine MR: Delayed primary wound closure. Used to prevent implant extrusion following evisceration for endophthalmitis. *Arch Ophthalmol.*1998;106(9):1303-8.
  15. Robinson DA: A method of measuring eye movement using a scleral search coil in a magnetic field. *IEEE Trans Biomed Eng* 1963;10:137-45.