

## Limited resection for limbal dysplasia by conjunctivectomy and medial canthectomy for limbal carcinoma involving medial canthus - case series

Ram Lal Sharma<sup>1,\*</sup>, Kalpana Sharma<sup>2</sup>, Preeti Chopra<sup>3</sup>

<sup>1</sup>Professor, <sup>2</sup>Senior Resident, <sup>3</sup>Junior Resident, Dept. of Ophthalmology, Indira Gandhi Medical College, Shimla, Himachal Pradesh

**\*Corresponding Author:**  
Email: rls\_10@rediffmail.com

### Abstract

Limbal dysplasia refers to the abnormal maturation of the epithelium as it differentiates from the basal to superficial layers. This is premalignant condition that needs wide excision and close follow up. Squamous cell carcinoma of the conjunctiva arises at the epithelial transition zone of limbus which tends to involve cornea or adjacent bulbar conjunctiva. Management of these cases varies from topical chemotherapy, surgical excision, cryotherapy or their combination in small lesions to enucleation or exenteration in large or invasive lesions. We report 2 cases one with severe limbal dysplasia removed by localised conjunctivectomy and other case of invasive limbal squamous cell carcinoma involving both lids on medial side, where limited resection was performed by enucleation and medial canthectomy instead of exenteration. So by limited resection one can avoid a radical surgery in cases where extensive infiltration of lid is not present.

### Introduction

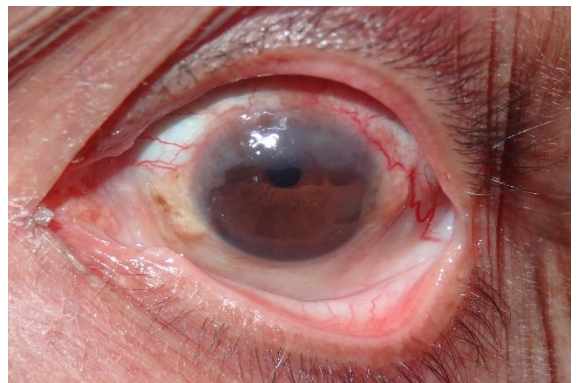
Conjunctival intraepithelial neoplasia (CIN) is non-invasive in which the basement membrane remains intact and the underlying substantia propria is spared. Corneal epithelial dysmaturation, corneal epithelial dysplasia, and corneal intraepithelial neoplasia refer to neoplastic lesions of the cornea in which the conjunctival presence is minimal and the basement membrane of cornea remains intact. Carcinoma in situ is a full thickness replacement of epithelium by frankly malignant cells. Squamous cell carcinoma (SCC) describes a malignant lesion in which the dysplastic epithelial cells have penetrated the corneal basement membrane, gaining metastatic potential.<sup>(1,2)</sup>

Squamous cell carcinomas of the conjunctiva are mostly limbal or less often conjunctival. It may be papillary carcinoma of the limbus, nodular carcinoma of the bulbar and the palpebral conjunctiva, and diffuse carcinoma of the palpebral conjunctiva.<sup>(3)</sup> Depending on the lesion and histopathologic findings, treatment ranges from topical chemotherapy or excision alone for smaller lesions versus a combination of surgical excision, cryotherapy, and chemotherapy, and even enucleation and exenteration for larger or invasive lesions. We report a case series of two patients, the first one with severe limbal dysplasia removed by localised conjunctivectomy and other with limbal squamous cell carcinoma managed with limited resection for limbal carcinoma conjunctivectomy and medial canthectomy without any recurrences in both cases. Thus local excision should be sufficient in the most of these cases and that radical surgery like exenteration is necessary only if deep infiltration of lids occur.

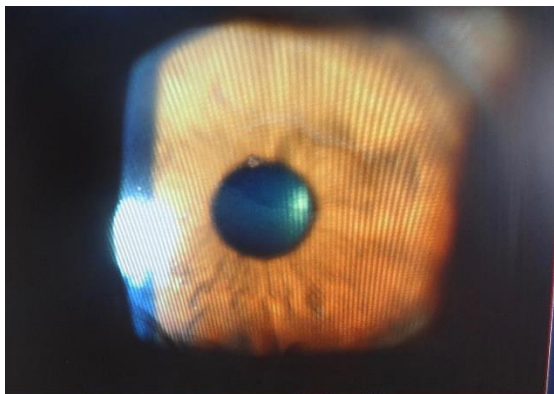
### Case 1

A 70-year-old male presented with a limbal mass following cataract surgery, which was involving right

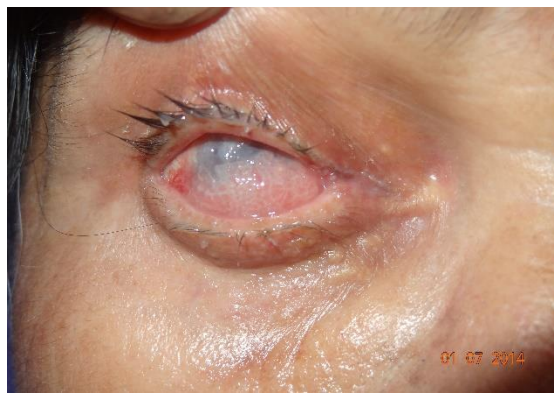cornea from the nasal side hampering vision(Fig. 1). The patients was planned for lamellar keratectomy to remove the invading mass. An incision was made in clear cornea just beyond the farthest area of tumour invasion. A plane between stromal lamellar found in the upper third of the cornea and the dissection was continued beneath the invading tumour till the limbus. The mass was excised from episcleral tissue at the limbus along with localised conjunctivectomy and raw area covered with adjacent healthy conjunctiva(Fig. 2). Histopathology of the mass showed limbal dysplasia. Postoperatively visual acuity improved and follow up after 6 months did not show any recurrence.



**Fig. 1: Limbal dysplasia involving upper half of cornea**



**Fig. 2: Postoperative appearance after superficial keratectomy and conjunctivectomy**

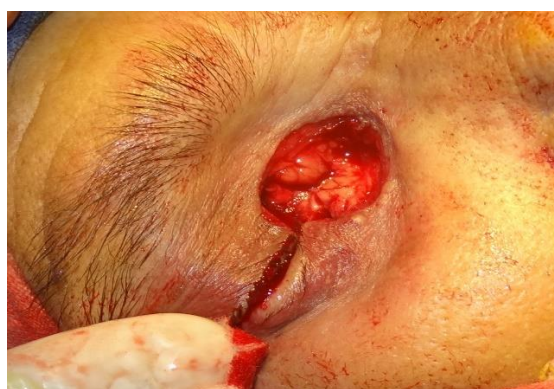

**Fig. 3: Squamous cell carcinoma involving medial canthus**

### Case 2

A 65 years old female patient presented with the chief complaints of redness and irritation from right eye 2 years back. On examination patient has fibro-vascular growth at the medial limbus encroaching over the cornea (Fig. 3). Patient was diagnosed local limbal stem cell deficiency and was put on medical treatment. After 6 months the fleshy mass appeared at the base limbus, so an excision biopsy of the mass was done. Histopathology of the mass showed epithelial dysplasia and patient was kept on close follow up. Patient presented after 6 months again with similar mass but refused any surgical intervention. The mass further increased in size in next one year, which became multi-lobulated encroaching on 2/3<sup>rd</sup> of cornea medially and was adherent to the medial rectus and both eyelids on medial side. There was h/o dull pain and mucous discharge from the eye. Visual acuity of the patient was 6/60 in this eye with cataractous changes in the beginning but later it was light perception. Cornea was visible in the upper part but no further detail of anterior segment was visible. The lid margin and fornix were free from the growth. Now an impression smear and edge biopsy was allowed by the patient, which showed moderately differentiated squamous cell carcinoma.

Clinically there was no regional metastasis to the lymph nodes. Investigations were done for any evidence of systemic metastasis or visceral tumour which were normal. The patient was planned for excision of the eyeball due to rectus muscle involvement along with partial lid excision with reconstruction of medial canthus in single stage. During surgery eye ball was adhered to the medial canthus without any cleavage so partial excision of both the eyelids were done on medial canthus (medial canthectomy) Fig. 4, 5. Post operatively patient was given local radiotherapy.



**Fig. 4: Intraoperative appearance after enucleation and medial canthectomy**

**Fig. 5: 1st postoperative day appearance of patient after primary reconstruction**

### Discussion

The incidence of ocular surface squamous neoplasia varies between 0.13 to 3.5/100000. It is predominantly seen in dark skinned Caucasians, the age of onset being significantly higher in areas closer to the equator. The average age of occurrence has been noted to be 60 years, ranging from 20 to 88 years. The average age of incidence of carcinoma in situ lesions is 5-9 years lower than invasive ocular surface squamous neoplasia (OSSN). This difference represents the time taken for progression from intraepithelial neoplasm to invasive carcinoma.<sup>(4)</sup>

Squamous cell carcinomas of the conjunctiva usually arise at the limbus and spread to the cornea and adjacent bulbar conjunctiva (Ash, 1950).<sup>(5)</sup> As carcinomas tend to arise at sites of epithelial transition it is consistent for the limbus to be the place of predilection. Conjunctival SCC occurs in sun damaged ocular surface, usually at the limbus in elderly men with fair skin, history of actinic skin lesions, Xeroderma Pigmentosum, chronic infection by HPV (human papilloma virus), HIV, or trachoma, vitamin A deficiency, Immunosuppression as

predisposing risk factors. Recurrence of OSSN is common with significantly increased risk for older patients, lesions of large diameter and positive surgical margins.<sup>(6)</sup>

Most limbal carcinomas are removed when they are relatively small and have not invaded cornea. It is rare to see large invasive tumours of the cornea, and this occurs only if conjunctival tumour extending from the limbus is not excised for long, slowly it may involve eyelids when it requires extensive surgery.

Zimmerman (1965)<sup>(7)</sup> has stated that the eye had been enucleated because the limbal tumour seemed to have involved so much of the cornea or because it had grown so large. He believed that the eye might well have been saved by a courageous surgeon, because often in the case of the spreading 'in situ' cancers that involve much of the corneal surface the opacification, vascularisation, and pannus formation that are so impressive clinically are found histologically to be very superficial. So an extensive superficial keratectomy would have sufficed in a number of cases that were treated by enucleation. We had carried out limited resection of tumour in these patients with invasive carcinomas of their corneas, where a conservative approach was used. The excision of dysplastic tissue from the invaded cornea along with local conjunctivectomy at the limbus. This not only removed the tumour but also improved patient hampered vision.

Bowman's membrane offers considerable resistance to the deep invasion of the tumour, and even tumours involving the entire corneal surface may not have penetrated into stroma. This feature is important from a therapeutic aspect, as even very large tumours invading large areas of cornea may be adequately removed by superficial keratectomy, as was indicated in this case with severe limbal dysplasia. Ash and Wilder (1942), in discussing limbal tumours came to the conclusion that local excision will suffice in the majority of cases and that enucleation is necessary only if recurrences are persistent.<sup>(8)</sup>

Sever limbal dysplasia can be removed by superficial keratectomy along with localised conjunctivectomy effectively. Extension of a limbal carcinoma into the eye is an extremely rare occurrence and cornea is resistant to deep spread of the tumour. But once the lids are invaded then exenteration of orbit is advisable. In our 2nd case, instead of exenteration we planned enucleation due to the muscle invasion in blind eye and limited resection of both eyelids hence medial canthectomy along with post operative radiotherapy. Patient tolerated both procedure well and was asymptomatic during one year follow up. So by limited resection one can avoid a radical surgery in cases where extensive infiltration of lid is not present.

## References

1. Krachmer JH, Mannis MJ, Holland EJ. Cornea: Fundamentals, diagnosis and management. 2005.
2. Reidy JJ, Bouchard CS, Florakis GJ, et al. Basic and Clinical Science Course, 2011-2012. 2011:226-233.
3. Blodi, F.C. Doc Ophthalmol (1973) 34: 93. doi:10.1007/BF00151799.

4. Lee GA, Hirst LW: Incidence of ocular surface epithelial dysplasia in metropolitan Brisbane. A 10 year survey. Arch Ophthalmol 1992;110:525-7.
5. Ash, J. E. (1950). Epibulbar tumors. American, Journal of Ophthalmology, 33, 1203-1219.
6. McKelvie PA, Daniell M, McNab A, et al Squamous cell carcinoma of the conjunctiva: a series of 26 cases *British Journal of Ophthalmology* 2002;86:168-173.
7. Zimmerman, LE. Squamous cell carcinoma and related lesions of the bulbar conjunctiva. In: Boniuk M (Ed.) Ocular and Adnexal Tumors. CV Mosby, St Louis; 1964:49-74.
8. Ash, J. E., and Wilder, H. C. (1942). Epithelial tumors of the limbus. American Journal of Ophthalmology, 25,926-932.