

## Retroperitoneal Leiomyosarcoma metastatic to the orbit: Report of a case and review of Literature

Smriti Bansal<sup>1</sup>, Sima Das<sup>2\*</sup>, Kaustabh Mulay<sup>3</sup>, Arpan Gandhi<sup>4</sup>

<sup>1,2</sup>Oculoplasty & Ocular Oncology Services, <sup>4</sup>Ocular Pathology Services, Dr. Shroff's Charity Eye Hospital, New Delhi, <sup>3</sup>National Reporting Centre for Ophthalmic Pathology, Centre for Sight, Hyderabad

**\*Corresponding Author:**

Email: [contactsima@gmail.com](mailto:contactsima@gmail.com)

### Abstract

Leiomyosarcoma is a rare soft tissue tumor arising from mesenchymal smooth muscle cells. Orbital involvement can be primary or metastatic from other part of the body. We present a case of a 45 year old female with retroperitoneal leiomyosarcoma with right orbital metastasis.

**Keywords:** Leiomyosarcoma, Metastatic, Orbit, Retroperitoneum

### Introduction

Leiomyosarcoma is a common soft tissue tumor arising from smooth muscle cells of mesenchymal origin. It commonly affects female genital tract and limbs, gastrointestinal tract, trunk and retroperitoneum.<sup>(1)</sup> Ocular involvement is uncommon mainly affecting orbit, conjunctiva and uvea.<sup>(2,3)</sup> Orbital involvement can be primary, secondary due to extension from paranasal sinuses or metastatic. The clinical features of orbital tumor have been reported rarely in the literature. We report a case of retroperitoneal leiomyosarcoma metastatic to the orbit and review the published literature on the clinical features of this rare orbital tumor.

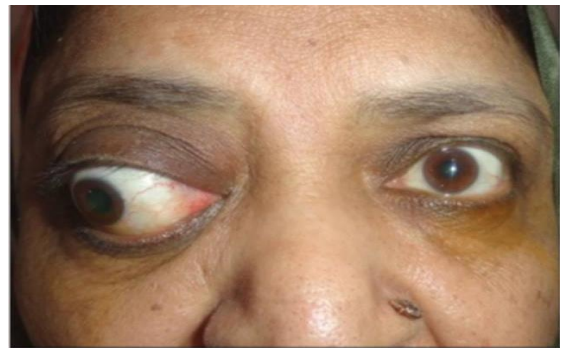### Case Report

A 45 year old lady presented with complaint of bulging of right eye (RE) along with ocular pain and blurring of vision for 2 months (Fig. 1). She underwent excision of a retroperitoneal mass 2 years back elsewhere. Histopathology of the excised mass showed low to medium grade leiomyosarcoma. She was lost to follow up after excision and presented to the oncologist one year post excision with complaint of difficulty in breathing. Positron emission tomography scan revealed metastasis to lungs, ribs, lumbar vertebrae and hilar lymph nodes and she was started on systemic chemotherapy (vincristine, cyclophosphamide and doxorubicin) for the same.

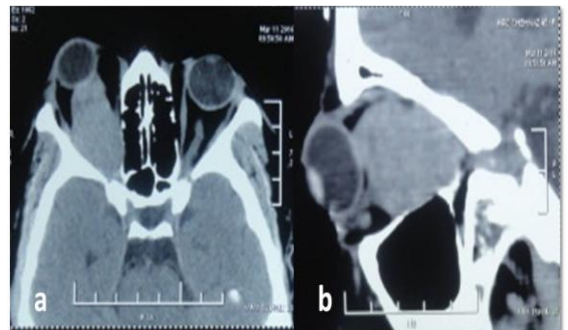On ocular examination, her best corrected visual acuity was perception of light in RE and 6/6 in left eye (LE). RE had 10mm proptosis with extraocular motility restriction. Anterior segment of both eyes were normal. Fundus examination of RE showed choroidal folds in superotemporal quadrant and optic disc edema. A firm, non tender mass was palpable in temporal quadrant of right orbit. Computed tomography scan showed a well defined isodense mass in right intraconal space, lateral to optic nerve (Fig. 2). Incisional biopsy was performed from the orbital mass. Histopathological examination showed a tumor composed of interlacing fascicles of spindle-shaped cells having moderate, pale eosinophilic cytoplasm and fusiform vesicular nuclei having blunted ends with coarse chromatin and prominent nucleoli(Fig.

3). Nuclear atypia was moderate and abnormal mitoses were present. The tumor cells were positive for alpha - smooth muscle actin and vimentin. S100, HMB45, CD34, myogenin and pan-cytokeratin were negative in the tumor cells. A diagnosis of leiomyosarcoma was confirmed.

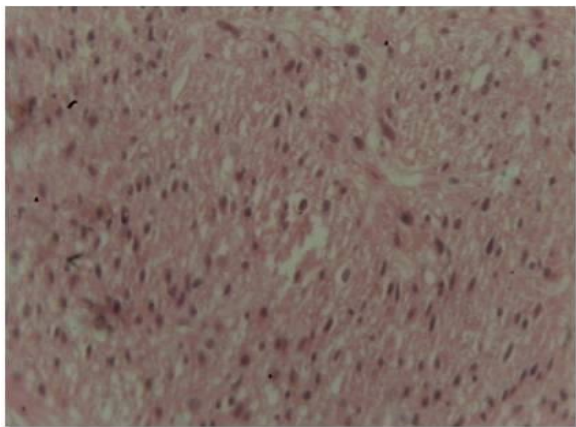
Patient refused any major surgical intervention for removal of the tumor and was continued on palliative treatment. A permanent tarsorrhaphy was done to prevent exposure keratopathy. Patient was alive with disease at last follow up.



**Fig. 1: Right eye proptosis and downward displacement of the globe in an elderly female with metastatic orbital leiomyosarcoma**



**Fig. 2: Axial(Fig. 2a) and sagittal(Fig. 2b) CT scans showing well defined isodense mass in the intraconal space of the right orbit**



**Fig. 3: Hematoxylin and Eosin stained slides of the incision biopsy specimen(40x magnification) showing cellular spindle cell tumour with a palisading pattern. The spindle cells have elongated pleomorphic nuclei with moderate eosinophilic cytoplasm elongated cytoplasmic processes. Few mitotic figures are also seen**

### Discussion

Soft tissue sarcomas are rare tumor accounting for 0.7% of malignancies of which 5-10% are leiomyosarcoma. It commonly affects female genital tract (26%), limbs (16%), gastrointestinal tract (14%), trunk (13%) and retroperitoneum (6%).<sup>(1)</sup> Orbital involvement can be primary or secondary extension from surrounding structures or as part of distant metastasis. On doing a Medline literature search in English language, 31 reported cases of leiomyosarcoma were identified, out of which 13 were primary, 5 developed as second malignancy in patients who have received prior radiation to orbit, 5 were secondary orbital extension from adjacent paranasal sinus and 6 were orbital metastasis from a distant primary site(Table 1).<sup>(4-14)</sup>

**Table 1: Demographic and clinical details of the primary, secondary and metastatic orbital leiomyosarcoma**

No.	Authors	Age / sex	Primary or secondary/metastatic	Primary site(in case of secondary/metastasis)	Presenting complaint	Eye	Location in the orbit	Duration of symptom (m)	Imaging	Treatment	Adjunctive treatment	Histopathology	Immunohistochemistry	Outcome
1	Terry et al 1934 <sup>(6)</sup>	51/ F	Primary	Orbit (recurrence)	Upper lid mass	Right	Superior	2		Excision	Exenteration with Radium implant	Cells with rod shaped nuclei	Not done	Died after 2 months
2	Ingalls et al 1953 <sup>(9)</sup>	34/ F	Primary		Proptosis	Left	Superior orbital fissure	24		Incision biopsy				Patient refused treatment
3	Kojima et al 1972 <sup>(6)</sup>	48/ F	Primary	Orbit	Proptosis	Right	Medial							
4	Tsuchiya et al 1972 <sup>(6)</sup>	68/ F	Primary	Orbit	Proptosis		Inferotemporal	1.5		Excision				
5	Jacobeic et al 1975 <sup>(6)</sup>	58/ F	Primary	Orbit	Proptosis	Right	Medial orbit	15		Excision	Patient Refused			Died after 15 months
6	Jacobeic et al 1975 <sup>(6)</sup>	59/ F	Primary	Orbit	Proptosis	Left	Inferolateral orbit	18		Excision	Exenteration			Died after 1 yr

7	Wojno et al 1983 <sup>(6)</sup>	36/M	Primary	Orbit	Proptosis	Right	Inferomedial orbit	6	Well defined homogenous mass with no bony erosion	Excision		Spindle shaped cells with cigar shaped nuclei		Alive at last follow up
8	Meekins et al 1988 <sup>(6)</sup>	82/F	Primary	Orbit	Proptosis	Left	Lateral	1.5	Well defined homogenous mass	Excision	Radiotherapy	Spindle shaped cells with elongated nuclei		Died after 5 months due to cerebrovascular accident
9	Das et al 1992 <sup>(4)</sup>	12/M	Primary	Orbit	Proptosis	Right	6			Excision	Chemotherapy	Spindle shaped cells with cigar shaped nuclei		Alive after 5 yrs of excision
10	Weichens et al 1999 <sup>(5)</sup>	84/F	Primary	Orbit	Proptosis	Right	Inferior		Ill defined heterogenous mass with no bony erosion	Incision biopsy	Exenteration	Spindle shaped cells	Positive for desmin and smooth muscle actin	Died after 14 months
11	Lawrence et al 2003 <sup>(7)</sup>	56/F	Primary	Orbit	Diplopia + proptosis	Left	Medial	10	Well defined homogenous mass with no bony erosion	Excision	Chemotherapy + radiotherapy	Spindle shaped cells arranged in fascicles	Antismooth muscle actin and desmin positive and negative for S-100 and CD 34	Alive after 4 months of last follow up
12	Lin et al 2005 <sup>(7)</sup>	84/F	Primary	Orbit	Upper lid nodule	Right	Medial orbit	1	Well defined homogenous mass	Excision		Large atypical cigar shaped nuclei	Antismooth muscle actin positive, negative for 100 and CD34	Alive after 3 yrs
13	Yeniad et al 2009 <sup>(7)</sup>	79/F	Primary	Orbit	Proptosis	Left	Superotemporal orbit	6	Well defined heterogenous mass	Excision		Spindle shaped infiltration with multilobulated pattern	Antismooth muscle actin positive Negative for CD 34, CD 68 and desmin	Alive after 12 months
14	Folberg et al <sup>(8)</sup>	29/M	Primary	Orbit	Proptosis	Right	Medial	4	Well defined homogenous mass	Excision		Spindle shaped cells with cigar shaped nuclei	Stained red with masson's trichome	Alive at last follow up

15	Folberg et al <sup>(8)</sup>	26/M	Primary	Orbit	Mass in inferior part of eye	Right		1	Not seen on CT	Exenteration		Spindle shaped cells with cigar shaped nuclei	Stained red with masson's trichome	
16	Font et al <sup>(5)</sup>	31/F	Primary	Orbit	Subcutaneous mass			30		Excision				
17	Perez et al <sup>(16)</sup>	23/M	Primary	Orbit	Lower lid mass	Right	Infeolateral		Well defined heterogenous mass	Excision	Plaque radiotherapy			Alive after 30 months
18	Klippelstein et al <sup>(5)</sup>	29/M			Orbital mass			28		Exenteration	Radiotherapy			
19	Gardner et al 1917 <sup>(9)</sup>	55/F	Metastatic	Uterus	Proptosis	Right	Posterior orbit							Died after 4 years
20	Kaltrieder et al 1987 <sup>(9)</sup>	43/F	Metastatic	Subcutaneous nodule over abdomen	Blurring of vision and proptosis	Right	Superomedial orbit	4	Well defined heterogenous mass with erosion of medial wall	Excision	Chemotherapy	Spindle shaped cells with elongated nuclei		Alive after 6 months of follow up
21	Minkowitz et al 1990 <sup>(11)</sup>	71/M	Metastatic	Skin abdomen and scalp	Upper lid mass	Left	Superolateral orbit	5	Well defined mass	Excision	Chemotherapy	Elongated epitheloid cells with prominent nuclei	Positive for vimentin and actin, neagtive for S-100 and keratin	Died after 1 yr
22	Voros et al 2005 <sup>(10)</sup>	74/M	Metastasis	Left leg	Diplopia +proptosis	Left	Superomedially	3	Well defined homogenous mass	Excision	Refused	Spindle shaped cells arranged in fascicular pattern	Positive for antismmoth muscle actin and negative for desmin and S-100	Alive after 6 months of follow up
23	Grant et al 2007 <sup>(12)</sup>	55/F	Metastatic	Uterus	Proptosis + diplopia	Right	Superomedial orbit	0.5	Well defined homogenous mass in greater wing of sphenoid	Exenteration	Radiotherapy	Poorly differentiated Leiomyosarcoma		Alive after 10 months of last surgery

24	Sophie et al <sup>(13)</sup>		Metastatic	Spermatic cord	Proptosis	Left	Intraconal inferior to optic nerve	1	Well defined homogenous mass	orbitotomy	chemotherapy	Bundles of fascicles containing spindle shaped cells	Positive for antismooth muscle actin and vimentin, negative for S-100, CD-34 and CD-64	Alive at last follow up
25	Chen et al 2012 <sup>(5)</sup>		Metastatic	Retroperitoneal mass	Proptosis	Left	Inferomedial orbit	4	Well defined homogenous mass	orbitotomy	Chemotherapy+radiotherapy	Spindle shaped cells woven together in storiform pattern	Positive for antismooth muscle actin and vimentin	Alive after 12 months of treatment
26	Kim et al 2016 <sup>(10)</sup>	57/F	Metastatic	Uterus	Proptosis	Left	Diffuse going till apex	2	Heterogeneous mass involving whole orbit with intracranial extension	Patient refused treatment				Died after 2 months
27	Fu and Perzin et al <sup>(14)</sup>	37/F	Secondary	Maxillary bone		Left	Medial	6		Excision	Chemotherapy			
28	Fu and Perzin et al <sup>(14)</sup>	56/M	Secondary	Ethmoid + sphenoid sinus	Displacement of globe superiorly	Left	Inferior			Excision	Radiotherapy			
29	Fu and Perzin et al <sup>(14)</sup>	18/F	Secondary	Ethmoid + Maxillary + frontal sinus	Proptosis	Left	Superomedial	3		Excision	Radiotherapy			Alive after 1 year
30	Fu and Perzin et al <sup>(14)</sup>	36/M	Secondary	Posterior nasal cavity	Proptosis	Right	Inferior			Excision	Radiotherapy			
31	Jacobeic et al 1978 <sup>(14)</sup>	39/M	Secondary	Maxillary sinus	Proptosis	Left	Floor and medial wall	2		Chemotherapy	Radiotherapy	Tumor cells with cigar shaped nuclei		Alive after 9 months of follow up

Leiomyosarcoma affecting orbit as primary site was first reported by Terry as an upper eyelid mass.<sup>(6)</sup> Primary orbital leiomyosarcoma affect elderly females with average age at presentation of 58 years (ranging from 34-84 years). Proptosis is the most common presentation as seen in 11 cases whereas 2 patients presented with an upper eyelid mass. Superior and inferior quadrant of the orbit is the common location. Imaging shows a well defined isodense mass with no bony erosion. Complete surgical excision remains the treatment of choice. Recurrence rate of 30% has been reported following excision. Though the tumor appears encapsulated on imaging, it can be friable with extension into the surrounding orbital tissues making complete excision difficult and accounting for the high recurrence rate following excision. Recurrent tumors tend to be more aggressive. Adjuvant chemotherapy has been found beneficial in improving survival in recurrent tumors.

Orbital leiomyosarcoma can also be seen as second malignant neoplasm in germline retinoblastoma survivors who had received orbital irradiation in childhood. In all 5 reported cases, leiomyosarcoma developed within 25 years of receiving radiation.<sup>(8,15)</sup> Complete excision is the preferred treatment modality in these patients.

Metastatic and secondary orbital leiomyosarcoma was first described by Gardner in 1917.<sup>(9)</sup> Orbital involvement is seen late in the disease course and in about 50% of patients the tumor had already metastasized to lungs and liver when orbital involvement was detected. Orbital involvement was secondary to paranasal sinus tumor in 5 cases, mainly from ethmoid and maxillary sinus. Metastatic orbital leiomyosarcoma is also a tumor of the elderly with a mean age at presentation of 52 years (18-78 years). Most orbital involvement is detected within 4 years of the diagnosis of the primary tumor, however delayed involvement of the orbit 20 years after the diagnosis of primary tumor has also been reported. Common primary site are uterus, subcutaneous tissues of buttock, lower limb, abdominal skin, spermatic cord and retroperitoneum. Unlike primary orbital leiomyosarcoma, metastatic leiomyosarcoma can have variable imaging findings ranging from well defined to illdefined mass with or without bony erosion. Complete excision remains the treatment of choice. Secondary tumor extending from paranasal sinus carries a poor prognosis as recurrence was noted in all patients following excision. All these patients received adjuvant treatment in form of either chemotherapy or radiotherapy.

On histopathology the tumor appears as spindle shaped cells arranged in a fascicular or storiform pattern with abundant red staining cytoplasm. On high power microscopy, these cells have an elongated cigar shaped nuclei with cellular atypia and mitotic figures. Immunohistochemistry shows positivity for anti-smooth muscle actin showing its origin from smooth muscle.

Chen et al have reported a case of metastatic orbital leiomyosarcoma from a retroperitoneal primary site in a 51 year old lady.<sup>(5)</sup> Orbital metastasis was detected 6 years after the excision of primary tumor and there was concurrent metastasis to liver, lungs and pancreas.

Complete excision of the orbital tumor was done and at 12 months of follow up patient was alive with no local recurrence. Our patient had a similar presentation with involvement of right orbit 3 years after excision of a retroperitoneal primary tumor and had concurrent metastasis to lungs, liver and hilar lymph nodes. To the best of our knowledge this is the second report of orbital metastasis of retroperitoneal leiomyosarcoma.

## References

1. Dennis N, Francis M, Lawrence G. National Cancer Intelligence Network. Soft Tissue Sarcoma Incidence and Survival Tumors Diagnosed in England between 1985 and 2009. London 2012: 11-5.
2. Nair AG, Kaliki S, Kamal S, Mishra DK, Vemugati GK. Conjunctival Leiomyosarcoma: A Report of Two Cases. *Orbit* 2015;34(5):274-8.
3. Feinstein E, Kaliki S, Shields CL, Ehya H, Shields JA .Choroidal metastasis from leiomyosarcoma in two cases. *Oman J Ophthalmol.* 2014 Jan;7(1):19-21.
4. Das Dk, Das J, Kumar D, Bhatt NC, Banot K, Natarajan R. Leiomyosarcoma of the orbit. *Diagnostic Cytopathology* 1992;8:609-13.
5. Chen J, Wei R, Ma X. Orbital metastasis of Retroperitoneal Leiomyosarcoma. *Medical Oncology* 2012;29:392-5.
6. Meekins BB, Dutton JJ, Proia AD. Primary Orbital Leiomyosarcoma. *Archives of Ophthalmology* 1988;106:82-86.
7. Yeniad B, Tuncer S, Peksayar G, Mete O, Minareci O. Primary Orbital Leiomyosarcoma. *Ophthalmic Plastic and Reconstructive Surgery* 2009;25(2):154-5.
8. Folberg R, Cleasby G, Flanagan JA, Spencer WH, Zimmerman LE. Orbital Leiomyosarcoma after Radiation Therapy for Bilateral Retinoblastoma. *Archives of Ophthalmology* 1983; Oct 101:1562-5.
9. Kaltreider SA, Destro M, Lemke BN. Leiomyosarcoma of the Orbit. *Ophthalmic Plastic and Reconstructive Surgery* 1987;3(1):35-41.
10. Kim YH, Park IK, Min GE, Jin KH, Shin JH. A Case of Orbital Metastasis of Uterine Leiomyosarcoma with Intracranial Extension Presenting With Proptosis. *Ophthalmol Plastic and Reconstructive Surg* 2016;32(3):e 51-52.
11. Minkowitz JB, Dickerson GR, Dallow RL, Albert DM. Leiomyosarcoma Metastatic to Orbit. *Archives of Ophthalmology* 1990;108:1525-26.
12. Grant W, Sanh H Hong. Leiomyosarcoma of the Uterus with Sphenoid Bone and Orbital Metastasis. *Ophthalmic Plastic and Reconstructive Surgery* 2007;23(5):428-30.
13. Bakri SJ, Krohel GB, Peters GB, Farber MG. Spermatic Cord Leiomyosarcoma metastatic to Orbit. *American Journal of Ophthalmology* 2003;136:213-5.
14. Fu YS, Perzin KH. Nonepithelial tumors of nasal cavity, paranasal sinuses and nasopharynx: a clinicopathologic study. *Cancer* 1975;35:1300-8.
15. Perez NP, Zamora FM, Miguelez CG. Adjuvant pulse dose rate brachytherapy in a secondary leiomyosarcoma of the orbit. *Canadian journal of ophthalmology* 2013;48(4):e65-7.