

Myoepithelioma of lacrimal gland: A rare entity

Dhaval Patel¹, Dipankar Das², Ganeshchandra Kuri³, Diva Kant Mishra^{4,*}, Prabhjot Kaur Multani⁵

^{1,4,5}Resident, ²Senior Consultant, Dept. of Ocular Oncology & Pathology, ³Senior Consultant, Dept. of Oculoplasty & Ocular Oncology, Sri Sankaradeva Nethralaya, Guwahati, Assam

***Corresponding Author:**

Email: divakant@gmail.com

Abstract

Myoepithelioma of lacrimal gland, an extremely rare monomorphic adenoma, has been reported only 7 times to the best of our knowledge. We report a case of 62 years old female who presented with painless proptosis of the left eye with restricted extraocular movements. MRI scan revealed a well- defined hypodense mass originating from the lacrimal gland. The lesion was excised in- toto following a planned anterior orbitotomy. Histopathology revealed spindle cell and round cell proliferation which was positive for actin, vimentin, cytokeratin and glial fibrillary acidic protein and negative for S100 and desmin on immunohistochemistry. Post- operative period was uneventful and there was no evidence of recurrence in three years until the last follow up.

Keywords: Immunohistochemistry, Lacrimal gland, Myoepithelioma, Spindle cell variant

Introduction

Myoepithelioma is a rare epithelial tumor, most frequently reported to affect salivary glands¹. To the best of our knowledge only seven cases of myoepithelioma of lacrimal gland, a very rare monomorphic adenoma, have been reported till date. Amongst the lacrimal gland tumors, Pleomorphic adenoma is most common neoplasm followed by adenocarcinoma, mucoepidermoid carcinoma and adenoid cystic carcinoma being less frequently arising neoplasms². Histologic characteristics of epithelial tumors of lacrimal glands are similar to the salivary gland tumors. We hereby intend to report a case of myoepithelioma of lacrimal gland in a 62 years Indian female and its clinical, histopathological and immunohistochemistry report are compared to the cases reported in literature.

Case Report

62 years female presented to our out- patient department with complaints of painless swelling of left upper lid associated with mild forward displacement of eye and diminution of vision in the left eye since one year. On examination, visual acuity was 6/12 in the affected eye. There was limitation of levo-elevation on ocular movement. Anterior examination revealed grade III nuclear sclerosis cataract. There was 2 mm axial proptosis of the left eye. Rest ophthalmic examination was within normal limits. On palpation, there was an oval swelling of soft rubbery consistency and smooth margin, of size approximately 2cm x 1 cm, in the superolateral quadrant of the left orbit. There was no pulsation and trans illumination present. Magnetic resonance imaging of orbit revealed a well- defined oval hypodense lesion of 22 x 11 mm in left lacrimal fossa displacing eyeball inferomedially, the mass appeared continuous with lacrimal gland without any bone scalloping or calcification. Based on these findings, a provisional diagnosis of pleomorphic adenoma of lacrimal gland was made. Patient was planned for

anterior orbitotomy under general anesthesia and the lesion was entirely removed 'en-block' along with lacrimal gland. On histopathological examination, grossing revealed an encapsulated gray tumor of 19 x 14 x 10mm size. There was no evidence of any hemorrhage or necrosis. Microscopy showed pleomorphic changes along with spindle cell and round cell proliferation. On immunohistochemistry, tissue was positive for actin, vimentin, cytokeratin and glial fibrillary acidic protein and negative for S100 and desmin (Figure A, B, C and D). Considering the histology of spindle cell proliferation, immunohistochemistry results and the previous reports available in literature, a final diagnosis of myoepithelioma of lacrimal gland was made. Postoperative period was uneventful and the patient was advised systemic antibiotics and anti-inflammatory agents with topical antibiotic eye ointment. The patient was clinically free of disease after 7 months follow up and is under observation till date. There was no evidence of recurrence since last 2 years.

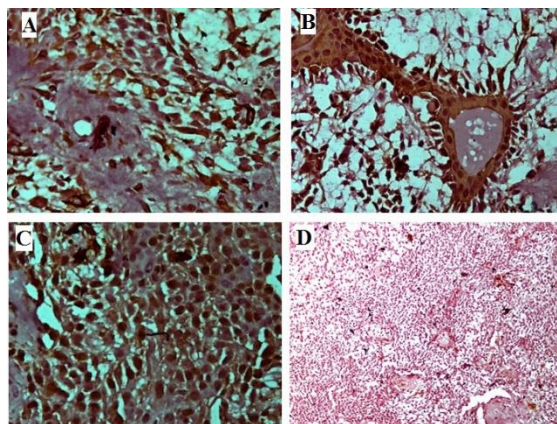


Fig. A: Immunohistochemistry (IHC) positive for GFAP, B: IHC positive for cytokeratin, C: IHC positive for Actin, D: IHC negative for S100

Discussion

Myoepithelioma is a benign tumor which consists of cells showing myoepithelial differentiation in 10% or less ductal component.⁽¹⁾ Cells of origin i.e. the myoepithelial cells are situated between luminal epithelial cells and the intercalated ducts and the basal lamina of acini and intercalated ducts of normal salivary gland. Their location in the lacrimal gland is similar.⁽³⁾ Based on the morphology of this tumor, Dardick et al classified it as solid, myxoid, reticular, and mixed, and into five cellular subtypes being spindle, plasmacytoid, epithelial, clear and mixed.⁽⁴⁾ As very few cases have been reported, the present case report aims to add to the limited knowledge of the disease course and its histopathology and immunochemistry.

Of the eighth reported cases, all of them belonged to different age group. Males were slightly more frequently affected than females with the ratio being 4:3. Spindle cell variety was more frequently found in 4 cases which was similar to the present case. One each of epithelioid, plasmacytoid and mixed variety has been reported. None of them had any invasion, necrosis or hemorrhage present similar to the present case. Table 1 summarizes the details of all the reported cases and their comparison to the present case.

Table 1: Comparison of present case of myoepithelioma with the rest seven reported cases in literature

	Present case I	Case II ⁽⁵⁾	Case III ⁽¹⁾	Case IV ⁽⁶⁾	Case V ⁽⁷⁾	Case V ⁽⁸⁾	Case VII ⁽⁹⁾	Case VIII ⁽⁴⁾
Age (years)	62	34	46	Middle age	23	76	68	77
Sex	F	M	M	F	F	F	M	M
Side	Left	Right	Right	NK	Left	Right	Left	Left
Size	19x14x10	25x15x18	16x18x16	31x25x17	30x25x17	9x9x9	35x30x25	NK
Variant	Spindle	Spindle	Plasmacytoid	Spindle	Spindle	Mixed	Epithelioid	Spindle
S-100	-	+	+	NK	NK	NK	NK	+
CK	+	-	+	NK	NK	NK	NK	NK
GFAP	+	-	+	NK	NK	NK	NK	+
SM-ACTIN	+	+	-	NK	NK	NK	NK	+

Abbreviations used: +: Positive; -: Negative; M: Male; F: Female; NK- Not known

As immunohistochemistry is a recent investigation in the field of pathology and diagnostic medicine, it helps to better understand the tumor and its type. Being relatively new, this has not been done in the reports published earlier as evidenced from the table.

However, there is a need of more case reports and studies of longer duration in order to understand the tumor and its histopathology as well as immunohistochemistry, course of disease and the nature of its outcome. The rarity of this tumor makes it unique in itself and more knowledge on this subject is required for better planning and management of this disease.

Conclusion

Thus, myoepithelioma of lacrimal gland is a rare tumor, a slowly growing lesion, presenting as painless proptosis of 1 year duration with limitation of extraocular movements. Histopathology and immunohistochemistry helps to complete the diagnosis in such cases. More case reports and studies are needed to further understand the neoplasm and its histological variants.

Acknowledgement

Prof. Panna Deka, Mr. Apurba Deka

References

- Bolzoni A, Pianta L, Farina D, Nicolai P. Benign myoepithelioma of lacrimal gland: report of a case: Eur Arch Otorhinolaryngol. 2005;262:186-8.
- Herrera GA. Light microscopic, ultrastructural and immunohistochemical spectrum of malignant lacrimal and salivary gland tumor, including malignant mixed tumor. Pathobiology. 1990;58:312-322.
- Cutler LS, Chaudhry A, Innes OJ Jr. Ultrastructure of the parotid duct. Cytochemical studies of the striated duct and papillary cystadenoma lymphomatosum of the human parotid gland. Arch Pathol Lab Med. 1977;101:420-4.
- Dardick I, Thomas MJ, van Nostrand AWP. Myoepithelioma — new concepts of histology and classification: a light and electron microscopic study. Ultrastruct Pathol. 1989;13:187-224.
- Iida K, Shikishima K, Okido M, Sato S, Masuda Y. A case of malignant myoepithelioma in the lacrimal gland. Nippon Ganka Gakkai Zasshi. 2001;105:42-46.
- Font RL, Garner A. Myoepithelioma of the lacrimal gland: report of a case with spindle cell morphology. Br J Ophthalmol. 1992;76:634-636.
- Grossniklaus HE, Wojno TH, Wilson MW, Someren AO. Myoepithelioma of the lacrimal gland. Arch Ophthalmol. 1997;115:1588-1590.
- Okudela K, Ito T, Iida MI, Kameda Y, Furono K, Kitamura H. Myoepithelioma of the lacrimal gland: report of a case with potentially malignant transformation. Pathol Int. 2000;50:238-243.
- Heathcote JG, Hurwitz JJ, Dardick I (1990) A spindle-cell myoepithelioma of the lacrimal gland. Ophthalmology 108:1135-1139.