

Comparison of efficacy of diagnostic hysteroscopy and transvaginal sonography in evaluation of women with abnormal uterine bleeding

Vasundhara Padmanabhan^{1,*}, D. Susmitha², Satya Sowjanya³

¹Professor, ²Senior Resident, ³Junior Resident, Dept. of Obstetrics & Gynecology, Katuri Medical College, Guntur, Andhra Pradesh

***Corresponding Author:**

Email: ananthavasup@gmail.com

Abstract

Abnormal uterine bleeding (AUB) is one of the most common disorder for which a woman needs immediate attention. Transvaginal ultra sonography (TVS) being simple and non invasive modality and Hysteroscopy is a new endoscopic approach that can visualise the entire uterine cavity to detect the pathology. This study was designed to compare the accuracy of hysteroscopy and transvaginal ultrasonography in the diagnosis of intracavitary disorders in patients with abnormal uterine bleeding.

Date of Acceptance: 24th March, 2017 **Date of Manuscript Receipt:** 14th February, 2017

Introduction

Abnormal uterine bleeding is the most common complaint of the women in reproductive age group⁽¹⁾ and it accounts for 33% of female patients referred to gynaecologists.⁽²⁾ All abnormal patterns of menstrual bleeding result from variety of causes are considered as AUB. Anovulation, uterine pathology and coagulopathies are the most common causes

The bleeding patterns are menorrhagia (bleeding lasting >7 days or/and blood loss >80 mL at regular intervals), metrorrhagia (bleeding occurring at irregular intervals), menometrorrhagia (a combination of the two).⁽²⁾ Anovulatory bleeding associated with infrequent, irregular pattern of bleeding and regular menstrual cycles with excessive flow is associated with ovulatory cycles with anatomical abnormalities of uterus. A careful history and physical examination are preliminary for starting the evaluation of AUB.

Improvement in the accuracy of diagnosing the cause of AUB will improve woman's general condition, decreases anaemia and can reduce the frequency of hysterectomy as a cure. Office endometrial biopsy is used to be the mainstay of investigation for abnormal uterine bleeding but it is a blind procedure and not accurate for diagnosing focal intrauterine lesions such as endometrial polyps or submucous fibroids which may be small or located in areas difficult to approach.⁽³⁻⁶⁾ Currently, the main diagnostic methods which are being used in the evaluation of AUB are transvaginal ultrasonography, a non-invasive approach and diagnostic hysteroscopy an invasive method to detect pathology of uterus.⁽⁷⁾

Present study was done to compare the accuracy of TVS and hysteroscopy in diagnosing the cases of abnormal uterine bleeding. This is to formulate the ideal investigation protocol in these female patients to avoid time delay in treatment of AUB.

Aims and Objectives

To compare the validities of Transvaginal ultrasonography and hysteroscopy in evaluation of AUB.

Materials and Methods

This prospective observational study was conducted at the Department of Obstetrics and Gynaecology of Katuri medical college and hospital, a tertiary care teaching hospital at Guntur, Andhra Pradesh. The study population included female patients attending the OPD for abnormal uterine bleeding.

126 patients with AUB were explained about the investigations and management, 98 women were given consent for the study

Inclusion criteria: Women between age group 25-55yr, who had given consent for study, investigations and follow up

Exclusion criteria: Unmarried women, uterine size larger than 12 weeks gestation, women who were on medication which alters the bleeding pattern, women with coagulation disorders those with pelvic inflammatory disease, women with cervical mass lesions.

82 women fulfil the eligibility criteria and taken for study.

After taking proper history each patient was subjected to proper general examination, systemic examination, pelvic examination. Each woman was categorised according to her symptoms like menorrhagia, metrorrhagia, menometrorrhagia.

Each woman was subjected to undergo blood investigations like haemogram, peripheral smear, ESR, bleeding time, clotting time, thyroid profile, renal function tests. Later TVS examination was performed by a radiologist using a 7.5 MHz vaginal probe transducer. Anatomic abnormalities, mass lesions in the endometrial cavity like polyps, submucous fibroids,

thickness of the endometrium and uterine adnexae were observed and reported.

Each woman was counselled for short hospital stay to undergo hysteroscopy. Pre anaesthetic examination was done to undergo hysteroscopy under short general anaesthesia. Hysteroscopy was performed by using a 30° hysteroscope and the uterine cavity was distended with normal saline. Endometrial biopsy was taken from suspected areas while doing hysteroscopy and sent for HPE. Therapeutic procedures like endometrial resection, polypectomy were also performed depending on the type of lesion.

A total of 80 patients completed the study and underwent both TVS and hysteroscopy. Sensitivity, specificity and predictive value of the TVS and hysteroscopy in detecting the intracavitary lesions were calculated by taking histopathology report as standard for diagnosing the pathology. The results were analyzed and compared with each other.

Results

From each patient demographic data, chief complaints, TVS findings, hysteroscopic findings were tabulated. Comparison between the two diagnostic procedures was done. The accuracy was calculated in related to the histopathological diagnosis

Table 1: Age wise distribution of AUB

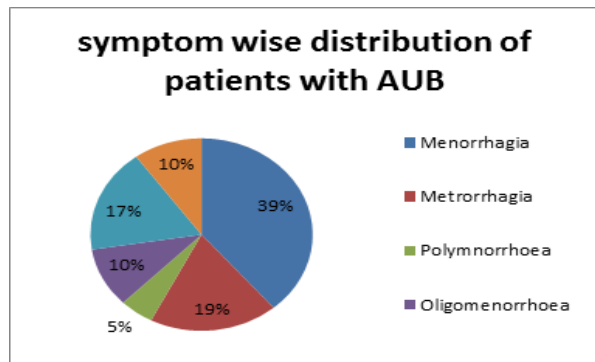
Age group	No of patients	Percentage
25-35	18	22.5
36-45	36	45
46-55	26	32.5
Total	80	100

Majority of women with AUB in our study were between 36-45yrs age. Multiparous women were 86%. At this age group we have to start screening procedures to rule out genital cancers.

Table 2: Symptom wise distribution of AUB

Symptoms	No of patients	Percentages
Menorrhagia	31	38.75%
Metrorrhagia	15	18.75%
Polymnorrhoea	4	5.00%
Oligomenorrhoea	8	10.00%
Menometrorrhagia	14	17.5%
Postmenopausal bleeding	8	10%
Total	80	100%

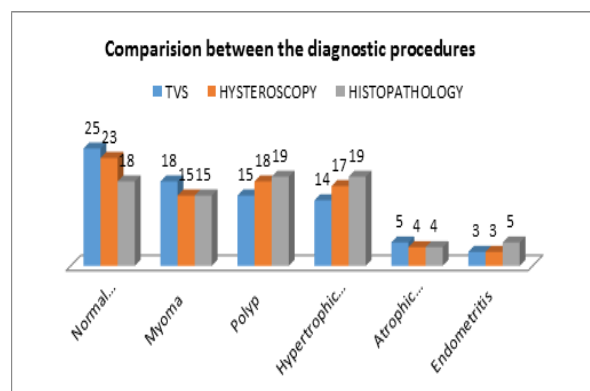
Menorrhagia was the most common symptom and most of the women in our study had presented with bleeding more than 2weeks duration.



The observations of each procedure was tabulated and compared with histopathology report.

Table 3: Comparison of findings of diagnostic procedures

Findings	TVS	Hysteroscopy	Histopathology
Normal endometriun	25 (31.25%)	23 (28.75%)	18 (22.5%)
Myoma	18 (22.5%)	15 (18.75%)	15 (18.75%)
Polyp	15 (18.75%)	18 (22.5%)	19 (23.75%)
Hypertrophic endometrium	14 (17.5%)	17 (21.25%)	19 (23.75%)
Atrophic endometrium	5 (6.25%)	4 (5%)	4 (5%)
Endometritis	3 (3.75%)	3 (3.75%)	5 (6.25%)
Total	80	80	80



Sensitivity, specificity, positive predictive value, negative predictive value were calculated for each test.

Table 4: Validity of TVS

TVS	Histopathology		Total
	Abnormal	Normal	
Abnormal	49	6	55
Normal	13	12	25
Total	62	18	80

Table 5: Validity of hysteroscopy

Hysteroscopy	Histopathology		Total
	Abnormal	Normal	
Abnormal	56	1	57
Normal	6	17	23
Total	62	18	80

Validity of each diagnostic procedure were compared with histopathological diagnosis.

Table 6: Comparison of validities

Validity	TVS	Hysteroscopy
Sensitivity	79.03%	90.3%
Specificity	66.6%	94.4%
Positive predictive value	89.09%	98.2%
Negative predictive value	48%	73.9%
Accuracy	76.25%	91.25%

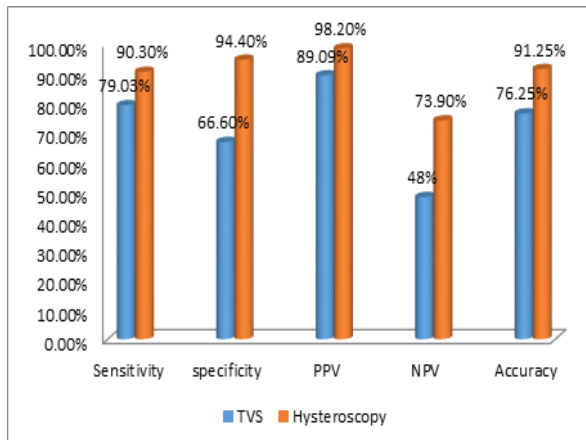


Table 6, showing that hysteroscopy is more accurate in diagnosing the endometrial pathology when compared to TVS. But with the help of TVS alone we can detect 2/3rd of abnormalities.

Discussion

Abnormal uterine bleeding constitutes a large proportion of gynaecologic consultations.⁽⁹⁾ Accurate diagnosis is key factor to treat AUB without delay. The treating doctor should order various investigations to detect underlying pathology. Endometrial hyperplasia, endometrial polyps, submucous fibroids, fibroid polyps, cervical dysplasias are the major pathologies of AUB.

The most reliable diagnostic tests for evaluation of AUB are hysteroscopy and transvaginal ultrasonography (TVS). Histopathology will give the additional support for diagnosis. It is essential for the clinician to understand the appropriate role and need of various diagnostic tests in the evaluation of AUB.

We had undertaken the present study to evaluate the efficacy of TVS and hysteroscopy in patients with AUB and compared with hystopathological evidence.

TVS is quick, non invasive, easy to perform, at low cost. Apart from that it has high sensitivity and more positive predictive value hence can be used as screening test. Most of the clinicians opinion that, no need for hysteroscopy if clinical diagnosis and TVS are conclusive for one another.⁽¹¹⁻¹³⁾ TVS is a equally reliable procedure in detecting intracavitary mass lesions as hysteroscopy, hence no need for hysteroscopy after a negative TVS.⁽¹⁴⁻¹⁵⁾ Detection of

abnormalities in the paramtrium and ovaries is possible with TVS. Expertise of the sonologist will reduce the false positives and false negatives and increases the accuracy.

Hysteroscopy had got high specificity, sensitivity both positive and negative predictive values. Hence it can be used as diagnostic procedure. Moreover in our study we had found that hysteroscopy has a very high predictive value, both negative as well as positive.

To perform hysteroscopy the women should be counselled, informed consent has to be taken, short general anaesthesia is required. The woman needs to explain the anaesthesia and procedure related complications. Pathology in the adnexa will not be visualised. Apart from these the patient needs short hospital stay. It is costlier and special training is required for the clinician.

But the benefits of hysteroscopy outweigh the risks. The clinician can take biopsies from suspected areas, direct visualisation will helps in proper planning for treatment. If necessary, therapeutic procedures can also be performed at the same time. Surgical skill of the treating clinician will reduce the complications.

In our study most of the women with AUB are between the age group 36-45yrs. It is the treating clinician's responsibility to identify pre-malignant and malignant lesion. Hysteroscopy guided biopsy yields promising results when compared with office endometrial biopsy.

Conclusion

Hysteroscopy and guided endometrial biopsy will give the definitive diagnosis for abnormal uterine bleeding. As it is an invasive and costly procedure, most of the women are not willing for this procedure. Proper counselling is needed to perform the procedure. Hence it should be reserved for diag.

Surgical skill of the clinician will reduce the procedure related complications and yields good results.

Transvaginal sonography is equally effective as hysteroscopy in identifying the intracavitary mass lesions and hyperplasia of endometrium. It is an outpatient procedure, quick and can be done at low cost. Hence can be used as screening test.

Combination of these two tests is needed after careful history taking, physical examination to get good results and proper planning to treat AUB and to avoid unnecessary hysterectomies. Early diagnosis and proper treatment will reduce the morbidity and increases the general health and well being of women.

References

1. Fritz M.A., Speroff L., editors. Clinical Gynecologic Endocrinology and Infertility. 8th ed. LWW; Philadelphia: 2011. pp. 591-606.
2. Mencaglia L., Perino A., Hamou J. Hysteroscopy in perimenopausal and postmenopausal women with

- abnormal uterine bleeding. *J Reprod Med.* 1987;32:577–582.
3. Word B., Wideman G.L. The fallacy of simple uterine curettage. *Obstet Gynecol.* 1958;12:642–648.
 4. Grimes D.A. Diagnostic dilation and curettage: a reappraisal. *Am J Obstet Gynecol.* 1982;42:1–6.
 5. Stock R.J., Kanbur A. Prehysterectomy curettage. *Obstet Gynecol.* 1975;45:537–541.
 6. Stovall T.G., Soloman S.K., Ling F.W. Endometrial sampling prior to hysterectomy. *Obstet Gynecol.* 1989;73:405–408.
 7. Farquhar C., Ekeroma A., Furness S., Arroll B. A systematic review of transvaginal sonography, sonohysterography and hysteroscopy for the investigation of abnormal uterine bleeding in premenopausal women. *Acta Obstet Gynecol Scand.* 2003;82:493–5048. Wamsteker K., Emanuel M.H., de Kruif. Fibroids. In: Lewis B.V., Magos A.L., editors. *Endometrial Ablation.* Churchill Livingstone; Edinburgh: 1993. pp. 161–181.
 8. Coulter A., Bradlow J., Agass M. Outcomes of referrals to gynaecology out-patient clinics for menstrual problems: an audit of general practice records. *Br J Obstet Gynaecol.* 1991;98:789–796.
 9. Eisenberg J.M., Sankey V., Williams M.D. Computer based audit to detect and correct overutilization of laboratory tests. *Med Care.* 1977;15:915–921.
 10. Towbin N., Gviazda I., March C. Office hysteroscopy versus transvaginal ultrasonography in evaluation of patients with excessive uterine bleeding. *Am J Obstet Gynecol.* 1996;174:1678–1682.
 11. Fedele L., Bianchi S., Dorta M. Transvaginal sonography versus hysteroscopy in the diagnosis of uterine submucous myomas. *Obstet Gynecol.* 1991;77:745–748.
 12. Wood C., Hurley V.A., Leoni M. The value of vaginal ultrasound in the management of menorrhagia. *Aust N Z J Obstet Gynecol.* 1993;33:198–200.
 13. Indman P.D. Abnormal uterine bleeding: accuracy of vaginal probe ultrasound in predicting abnormal hysteroscopic findings. *J Reprod Med.* 1995;40:545–548.
 14. Vercellini P., Cortesi I., Oldani The role of transvaginal ultrasonography and outpatient diagnostic hysteroscopy in the evaluation of patients with menorrhagia. *Hum Reprod.* 1997;12:1768–1771.