



A study on hepatoprotective activity of aqueous seed extract of *Vigna Unguiculata* (L) Walp against ethanol induced hepatotoxicity in rats

Ibrahim Sayeed V K^{1*}, Satish S², Ajay Kumar K³ and Chaitra Amin B⁴

Department of Pharmacology, Srinivas College of Pharmacy, Valachil, Post Farangipete, Mangalore-574143, Karnataka, India.

Received: 12-03-2017 / Revised Accepted: 19-04-2017 / Published: 26-04-2017

ABSTRACT

In the present study, the aqueous extract of *Vigna unguiculata* (L) Walp seed was evaluated for its hepatoprotective effect on ethanol induced acute liver damage on Wistar albino rats. The degree of protection was measured by using biochemical parameters such as serum glutamate oxalate transaminase (SGOT), serum glutamate pyruvate transaminase (SGPT), alkaline phosphatase (ALP), total bilirubin (TB), superoxide dismutase (SOD), lipid peroxidation (LPO), glutathione (GSH), and catalase (CAT) levels. Ethanol induced group had enhanced levels of SGPT, SGOT, ALP, TB & LPO and decreased levels of GSH, SOD and CAT when compared with control group. Treatment with silymarin, 200mg/kg and 400mg/kg of *Vigna unguiculata* (L) Walp seed extract had significantly brought down the elevated levels of SGPT, SGOT, ALP, TB & LPO and an increase in the levels of GSH, SOD, LPO and CAT. The results showed that aqueous extract of *Vigna unguiculata* (L) Walp seeds possesses significant hepatoprotective activity.

Key words: Ethanol, *Vigna unguiculata* (L) Walp, Hepatotoxicity, Wistar albino rat.

INTRODUCTION

Herbal drugs play an important role in drug discovery process, which provides basic compounds affording less toxic and more effective drug molecules, serves as extremely useful natural drugs, exploration of biologically active prototypes towards newer and better synthetic drugs and modification of inactive natural products by suitable biological or chemical means into potent drugs [1]. India is sitting on gold mine of well recorded and traditionally well practices knowledge of herbal medicine, therefore, any scientific data on such plant derivatives could be of clinical importance. Urbanization and changes linked with it like sedentary lifestyle, fatty food, uncontrolled blood sugar, obesity, smoking and high alcohol intake is leading Indians towards higher incidence of fatty liver disease. According to the latest WHO data published in May 2014 Liver Disease Deaths in India reached 216,865 or 2.44% of total deaths and ranks 61 in the world.

Alcoholic liver disease is a worldwide health problem which has three manifestations in form of fatty liver/steatosis, alcoholic hepatitis and liver cirrhosis. At least 80% of chronic alcoholic

consumers may develop steatosis, 10-35% alcoholic hepatitis and approximately 10% liver cirrhosis. Intake of alcohol causes accumulation of reactive oxygen species (ROS) like superoxide, hydroxyl radical and hydrogen peroxide in the hepatic cell that oxidize the glutathione which leads to lipid peroxidation of cellular membranes, oxidation of protein and DNA resulting in hepatic damage [2].

Number of plants being used for the treatment of hepatic disorders. The seeds of the *Vigna unguiculata* (L) Walp used in Ayurveda as hepatoprotective and in the treatment of liver disorders like jaundice [3], also possess antioxidant [4] and free radical scavenging activity [5], which can be beneficial properties in the treatment of hepato toxicity. However, there is paucity of scientific data for the hepatoprotective activities of the whole plant. Hence, the present study is designed to evaluate the efficacy of *Vigna unguiculata* (L) Walp seed extract against ethanol induced hepato toxicity in wistar albino rats.

MATERIALS AND METHODS

Plant material collection: The seeds of *Vigna unguiculata* (L) Walp was collected from local

*Corresponding Author Address: Ibrahim Sayeed V K, Department of Pharmacology, Srinivas College of Pharmacy, Valachil, Post Farangipete, Mangalore-574143, Karnataka, India; Email: sayeedivk@gmail.com

market of Mangaluru district and the plant was identified and authenticated by a Taxonomist Mrs. Aparna Upadhyaya. Govt.High school Hodavad, Madikeri.

Preparation of extract: The *Vigna unguiculata* (L) Walp seeds were dried in the shade, pulverized by mechanical grinder and passed through a 40 mesh sieve. The powder was extracted by maceration with distilled water for 24hrs. The extract was double filtered by using muslin cloth and Whatmann filter paper No.1 and concentrated by evaporation on water bath. The extract was preserved in airtight containers and kept at 4-5°C until further use [6].

Phytochemical screening: Preliminary phytochemical screening of aqueous extracts of *Vigna unguiculata* (L) Walp seeds was carried out as per the methods and tests to confirm the presence and absence of various phytoconstituents [7,8]. These tests revealed the presence of carbohydrates, alkaloids, glycosides, saponins, tannins, flavonoids and polyphenols. The results of preliminary phytochemical screening of aqueous extracts of *Vigna unguiculata* (L) Walp seeds were showed in table 1.

Table 1: Phytochemical analysis of *Vigna unguiculata* (L) Walp seeds

Carbohydrates	+
Glycosides	+
Alkaloids	+
Flavonoids	+
Tannins	+
Saponins	+
Steroids	-
Polyphenols	+

Drugs and Chemicals: All chemicals used were of analytical grade and obtained from Himedia Laboratories. The kits for the estimation of SGPT, SGOT, ALP and Bilirubin were purchased from Agape Diagnostics LTD, Kochi. The standard drug Silymarin was purchased from Serum international Ltd, India.

Experimental animals: Healthy Wistar albino rats of either sex weighing 150-200 g were used. Animals used in the study were procured from registered breeder. The animal care and handling was carried out according to CPCSEA guidelines. Animals were acclimatized to the animal quarantine for one week prior to the experiment under controlled conditions of temperature (27 ± 2°C) and were housed in sterile polypropylene cages containing paddy husk as bedding material with maximum of six animals in each cage. The rats were fed on standard food pellets and water *ad*

libitum. The studies conducted were approved by the Institutional Animal Ethical Committee, Srinivas College of Pharmacy, Mangalore, Karnataka (Approval No.: SCP/CPCSEA/ F150/P02/2015).

Acute toxicity studies: Acute toxicity study of the aqueous extract of *Vigna unguiculata* (L) Walp plant seeds was performed as per the OECD guidelines 425 at a limit dose of 2000 mg/kg. The doses were administered by oral route in mouse as per schedule. Animals were observed individually at least once during the first 30 minutes after dosing, periodically during the first 24 hours (with special attention given during the first 4 hours), and daily thereafter, for total 14 days for sign of discomfort, general behavior and mortality. The LD50 was calculated by using OECD guideline 425 [9]. In the present study, 200 mg/kg and 400 mg/kg (*Vigna unguiculata* (L) Walp) doses were selected.

Ethanol induced hepatotoxicity studies: Wistar albino rats were randomly assigned into five groups of six animals each. Group I served as control and received vehicle (Distilled water), Group II served as toxic control and received 40% v/v of Ethanol at a dose of 2ml/100g, Group III served as reference standard and received standard drug (Silymarin 100 mg/kg), Group IV served as low dose test and received aqueous extracts of *Vigna unguiculata* (L) Walp at a dose of 200mg/kg and Group V served as High dose test and received aqueous extract of *Vigna unguiculata* (L) Walp seeds at a dose of 400mg/kg body weight.

All the four groups except group I were intoxicated by oral administration of ethanol (40% v/v, 2 ml /100g) daily for 21 days. All the drug preparations were done in distilled water and administered orally once daily for 21 days.

On 22nd day, after 24hrs of ethanol administration, blood was collected through retro orbital route and serum was separated for analyzing various biochemical parameters like SGPT, SGOT, ALP and Total bilirubin. Animals were sacrificed by euthanasia and liver was dissected out and used for endogenous antioxidant analysis and histopathological studies [10].

Statistical analysis: All data were expressed as mean ±SEM. The statistical significance between groups was compared using one way ANOVA, followed by Dunnett's (multiple comparisons) test.

OBSERVATION AND RESULTS

Evaluation of Biochemical parameters: The effect of aqueous extract of *Vigna unguiculata* (L)

Walp seed on various biochemical parameters are shown in Table No.2. It was observed that, the activities of serum SGOT, SGPT, ALP & TB were increased markedly in ethanol fed animals as compared to normal control group. The administration of *Vigna unguiculata (L) Walp* seed extract 200mg/kg and 400mg/kg lowered the ethanol induced elevation of serum parameters. The

Standard (Silymarin) treatment showed extremely significant ($P<0.001$) reduction in SGPT, SGOT, ALP, and TB. Treatment with *Vigna unguiculata (L) Walp* (200mg/kg) showed moderately significant ($P<0.05$) reduction and treatment with 400mg/kg showed significant ($P<0.01$) reduction in SGOT, SGPT, ALP & TB level as compared to toxic control group.

Table No. 2: Effect of Silymarin and Aqueous extract of *Vigna unguiculata (L) Walp* on SGOT, SGPT, ALP & TB in ethanol induced liver toxicity.

Groups	Treatment	ALP(U/I)	SGOT(U/I)	SGPT(U/I)	TB(mg/dl)
Normal control	Distilled water 1ml/kg	106.3± 0.67	55.3± 1.02	44.8± 1.14	0.62± 0.06
Toxic control	Ethanol 2ml/100 g p.o	230.0± 2.35 ^a	124.7± 1.2 ^a	112.8± 1.53 ^a	2.09± 0.07 ^a
Standard	Silymarin 100mg/Kg, p.o	140.0± 2.6 ^{***}	71.0± 1.0 ^{***}	59.7± 1.3 ^{***}	0.78± 0.05 ^{***}
Low dose	<i>Vigna Unguiculata (L) Walp</i> 200 mg/Kg, p.o	201.2± 1.35 [*]	97.3± 1.3 [*]	87.2± 1.2 [*]	1.48± 0.05 [*]
High dose	<i>Vigna Unguiculata (L) Walp</i> 400 mg/Kg, p.o	181.2± 1.1 ^{**}	87.3± 1.1 ^{**}	75.2± 0.8 ^{**}	1.08± 0.04 ^{**}

All the values are Mean±SEM, n=6. One way ANOVA followed by Dunnett's t test. ^ap< 0.001 when compared with vehicle treated control group. *p<0.05, **p<0.01, ***p<0.001 when compared with toxic control.

Evaluation of liver endogenous antioxidant enzymes: The effects of aqueous extracts of *Vigna Unguiculata (L) Walp* seed on LPO, SOD, GSH and lipid Catalase concentrations in rat liver after challenging with ethanol are shown in Table No. 3. It was observed that animals treated with ethanol developed a hepatic damage, as increase in LPO and decrease in SOD, GSH and CAT when compared to normal control. Animals treated with standard (Silymarin) showed extremely significant

increase ($P<0.001$) in SOD, GSH & CAT and decrease in LPO. Treatment with *Vigna Unguiculata (L) Walp* extract (200mg/kg) showed moderately significant decrease ($P<0.05$) in LPO and increase ($P<0.05$) in SOD, GSH & CAT, whereas treatment with extract (400mg/kg) showed significant decrease ($P<0.01$) in LPO and increase ($P<0.01$) in SOD, GSH & CAT as compared to toxic control.

Table No. 3: Effect of Silymarin and Aqueous extract of *Vigna unguiculata (L) Walp* on LPO, SOD, GSH, and CAT in ethanol induced liver toxicity

Groups	Treatment	LPO (Abs at 535 nm)	SOD (Abs at 560 nm)	GSH (Abs at 412nm)	CAT (Abs at 620 nm)
Normal Control	Distilled water 1ml/kg	1.7± 0.12	12.88±0.12	5.12± 0.12	15.12± 0.12
Toxic control	Ethanol 2ml/100 g	5.7± 0.12 ^a	4.28± 0.12 ^a	2.02± 0.14 ^a	3.92± 0.11 ^a
Standard	Silymarin 100mg/kg	1.93± 0.13 ^{***}	11.0± 0.12 ^{***}	4.53± 0.12 ^{***}	13.1± 0.09 ^{***}

Low dose	<i>Vigna Unguiculata</i> (L) Walp 200mg/kg	4.32± 0.13*	6.32± 0.06*	2.9±0.08*	7.83± 0.08*
High dose	<i>Vigna Unguiculata</i> (L) Walp 400mg/kg	3.08± 0.08**	7.73± 0.05**	3.92±0.05**	9.83±0.08 **
All the values are Mean±SEM, n=6. One way ANOVA followed by Dunnett's t test. ^a p< 0.001 when compared with vehicle treated control group. *p<0.05, **p<0.01, ***p<0.001 when compared with toxic control.					

Histopathological Profile: Histopathological studies of liver sections of control animal showed normal hepatic cells with well-preserved cytoplasm, prominent nucleolus and central vein (Fig. 1). Whereas the liver section of animals treated with 40% v/v ethanol showed sever degree of liver damage, showing congestion, macrovesicular and microvesicular steatosis (Fig.

2). The liver section of animal treated with standard drug (Silymarin) shows inflammation in the periportal region and moderate congestion (Fig. 3). The liver section of animals treated with *Vigna unguiculata* (L) Walp (200 mg/kg) shows mild inflammation and congestion (Fig. 4) whereas treatment with seed extract (400 mg/kg) shows moderate inflammation and congestion (Fig 5).

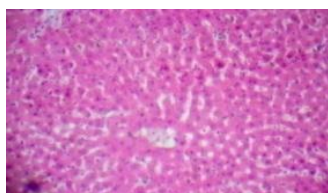


Fig. 1: Vehicle control

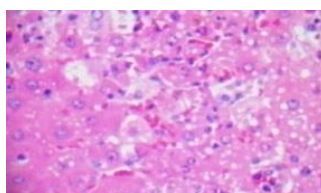


Fig. 2: Toxic control

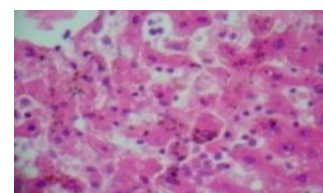
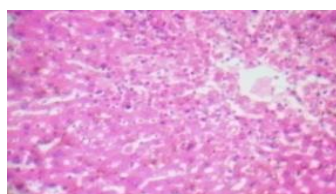
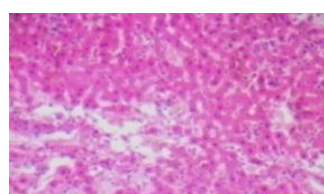


Fig. 3: Standard (Silymarin)

Fig. 4: *Vigna unguiculata* (L) walp (200 mg/kg)Fig. 5: *Vigna unguiculata* (L) walp (400 mg/kg)

DISCUSSION

The liver is an extremely resilient organ to resist toxic insults because of its unique cellular attributes. Despite this resiliency, the liver is vulnerable to injury because it is frequently exposed to agents in their most reactive toxic forms. The major functions of the liver are carbohydrate, protein and fat metabolism, detoxification, secretion of bile and storage of vitamin. Maintenance of a healthy liver is a crucial factor for overall health and wellbeing [11].

The hepatoprotective index of a protective agent is considered its capacity to maintain the normal hepatic physiological mechanisms, which has been

disturbed by hepatotoxins. Chronic and excessive ethanol consumption is associated with cellular proliferation, tissue lipid peroxidation, depletion in the tissue GSH levels, fibrosis and cirrhosis [12].

In addition, serum levels of many biochemical markers like SGPT, SGOT, Bilirubin and Alkaline phosphatase are elevated. During hepatic damage, these cellular enzymes leak into the serum, resulting in elevation in their concentrations. Alcohol dehydrogenase is the enzyme that is responsible for conversion of alcohol to acetaldehyde. This acetaldehyde is metabolized to acetate by acetaldehyde dehydrogenase enzyme. These two enzymes cause the reduction of nicotinamide dinucleotide (NAD) to

NADH. That results an alteration in the ratio of NAD/NADH, which leads to steatosis or fatty liver [13]. This causes impairment of carbohydrate metabolism, lipid metabolism, gluconeogenesis and finally results in the diversion of metabolism to ketogenesis and fatty acid synthesis [14]. Long term exposure to alcohol causes the activation of kupffer cells that induce the generation of reactive oxygen species and finally precipitate to oxidative stress, this in turn promotes hepatocyte necrosis, apoptosis, lipid peroxidation, inflammation and fibrosis [15].

In present study administration of ethanol (40% v/v in 2ml/100g bw) for 21 days increased serum enzymes like SGPT, SGOT, ALP and total bilirubin which indicated the ability of alcohol to produce hepatic damage. Administration of *Vigna unguiculata* (L) Walp seed extract with ethanol (Group IV & V) reduced the elevated levels of SGPT, SGOT, ALP and total bilirubin levels indicated their hepatoprotective effect against ethanol induced liver cell damage.

There is an innate antioxidant defense mechanism present in the liver. The major antioxidant enzymes like Lipid peroxidase (LPO), Superoxide dismutase (SOD), Glutathione (GSH) and Catalase (CAT) which catalyzes decomposition of reactive oxygen species [16]. In this study, there is an extreme elevation of LPO and reduction in SOD, GSH and CAT was observed after intoxication with ethanol that showed the ethanol. Administration of *Vigna unguiculata* (L) Walp seed extract with ethanol (Group IV & V) showed significant reduction in LPO and elevation in SOD, GSH & CAT, which indicated its ability to protect against oxidative stress. The preliminary phytochemical studies confirmed the presence of Carbohydrates, Alkaloids, Glycosides, Polyphenols, tannins, flavonoids, saponins and proteins. Phytoconstituents like the flavonoids [17], triterpenoids [18], saponins [19] and alkaloids [20]

are known to possess hepatoprotective activity. The presence of flavanoids in our extract may be responsible for its antioxidant [8] and thus hepatoprotective activity. Numerous studies have suggested that flavonoids commonly function as antioxidants and may protect plants against oxidative stress caused by suboptimal environmental conditions [21, 22]. The antioxidant capacity of flavones is attributed to the high reactivity of the hydroxyl substituent, with the number of hydroxyl groups on the B-ring being correlated with ROS scavenging capability [23]. It was also supported by the histopathological examination carried out on isolated liver.

CONCLUSION

In conclusion, results of our study reported that aqueous extract of *Vigna unguiculata* (L) Walp seed was effective in the treatment of hepatotoxicity induced by ethanol. The degree of protection was measured by using biochemical parameters like SGPT, SGOT, ALP, Total bilirubin and antioxidant characters (LPO, SOD, GSH & CAT). Our results shows that the hepatoprotective effects of *Vigna unguiculata* (L) Walp seeds extract may be due to both an increase in the activity of the antioxidant-defense system and an inhibition of lipid peroxidation. The aqueous extracts showed the significant hepatoprotective activity comparable with standard drug silymarin. However, the protective and antioxidant qualities of *Vigna unguiculata* (L) Walp seed need to be confirmed by characterizing the active ingredient(s) of this seed as well as its mechanism(s) of action.

ACKNOWLEDGEMENT

The authors are thankful to Mr. Sayed Amir, Dr. Karunakar Hegde, Dr. AR Shabaraya and Faculty of Srinivas College of Pharmacy, Mangalore Karnataka, for providing research laboratory facilities.

REFERENCES

1. Rasha Saad et al. Phytochemical screening and antioxidant activity of different parts from five Malaysian herbs. The Exp 2014; 19(2): 1336-7.
2. Muhammad HR, Mahmood T, Salim T, Afzal N, et al. Effect of silymarin and serum levels of ALT and GGT in ethanol induced hepatotoxicity in albino rats. J Ayub Med Coll Abbottabad 2009; 21(4):73-5.
3. Doppalapudi Sandeep. Evaluation of Antibacterial activity of seed extract of *Vigna unguiculata*. Int J Pharm Pharm Sci 2014; 6(1):75-7.
4. Muhammad Zia-Ul-Haq, Shakeel Ahmad, Ryszard Amarowicz, Vincenzo De Feo; Antioxidant Activity of the Extracts of Some Cowpea (*Vigna unguiculata* (L) Walp.) Cultivars Commonly Consumed in Pakistan. Molecules 2013; 18(2): 2005-17.
5. Perumal Siddhuraju, Klaus Becker. The antioxidant and free radical scavenging activities of processed *Vigna unguiculata* (L) Walp seed extracts. Food Chem 2007; 101(1):10-19.
6. Maisale AB, Patil MB, Jalalpure SS, Attimarad SL. Phytochemical properties and Anthelmintic activity of *Vigna unguiculata*. J Pharm Sci Innovat 2012; 1(2):51-2.
7. Kokate CK, Purohit PA, Gokhale BS. Pharmacognosy 22nd ed. Pune: Nirali Prakashan, 2003; 207-32.
8. Trase EG, Evans CW. Pharmacognosy. 12th ed. Eastbourne: English language Book society, 1985; 344.
9. OECD, Guidelines for testing of chemicals, Acute oral toxicity, Environmental Health and Safety Monograph Series on Testing and Adjustment No. 425,2001:1.

Ibrahim et al., J Pharm Biol Sci 2017; 5(3): 111-116

10. Sharma A, Sangameswaran B, Jain V, Saluja MS. Hepatoprotective activity of *Adina cardifolia* against ethanol induce hepatotoxicity in rats. *Int Curr Pharm J* 2012; 1(9):279-84.
11. Koda –Kimble young, Lee young, Curtis D.Holt, Edgar Arriola. Adverse effect of drugs on the liver. *Applied therapeutics –the clinical use of drugs*. 8th Ed. Lippincott Williams & Wilkins .United states of America. ISBN 0781748453; 2015; 30-1
12. Vipul Gujrati, Nilesh Patel, Venkat N Rao, and K Nanda Kumar. Hepatoprotective activity of alcoholic and aqueous extracts of leaves of *Tylophora indica* (Linn.) in rats. *Indian J Pharmacol* 2007; 39(1): 43-4.
13. Stewart S, Jones D and Day CP. Alcoholic liver disease: New insights into mechanisms and preventative strategies. *Trends Mol Med* 2001; 7: 408-13.
14. Lieber CS. Alcohol: its metabolism and interaction with nutrients. *Annu Rev Nutr* 2000; 20: 395–430.
15. Gramenzi A, Caputo F, Biselli M, Kuria F, Lloggi E, Andreone P & Bernardi M. Review article: alcoholic liver disease – pathophysiological aspects and risk factors. *Aliment Pharmacol Ther* 2006; 24(8): 1151–61.
16. Favier A. Oxidative stress in human diseases. *Ann Pharm Fr.* 2006; 64: 390-6.
17. Baek NL, Kim YS, Kyung JS, Park KH. Isolation of anti-hepatotoxic agents from the roots of *Astragalus membranaceous*. *Korean J Pharmacog* 1996; 27:111-6.
18. Xiong X, Chen W, Cui J, Yi S, Zhang Z, Li K. Effects of ursolic acid on liver protection and bile secretion. *Zhong Yao Cai* 2003; 26: 578-81.
19. Tran QI, Adnyana IK, Tezuka Y, Nagaoka T, Tran QK, Kadota S. Triterpene saponins from Vietnamese ginseng (*Panax vietnamensis*) and their hepatocyte protective activity. *J Nat Prod* 2001; 64: 456-61.
20. Vijayan P, Prashanth HC, Dhanraj SA, Badami S, Suresh B. Hepatoprotective effect of total alkaloid fraction of *Solanum pseudocapsicum* leaves. *Pharm Biol* 2003; 41: 443-8.
21. Bohnert HJ, Jensen RG. Strategies for engineering water stress tolerance in plants. *Trends Biotechnol* 1996; 14:89-97.
22. Rice-Evans CA, Miller NJ, Papanga G. Antioxidant properties of phenolic compounds. *Trends Plant Sci* 1997; 2:152-9.
23. Sekher A, Pannala-Chan TS, O'Brien PJ, Rice-Evans CA. Flavonoid B-ring chemistry and antioxidant activity: fast reaction kinetics. *Biochem Biophys Res Commun* 2001; 282(5):1161-8.