

## Morphometric study of coronary Ostia in human cadavers by dissection method

Jyothi SR<sup>1,\*</sup>, Dakshayani KR<sup>2</sup>

<sup>1</sup>Assistant Professor, Subbaiah Institute of Medical Sciences, Shimoga, <sup>2</sup>Professor & HOD, Dept. of Anatomy, MMC & RI, Mysore

**\*Corresponding Author:**

Email: jyothisr39@gmail.com

### Abstract

**Objectives:** An intimate knowledge of the anatomy of coronary ostia does a self-evident pre-requisite for complete understanding of coronary artery diseases and for more intelligent planning of surgery. The present study is undertaken

1. To measure the diameters of coronary ostia and the diameters of roots of coronary arteries.
2. To note for accessory ostia

**Materials and Method:** 49 human hearts fixed with 10% formalin were collected from Department of Anatomy and Forensic Medicine, Mysore Medical College and Research Institute, Mysore. Ethical clearance has been taken for the above.

Morphometric study of coronary ostia was performed using Vernier callipers. Data obtained was statistically analysed.

**Results:** It was observed that the mean diameter of left coronary ostia was greater than right coronary ostia which were statistically significant.

A statistically significant decrease in diameter from coronary ostia to the roots of coronary arteries was observed.

Multiple coronary orifices were common in anterior aortic sinus.

**Conclusion:** The knowledge of coronary ostia becomes important to cardiac surgeons for selective intubation.

**Keywords:** Aortic sinus of Valsalva, Coronary arteries, Coronary ostia, Sinotubular junction.

### Introduction

The Aortic sinus of Valsalva is dilatation of aortic root wall above the attached margin of each cusp. The upper margin of each sinus is limited by well-defined circumferential supra-auricular ridge. The ostia of coronary arteries usually open near this ridge. The right coronary artery arises from anterior aortic sinus and left coronary artery arises from left posterior aortic sinus.<sup>(1)</sup>

Coronary blood flow may be affected by changes in morphology of coronary ostia and it may disturb performing an

1. Aortotomy incision for aortic exposure
2. Preparing a coronary button
3. In aortic root replacement
4. Direct delivery of cardioplegia through coronary orifices
5. Approaches for aortic root enlargement.<sup>(2)</sup>

### Materials and Method

The present study was conducted on 49 hearts of human cadavers fixed with 10% formalin, collected from the Department of Anatomy and Forensic Medicine, Mysore Medical College and Research Institute, Mysore. Ethical clearance has been taken for the above.

The ascending aorta was sectioned transversely approximately 1 cm above the commissure of aortic leaflets. Next the aorta was longitudinally opened at the level of right posterior aortic sinus to enable the visualisation and analysis of coronary ostia. The

coronary arteries were sectioned at the level of their origin in the aortic wall.

Measurements were studied with help of Vernier callipers and divider, and exact measurements were noted. Based on the data obtained, morphology of coronary ostia was analysed.

### Observations

It was observed that the mean diameter of left coronary ostium was greater than right coronary ostium which was statistically significant ( $p$ -value<0.0001) (Table 1). There was decrease in diameter from coronary ostia to the roots of coronary arteries which was statistically significant ( $p$ -value=0.045). Decrease in diameter from left coronary ostium to root was 0.55 mm and right coronary ostium to root was 0.43 mm (Table 2). Number of coronary ostia in anterior aortic sinus was single ostium in 43 (87.75%) specimens, double ostia in 4 (8.16%) specimens, triple ostia in one (2.04%) specimen and also absence of ostium in one specimen (Table 3). Number of coronary ostia in left posterior aortic sinus was single ostium in 48 (98%) specimens and double ostia in one (2%) specimen (Table 4).

**Table 1: Diameters of coronary ostia**

Coronary Ostia	No. of Specimens	Mean(mm)	SD	P-Value
Right	49	3.4	0.9	<0.0001
Left	49	4.3	0.7	

**Table 2: Diameters of coronary ostia and roots of corresponding coronary arteries**

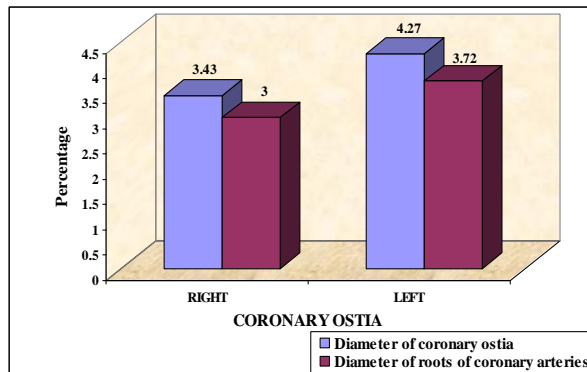
Coronary Ostia	No. of Specimens	Diameter of coronary ostia		Diameter of roots of coronary arteries		Decrease in diameter		Average % of decrease		% OF Decrease	P-Value
		Mean (mm)	SD	Mean (mm)	SD	Mean (mm)	SD	Mean (mm)	SD		
Right	49	3.43	0.87	3.00	0.85	0.43	0.24	13.3	7.5	12.5	0.045
Left	49	4.27	0.72	3.72	0.60	0.55	0.28	12.5	5.7		

**Table 3: Number of coronary ostia in anterior aortic sinus**

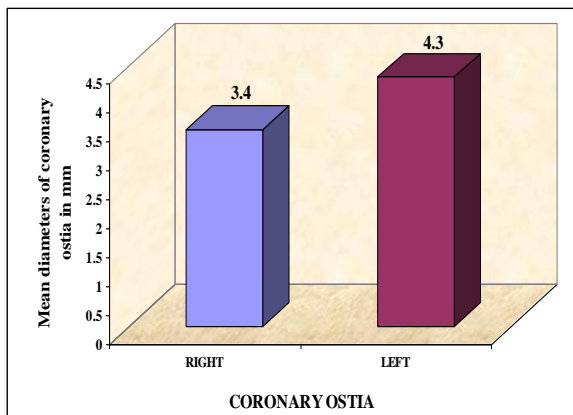
Number of coronary ostia in AAS	No. of specimens	Percentage (%)
0	1	2.04
1	43	87.75
2	4	8.16
3	1	2.04
Total	49	100.00

**Table 4: Number of coronary ostia in left posterior aortic sinus**

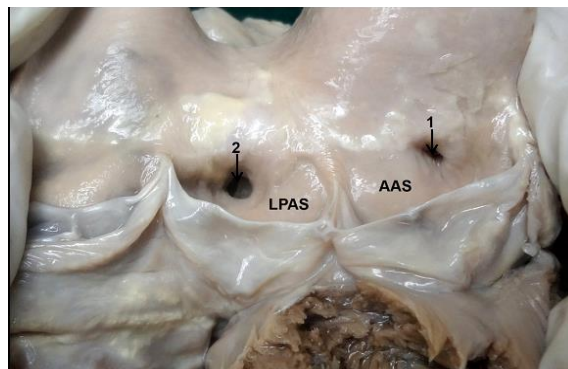
Number of coronary ostia in LPAS	No. of specimens	Percentage (%)
0	0	0
1	48	98
2	1	2
Total	49	100



**Fig. 2: Diameters of coronary ostia and roots of coronary arteries**

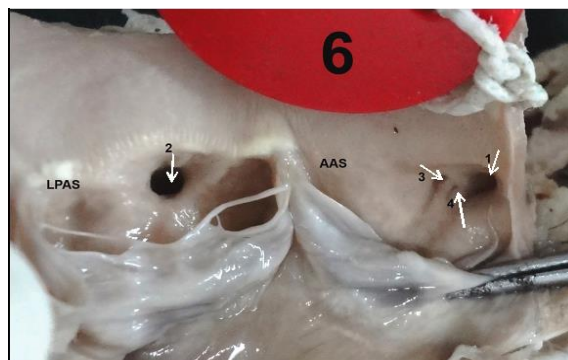

**Fig. 1: Diameters of coronary ostia**



**Fig. 3: Diameter of left coronary ostium more than right coronary ostium**

1. Right coronary ostium, 2. Left coronary ostium



**Fig. 4: Multiple orifices in anterior aortic sinus 1. Right coronary ostium, 2. Left coronary ostium, 3. Ostium of third coronary artery, 4. Ostium of ventricular branch of Right coronary artery**

## Discussion

Coronary ostial diameter is helpful in designing coronary perfusion cannula and for performing successful coronary angiography.<sup>(2)</sup>

In present study, the diameter of left coronary ostium was greater than right coronary ostium which was statistically significant (p-value<0.0001). This observation was in agreement with work done by Cavalcanti et al.,<sup>(3)</sup> Bhimali et al.<sup>(4)</sup> and B PejkoVIC et al.<sup>(5)</sup> Lopez-Minguez JR et al.<sup>(6)</sup> found out of 16 post-mortem hearts the diameter of left coronary ostium was greater in 10 (71%) specimens than right coronary ostium.

In present study there was mean decrease of 0.43 mm (12.5%) in diameter from right coronary ostium to root. A mean decrease of 0.55mm (12.9%) in diameter from left coronary ostium to root. Whereas study done by Cavalcanti et al.<sup>(3)</sup> was showing more percentage of decrease with right than left. This should be considered while designing stents for aorticostial lesions to achieve optimal results and to decrease restenosis.

The major coronary arteries could be identified in the walls of aortic sinuses before the emergence of coronary arterial orifices, thus suggesting in-growth rather than outgrowth of the arterial channels. Mechanisms considered reinforcing the theory of ingrowth to the development of coronary arteries are:

1. The role of neural crest cells
2. Growth factors –VEGF family members.<sup>(7)</sup>

In the present study multiple coronary orifices were more common in anterior aortic sinus which correlates with study of Sirikonda P and Sreelatha S.<sup>(2)</sup>

Mc Alpine WA<sup>(8)</sup> studied anomalous origin of different arteries from aortic sinuses besides third coronary artery and found that there were separate ostia for SA nodal artery and ventricular branch of right coronary artery.

Joshi SD et al.<sup>(9)</sup> described that multiple ostia, vertical shift and slit like ostia may confuse interpretation of images and pose difficulty during procedures such as angiography, angioplasty and coronary artery bypass grafting.

The unknown factors that interferes with wall tension of the aortic sinuses could promote development of anomalous coronary arteries' ostia.<sup>(10)</sup>

Olabu BO et al.<sup>(11)</sup> have explained in their study that the separate orifices for third coronary artery and right coronary artery is due to insufficient unification of these two vessels during their ingrowth towards the ascending aorta.

## Conclusion

The advances made in coronary artery bypass surgeries and modern methods of myocardial revascularisation makes it necessary for thorough complete knowledge of coronary ostia. Understanding variations in morphology of coronary ostia should be sought before surgical interventions. The present

anatomical data may help the cardiac surgeons to modify their surgical reconstruction of the aortic root in order to achieve satisfactory recovery. Keeping in mind the ever evolving and yet unexplored facts of this subject, the present study was undertaken to shed more light on this topic of coronary ostia.

## References

1. Standing S, Ellis H, Healy JC, Johnson D, Williams A, Collins P, et al. Gray's Anatomy. The anatomical basis of clinical practice. 40<sup>th</sup> ed. Philadelphia: New Elsevier Churchill Livingstone; 2008. pp. 968,972-3,978-80.
2. Sirikonda P, Sreelatha S. Measurements and location of coronary ostia. *Int J Biol Med Res* 2012;3(4):2489-96.
3. Cavalcanti JS, Mela NCV, Vasconcelos RS. Morphometric and topographic study of coronary ostia. *Arq Bras Cardiol* 2003;81(4):359-62.
4. Bhimali S, Dixit D, Siddibhavi M, Shirol VS. A study of variations in coronary arterial system in cadaveric human hearts. *World Journal of Science and Technology* 2011;1(5):30-5.
5. PejkoVIC B, Krajnc I, Anderhuber F. Anatomical variations of coronary ostia, aortocoronary angles and angles of division of the left coronary artery of the human heart. *The Journal of International Medical Research* 2008;36:914-22.
6. Lopez-Minguez JR, Ciment V, Yen-Ho S, Gonzalez-Fernandez R, Nogales-Asensio JM, Sanchez-Quintana D. Structural features of the sinus of Valsalva and the proximal portion of the coronary arteries: Their relevance to retrograde aortocoronary dissection. *Rev Esp Cardiol* 2006;59:696-702.
7. Silva Junior GO, Miranda SWS, Mandarim-de-Lacerda C. Origin and development of the coronary arteries. *Int J Morphol* 2009;27(3):891-8.
8. McAlpine WA. Heart and coronary arteries. Berlin: Springer-Verlag; 1975. pp. 133-209.
9. Joshi SD, Joshi SS, Athavali SA. Origins of the coronary arteries and their significance. *Clinics* 2010;65(1):79-84.
10. Hutchins GM, Hanna AK, Moore GW. Development of the coronary arteries in the embryonic human heart. *Circulation* 1988;77:1250-7.
11. Olabu BO, Saidi HS, Hassanali J, Ogen'g'o JA. Prevalence and distribution of the third coronary artery in Kenyans. *Int J Morphol* 2007;25(4):851-4.