

High termination of brachial artery with tortuous superficial radial and ulnar arteries: Anatomical perspectives and clinical implications

Rashmi Malhotra^{1,*}, Rajani Singh², Munish Wadhawan³, Manu Malhotra⁴

¹Assistant Professor, ²Additional Professor, ³Senior Resident, Dept. of Anatomy, ⁴Associate Professor, Dept. of Otorhinology, AIIMS, Rishikesh, Uttarakhand

***Corresponding Author:**

Email: rashmi_krish@yahoo.co.in

Abstract

Introduction: Upper limb arterial tree variations have been drawing attention of anatomists and surgeons since ages owing to the clinical significance attached to them. The main artery of the arm is the brachial artery which after giving branches to it terminates in the forearm.

Aim: The present study aims at exploring the gross anatomy, embryological and applied aspects of the high termination of the brachial artery.

Materials and Method: An unusually high termination of brachial artery into its terminal branches radial and ulnar arteries was noted during routine dissection in the upper part of the arm at AIIMS Rishikesh. The course, branches and relations of these arteries were studied and assessed in the light of available literature.

Conclusion: High termination of the brachial artery implicates a huge applied importance for radiologists, physicians, orthopaedic surgeons. So, encountering such variations might be possible during diagnosis, surgical procedures or interpreting angiograms of the upper limb.

Keywords: Brachial Artery, High bifurcation, Radial Artery, Ulnar Artery, Tortuous

Introduction

Brachial artery commences as the continuation of the axillary artery in the arm. It extends from the lower border of teres major muscle to the neck of the radius where it terminates by dividing into radial and ulnar arteries.⁽¹⁾ Blood pressure and pulsed Doppler ultrasonographic measurements are routinely assessed through distal part of brachial artery.⁽²⁾ Studies done earlier have reported cases of superficial radial artery and high bifurcation of brachial artery.^(3,4) These variations may cause complications in a wide range of clinical situations.^(5,6) This study reports a rare termination of brachial artery with superficial and tortuous course of radial and ulnar arteries correlated with embryology and probable clinical implications.

Case Report

During routine dissection of upper limb by undergraduate students in the Department of Anatomy at AIIMS Rishikesh, an unusual high bifurcation of brachial artery with tortuous radial and ulnar arteries was encountered in the upper third of the right arm in a 72 year old male cadaver (Fig. 1, 2, 3).

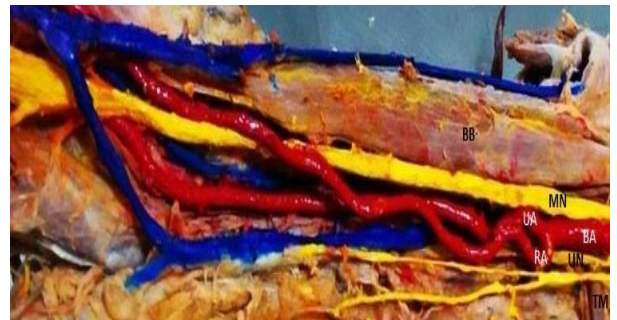

Fig. 1: High bifurcation of Brachial artery in the arm and Origin of Radial and Ulnar Arteries. BB-Biceps brachii muscle, MN-Median Nerve, BA-Brachial Artery, UA- Ulnar Artery, RA-Radial Artery, UN-Ulnar Nerve, TM-Teres Major muscle

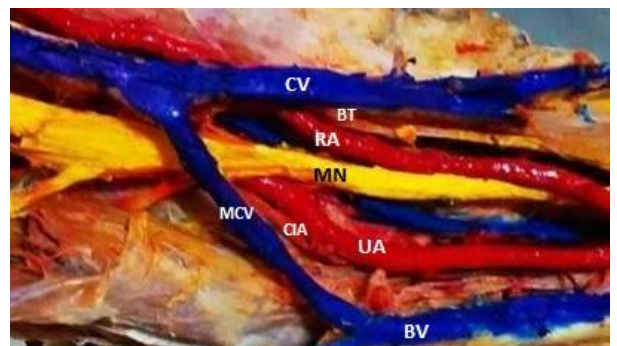


Fig. 2: Relation of Radial and Ulnar Arteries in the Cubital Fossa. Medial to lateral: CV-Cephalic Vein, BT-Biceps Tendon, RA-Radial Artery, MN-Median Nerve, UA- Ulnar Artery, CIA-Common Interosseous Artery, MCV-Median Cubital Vein, BV-Basilic Vein

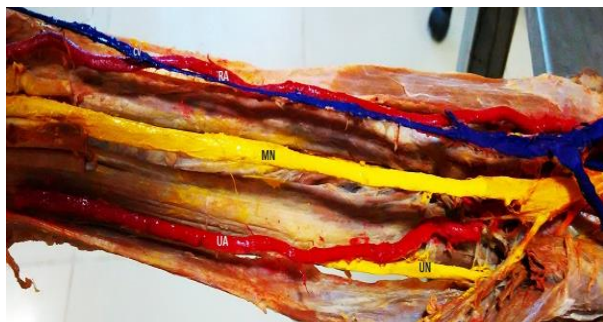


Fig. 3: Course of Radial and Ulnar Arteries in Forearm.

CV-Cephalic Vein, RA-Radial Artery, MN-Median Nerve, UA- Ulnar Artery, UN-Ulnar Nerve

Course of Brachial artery: The brachial artery commenced at the lower border of teres major and coursed for 3.0 centimeters to terminate into radial and ulnar arteries.

Course of Radial artery: In the upper third of the arm, radial artery originated as the medial branch of the brachial artery forming an upward loop or kink. The ulnar artery originated laterally at the same level from the brachial artery. Median nerve was related laterally to both of radial and ulnar arteries. Radial artery was superficial to ulnar nerve at this point. It had a highly tortuous course with medial cutaneous nerves of arm and forearm placed medial to it. After running for 1.5 cm it gave off a muscular branch.

In the lower one third of the arm, radial artery crossed superficially over the ulnar artery, median nerve and tendon of biceps brachii from medial to lateral side to enter into the cubital fossa.

In the cubital fossa, radial artery entered deep to bicipital aponeurosis and cephalic vein. Medial to lateral structures in cubital fossa were ulnar artery, median nerve, radial artery and biceps tendon.

In the forearm, radial artery ran superficially lateral to cephalic vein. It was under the cover of brachioradialis in upper half with brachioradialis tendon laterally in the distal part.

At the termination, radial artery passed deep to cephalic vein to divide into two terminal branches to enter in the palm.

Course of Ulnar artery: In the upper third of the arm, ulnar artery was given off laterally from brachial artery. It ran with relatively lesser tortuosity lateral to radial artery and medial to median nerve up to the elbow.

In the lower one third of the arm ulnar artery was related to basilic vein which was deep to it. The radial artery crossed superficially over the ulnar artery to arrive on its lateral side

In the cubital fossa, Median nerve was related laterally to the ulnar artery/.

In the forearm, ulnar artery entered below the median nerve coursing between forearm muscles superficial to the ulnar nerve which was related

medially in the upper part. The common interosseous artery was given off in the upper part.

At the termination, ulnar artery finally entered the hand by passing superficial to the flexor retinaculum.

Discussion

Earlier researchers have been studying the termination pattern of brachial artery.⁽⁷⁾ Superficial ulnar artery was found in 2% of cases in a study⁽⁸⁾ while high origin of radial artery occurrence was 3 to 15% according to some authors.^(9,10) Superficial brachial artery was reported in 12.3% dissections and was classified into three types according to Keen.⁽¹⁰⁾ Rodriguez-Niedenfuhr explained that the term 'brachio' should be prefixed to name of the artery (e.g. brachioradial, brachioulnar) that originate in the arm, and the term 'superficial' should be labelled if suffixed arteries have a superficial course in the forearm.⁽¹¹⁾ Adachi termed the brachial artery superficial if it courses superficial to the median nerve.⁽¹²⁾ In our study brachial, radial and ulnar arteries had a superficial course in arm and forearm. A similar case of brachial artery bifurcation was reported by Mitra et al in which radial and ulnar arteries had a straight course⁽¹³⁾ whereas in our study the radial artery was highly kinked at origin and both radial and ulnar arteries had a tortuous course in arm.

Earlier studies state that brachial artery may bifurcate proximally and reunite to form a single trunk⁽¹⁵⁾ but in our case they did not unite and had a separate course throughout the arm and forearm. Vare and Bansal reported a case with high division of brachial artery in which the superficial one is the brachial artery and deeper that continues in forearm is the interosseous complex⁽¹⁴⁾ whereas in our case both the radial and ulnar arteries given off by brachial artery are superficial. Shewale et al studied a case in left upper limb in which the brachial artery terminated at the lower border of the teres major with the radial artery arising laterally and radial and ulnar arteries ran superficially in the arm.⁽¹⁶⁾ In our case the high termination was in right arm and the radial artery took origin medially from the brachial artery.

Vishal Kumar reported a case of high division of brachial artery into medial and lateral branches, 9.5 cm distal to the lower border of teres major muscle contrary to 3.5 centimetre distal in our study. The branches crossed over in the distal arm and lateral branch trifurcated near pronator teres below the cubital fossa⁽¹⁷⁾ whereas in our case the terminal branches remained separate.

Udyavar A observed that the brachial artery divided into radial and ulnar arteries and common interosseous artery was a branch from the radial artery.⁽¹⁸⁾ This is contrary to our case in which ulnar artery gave off the common interosseous artery. Puspaltha M reported bilateral high divisions of the

brachial artery⁽¹⁹⁾ whereas we encountered the variation unilaterally on right side.

Tortuous radial artery is one of the causes of access failure in transradial approach of coronary interventions.⁽²⁰⁾ In our study we observed loops and acute bends of the radial and ulnar arteries which may occlude the vessels causing ischemia. Variations in this study are significant because high termination of brachial artery with kinked origin of radial and ulnar arteries running a tortuous course may result in clinical emergency if medical personals are unaware of this type of anomaly.

Embryological Basis: Variations of the arterial tree of the upper limb are because of developmental persistence or obliteration of any part of the axis artery.⁽²¹⁾ During embryogenesis the seventh cervical intersegmental artery gives rise to arteries of the upper limb. It commences as the brachial artery distal to lower border of teres major and as the interosseous artery in the cubital fossa. The radial and ulnar arteries develop from axis artery late in the development. Early in development the radial artery arises proximally and crosses superficial to the median nerve. Subsequently, the radial artery joins the main trunk at the level of the origin of the ulnar artery and thus both arteries arise at the same level. Normally, superficial or upper branches of radial artery are arrested developmentally due to hemodynamic predominance resulting in the deeper part persisting as the radial artery. In our case the deep part regressed and the superficial part persisted giving rise to superficial radial artery.⁽²²⁾ Also, brachial artery divided at a higher level after a short course. Cause for this may be haemodynamic arrest. A capillary plexus is also found in the early stages of development which eventually differentiates into definitive blood vessels.⁽²³⁾ Interruption in the stages of these plexus can also lead to the present case.

Conclusion

Anatomical knowledge of these variations has many clinical implications especially in surgeries related to orthopaedic and vascular re-constructive procedures. With cardiac interventions gaining popularity through upper limb vessels, identifying these tortuous and anomalous vessels becomes very essential to avoid any complication. These variations are also significant for radiologists for interpreting angiographic images and carrying out diagnostic as well as therapeutic interventions. This type of high origin, superficial and tortuous course of ulnar and radial arteries make them more susceptible to trauma during catheterization and faulty blood pressure measurement.

References

1. Standring S. Grays Anatomy. The Anatomical Basis of Clinical Practice. Edinburgh: Churchill Livingstone, 39th edn. 2005:856. Yalcin B, Kocabiyc N, Yazir F et al.

- Arterial variations of upper extremities. Anat Sc International 2006;81(1):62-64.
2. Singh H, Gupta N, Bargotra RN, Singh NP. Higher bifurcation of brachial artery with superficial course of radial artery in forearm: case report. JK Science. January-March 2010; 12(1); p. 39-40. 22.
3. Okaro IO, Jiburum BC. Rare high origin of radial artery: A bilateral symmetrical case. Nigerian J Surgical Research 2003;5(1-2):70-72.
4. Ozcan H, Oztekin PS, Zegeroglu AM, Ersöz G, Fiçıcılar H, Ustüner E. Doppler ultrasound evaluation of the structural and hemodynamic changes in the brachial artery following two different exercise protocols. Diagn. Interv. Radiol. 2006; 12(2) p. 80-84.
5. Cherukupuli C, Dwivedi A, Dayal R. High bifurcation of brachial artery with acute arterial insufficiency: A case report. Vascular Endovascular Surg. 2008;41(6):572-74.
6. Hazlett JW. The superficial ulnar artery with reference to accidental intra-arterial injection. Can Med Assoc J. 1949;61:289-293.
7. Teli C, Kate NN, Paarthipan N. High division and variation in brachial artery branching pattern. IOSR Journal of Dental Medical Sciences. 2013; 3(6), p. 68-70.
8. Natasis K, Papadopoulou AL, Paraskevas GT, Tsikaras P. High origin of a superficial ulnar artery arising from axillary artery - Anatomy, embryological and clinical significance and review of literature. Folia Morphol (Warsz) 2006;65:400-405.
9. Mehta V, Arora J, Suri RK, Rath G. Unilateral anomalous arterial pattern of human upper limb- Anatomical description and clinical implications. Sultan Qaboos University Medical Journal. July 2008; 8(2). p. 227-230.
10. Keen JA. A study of arterial variations in the limbs with special reference to symmetry of vascular pattern. Am J Anat. 1961;108:245-61.
11. Rodriguez-Niedenfuhr M, Vazquez T, Nearn L, Ferreyra B, Parkin I, Sanudo JR. Variations of the arterial pattern in the upper limb revisited: a morphological and statistical study, with a review of the literature. J Anat. 2001;199:547-566.
12. Adachi B. Das Arterien system des japaner (The arterial system of the Japanese). Kyoto. 1928;1:205-210.
13. Mitra B, Sadhu A, Meyur R, Sarkar S. High up division of brachial artery into laterally placed ulnar artery and medially placed radial artery. Int J Anat Var. 2013; 6. p. 64-65. 19.
14. Vare AM, Bansal PC. A case of anomalous brachial artery and other associate vascular anomalies in a single upper limb. Journal of Anatomical society of India 1969;18(2):50-5.
15. Williams PL, Bannister LH, Berry M.N, Collins P, Dyson M, Dussek JE, Ferguson MWJ. Gray's Anatomy. Cardiovascular system 38th Edn. Churchill Livingstone, New York, 1995, pp1538-1540.
16. Shewale SN, Sukre SB, Diwan CV. Bifurcation of brachial artery at its commencement-A case report. Biomed Res 2012;23(3):453-456.
17. Vishal Kumar and Pretty Rathnakar. Unilateral High Division of Brachial Artery: A case report and literature review. Nujhs Vol. 4, No.3, September 2014, 115-118.
18. Udyavar A. Anomalous termination of the brachial artery. J Anat. Soc. 2004;53:41.
19. Puspaltha M, Haq I. Bilateral high divisions of the brachial artery - a case report. Anatomica Karnataka. 2010;4(1).p. 59-61.
20. Elizabeth Bazemore, BS and J. Tift Mann, III, MD Problems and complications of the transradial Approach

- for Coronary Interventions: A review. Volume 13 - Issue 5 - May, 2005.
21. Rodriguez-Baeza A, Nebot J, Ferreira B, Reina F, Perez J, Sanudo JR, Roig M. An anatomical study and ontogenic explanation of 23 cases with variations in the main pattern of the human brachio-antebrachial arteries. *J Anat.* 1995; 187: 473–479.
 22. Singer E. Embryological patterns persisting in the arteries of the arm. *Anat Rec.* 1933;55:406-413.
 23. Kachlik D, Konarik M, Baca V. Vascular patterns of upper limb: An anatomical study with accent on superficial brachial artery. *Bosnian journal of basic medical sciences.* 2011; 11(1). p. 4-10.