

Incidence and pattern of rare tumors of breast in patients attending a tertiary care hospital in North India

Aneeta Singh Malhotra^{1,*}, Bawana Raina², Swati Gupta³, Arvind Khajuria⁴, Kuldeep Chander Goswami⁵

^{1,2}Associate Professor, ³Assistant Professor, ⁴Professor & HOD, ⁵Professor, Dept. of Pathology, ASCOMS, J&K

***Corresponding Author:**

Email: aneetasinghmalhotra@gmail.com

Abstract

Introduction: Breast tumors comprise a vast collection of different entities characterized by varied biological and pathological features, clinical profile and behaviour. Breast lesions are diverse and vary from simple fibroadenomas to various common carcinomas like infiltrating ductal carcinomas to rarer entities such as angiosarcoma, pleomorphic variant of lobular carcinoma, medullary carcinoma, tubular carcinoma, malignant phylloides etc.

Aim and Objectives: To study the incidence of neoplastic breast lesions and to evaluate the incidence of rare breast lesions in a tertiary care hospital along with the clinicopathological co-relation of the same.

Materials and Method: A three year prospective as well as retrospective study of all breast specimens received during the period from June 2013 to June 2016 was carried out. The necessary information and clinical data was obtained from the concerned sections.

Results: A few rare entities like malignant phylloides, schwannoma, leiomyosarcoma, angiosarcoma, lymphoma were identified.

Keywords: Breast, Lobular Carcinoma, Medullary Carcinoma.

Introduction

The breast is an important organ in the female body because of the psychological impact it has on an individual's mind. Almost all women experience breast changes which could be subtle to alarming at some point in their lives. Lesions in the breast vary from the most common and benign conditions such as fibroadenomas to various common carcinomas such as infiltrating ductal carcinomas to rarer entities like angiosarcoma, malignant phylloides tumor, leiomyosarcoma etc.⁽¹⁾

Aims and Objectives

1. To study the incidence of various neoplastic lesions of the breast.
2. To evaluate the incidence of rare breast entities in a tertiary care hospital along with clinicopathological correlation of the same.

Materials and Method

The present study was prospective as well as retrospective which included – cases from June 2013 to June 2016, i.e.; a period of three years. All the breast cases, irrespective of the sex and age of the patient were included. There were no exclusion criteria. Specimens were received and preserved in 10% formalin. Detailed gross examination was done for each specimen and histopathological features were studied to classify neoplasms according to the WHO classification 2003.⁽²⁾ For the retrospective cases we identified blocks and got fresh sections cut. Clinical details were retrieved from our records section for every case. Sections were stained

with hematoxylin and eosin. A morphological diagnosis was arrived at, based on the microscopic analysis.

Results

A total of 225 breast specimens received in different forms such as excisional biopsies, modified radical mastectomies, simple mastectomies and tru-cut biopsies were included in the present study. Total 210 breast neoplasms were studied, where the incidence of benign neoplasms was 56.19% (118 cases) and of malignant neoplasms was 43.8% (92 cases). The most common benign neoplasm was fibroadenoma (81.3%) while invasive ductal carcinoma not otherwise specified (85.8%) was the most common malignant tumor.

Among the benign lesions fibroadenoma, benign phylloides, tubular adenoma, lipoma, leiomyoma and neurofibroma were seen.

While invasive ductal carcinoma not otherwise specified was commonest malignancy (85.8%) as expected, three cases of invasive lobular carcinoma (ILC) were also seen. All were of classic type. Two cases of medullary and one case of mucinous carcinoma were reported. One case each of tubular carcinoma, apocrine carcinoma and papillary carcinoma were also encountered. Two cases of occult breast carcinoma were identified wherein no tumor was detected in the mastectomy specimens but lymph nodes showed metastatic deposits. Among the stromal tumors, one case of leiomyosarcoma, one of malignant phylloides, and a case of angiosarcoma were also encountered. Also a case of primary breast lymphoma was reported.

Table 1: Year wise distribution of breast biopsy cases with incidence of benign and malignant neoplasms

Year	Total breast biopsies	Benign neoplasms	% of total biopsies	Malignant neoplasms	% of total biopsies
2013-14	79	42	53.16	36	45.5
2014-15	70	34	48.57	32	45.7
2015-16	76	42	55.26	24	31.57
	225	118	52.4	92	40.88

Table 2: Age and Sex distribution in Benign Neoplasms

Age in years	Female		Male		Total Cases
	No. of cases	%	No. of cases	%	
0-10	-	-	-	-	-
11-20	3	2.5%	-	-	3
21-30	35	29.6%	-	-	35
31-40	32	27.1%	-	-	32
41-50	30	25.4%	-	-	30
51-60	12	10.16%	-	-	12
61-70	06	5.08%	-	-	06
71-80	-	-	-	-	-
Total	118	100%	-	-	118

Table 3: Age and Sex distribution in malignant neoplasms

Age in years	Female		Male		Total Cases
	No. of cases	%	No. of cases	%	
0-10	-	-	-	-	-
11-20	-	-	-	-	-
21-30	03	3.3	-	-	3
31-40	04	4.4	-	-	4
41-50	22	24.7	1	33.3%	23
51-60	32	35.9	-	-	32
61-70	24	26.9	2	66.6%	26
71-80	04	4.4	-	-	4
Total	89	100%	03	100%	92

Table 4: Incidence of various histological types of malignant breast neoplasms

S. No.	Type of Neoplasm	Sex		Total Cases	Percentage
		Male	Female		
I. Epithelial tumors					
a)	Invasive ductal carcinoma:NOS	3	76	79	85.8%
b)	Invasive lobular carcinoma	-	3	3	3.25%
c)	Tubular carcinoma	-	1	1	1.086%
d)	Apocrine	-	1	1	1.086%
e)	Medullary	-	2	2	2.17%
f)	Mucinous	-	1	1	1.086%
g)	Papillary	-	1	1	1.086%
II. Mesenchymal tumors					
h)	Leiomyosarcoma	-	1	1	1.086%
i)	Angiosarcoma	-	1	1	1.086%
III. Fibroepithelial tumors					
j)	Malignant Phylloides	-	1	1	1.086%
IV. Malignant Lymphoma					
		-	1	1	1.086%
Total				92	100%

Discussion

Worldwide breast cancer is the most common invasive cancer in women with approximately 1.5 lakh new cases and 70,218 deaths being reported annually in India.⁽³⁾

In the present study 210 cases of breast neoplasm were reported during the three year period from June 2013 to June 2016 in the department of pathology. A total of 225 breast biopsy specimens were received that also included some non-neoplastic and inflammatory conditions. Among the neoplasms, 118 were benign and 92 were malignant. The incidence of various histological types of malignant neoplasms was 43.8%.

Breast cancer is strongly related to age with only 5% of all breast cancers occurring in women under 40 years of age. In our study the incidence of breast cancer in women below 40 years was 7.7%, while it increased as the age of women increased.

In the present study 92 cases of malignant breast neoplasms were studied. A histomorphological diagnosis was established for each case based on the microscopic features. Invasive (or infiltrating) ductal carcinoma was the most common type of carcinoma reported, occurring in 79 out of the 92 cases and thereby accounting for an incidence of 85.8% which is comparable to other reported studies.⁽⁴⁾ Other histological variants of invasive breast carcinoma that we encountered were medullary carcinoma, mucinous carcinoma, tubular carcinoma, apocrine carcinoma, papillary carcinoma, metaplastic carcinoma, secretory carcinoma, inflammatory carcinoma and carcinoma with neuroendocrine features.⁽¹⁾

We now discuss the rare cases that we encountered with a very brief review of the published work.

Invasive lobular carcinoma: Three cases of invasive lobular carcinoma were reported accounting for 3.25 % of the incidence amongst all breast neoplasms. The incidence of invasive lobular carcinoma is approximately 10% in the published series.⁽⁵⁾ The most common type is classic lobular carcinoma while the other types are pleomorphic, signet ring, tubulolobular. Classic type is characterized by the presence of small and uniform tumor cells, growing singly in Indian file and in concentric fashion around lobules involved by the in situ lobular neoplasia.⁽¹⁾

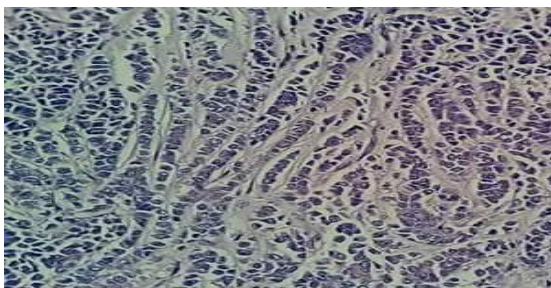


Fig. 1: Small, uniform tumor cells arranged in Indian file fashion (40X, H&E)

Medullary carcinoma: Medullary carcinomas account for less than 5% of invasive breast carcinoma.⁽⁶⁾ Two cases of Medullary carcinoma were encountered in the present study (2.17%).

The first case that we reported was a 65 year old woman with lump in the left breast for which she underwent simple mastectomy. Grossly, it was well circumscribed, measured 6 x 5 cm in diameter. Its cut surface was solid, homogeneous and gray with a small foci of necrosis. No lymph node was resected. The other case was a 50 year old woman who presented with a lump in right breast. Grossly, the mass we received was 3x4cm with 5 lymph nodes. Microscopic examination revealed metastatic deposits in two lymph nodes. Microscopically the borders are always of the “pushing” type. The pattern of growth is diffuse with ductal differentiation or intra ductal growth and absence of mucin secretion. The tumor cells are large, pleomorphic, with large nuclei, prominent nucleoli and numerous mitosis. The cell borders are indistinct hence this gives a syncytial or sheet like appearance. A very important component is lymphoplasmacytic infiltration at the periphery of the tumor which is basically a reaction of the host to the neoplasm. Medullary carcinoma appears mostly in patients under 50 years of age and is common in Japanese women.^(1,7) It is also said to be commonly associated with BRCA1 mutations. The prognosis for medullary carcinoma is better than for ordinary invasive ductal carcinoma.⁽¹⁾ While in one study⁽⁷⁾ the authors concluded that there was no overt favourable prognosis of medullary carcinoma when compared to invasive ductal carcinoma. Prognosis is more closely related to stage than histological subtyping.

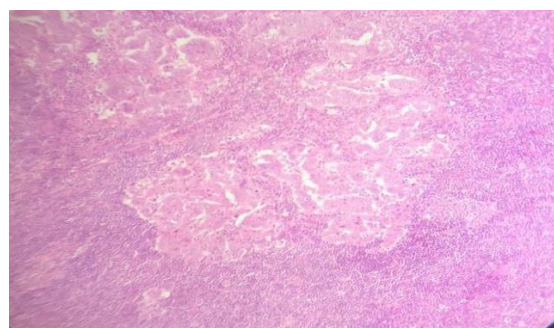


Fig. 2: Tumor cells arranged in syncytial pattern, separated from surrounding stroma by dense lymphocytic infiltrate (10X, H&E)

Mucinous carcinoma: Mucinous carcinoma usually occurs in post-menopausal women.⁽¹⁾ It is a rare type of invasive breast tumor formed by mucus secreting glands. We reported one case of mucinous carcinoma accounting for an incidence of 1.086%. It accounts for 1% to 7% of all breast cancers and generally bears better prognosis than other types of breast cancer.⁽⁸⁾ Our case presented with a lump in her left breast measuring 5x5cm. On cut section of the received specimen cystic areas were

present filled with mucoid material, eight lymph nodes were sampled however no lymph node involvement was seen. Grossly, the mucinous carcinoma is well circumscribed and crepitant to palpation. Foci of hemorrhage are frequent. Microscopically the classical description is of small clusters of tumor cells "floating in a sea of mucin". The mucin is extracellular, and may be of acid or neutral type.⁽¹⁾ Pure mucinous carcinoma is associated with a very low incidence of nodal metastases and has an excellent short term prognosis, especially when the tumor measures less than 3 cm in diameter.⁽¹⁾ Pure mucinous carcinoma generally has a less aggressive growth pattern.⁽⁹⁾

Invasive papillary Carcinoma: We reported one case of invasive papillary carcinoma in a 70 year old woman (1.086%). Invasive papillary carcinoma of breast represents approximately 0.5% of all the newly diagnosed cases of breast cancer.⁽¹⁰⁾ Our findings correlated with a study⁽⁷⁾ which reported a somewhat similar incidence of percentage. Microscopically, there were dilated ducts which were lined by neoplastic cells arranged in papillary pattern of growth.

Tubular Carcinoma: A case of tubular carcinoma was diagnosed in a 50 year old woman, presenting with a lump in the left breast. Invasive tubular carcinoma is a rare tumor of breast, having an excellent prognosis. Grossly, the tumor was 1.5 cm in diameter, poorly circumscribed and hard in consistency. Microscopically, the tumor had irregular and angulated contour. Axillary metastasis occurs in 20% patients. Breast preservation is a safe treatment for tubular carcinoma. In a study on 105 cases of tubular carcinoma of the breast, the authors suggested that the lesions which are composed of 90% or more of tubular carcinoma may be treated by simple mastectomy and axillary dissection is not necessary. Also they concluded that there was no difference in the presentation or outcome of pure versus mixed tubular carcinoma, the overall mortality was 2%.⁽¹¹⁾ The lymph node status did not influence disease free or overall survival.⁽¹²⁾

Angiosarcoma breast: A single case of angiosarcoma was reported accounting for 1.086% of the incidence among all malignant breast neoplasms. Mammographically, it presented as a solitary mass. Grossly, the tumor was soft, spongy and hemorrhagic. Microscopically, there was presence of anastomosing vascular channels which were lined by atypical endothelial cells. The prognosis of angiosarcoma is poor with most patients developing metastases through the blood stream. A study has shown that a good correlation exists between microscopic grade and outcome.⁽¹³⁾

Schwannoma breast: A case of schwannoma breast was reported which was initially presumed to be phylloides tumor. A 37 years old lady presented with a lump in right breast that was growing slowly over a period of 8 years. Grossly, it presented as a well encapsulated nodule. Microscopic evaluation showed an encapsulated spindle cell tumor with prominent nuclear palisading and

features typical of a Schwannoma. There was also strong and diffuse positive staining of S-100, favouring the diagnosis of Schwannoma. Schwannomas are mostly benign tumors that tend to favour nerves in the head and neck as well as the extremities.^(14,15) Schwannomas are though the most common peripheral nerve sheath tumors, their occurrence in the breast is rare. A review of literature shows only 28 cases of benign breast Schwannoma.^(14,15)

Leiomyoma: A single case of Leiomyoma breast was reported. Leiomyoma most commonly occurs in the uterus, small bowel, esophagus and is a rare non-epithelial tumor of the breast.⁽¹⁶⁾ A 46 year old woman revealed a well-defined 5 cm nodule in the upper outer quadrant of the left breast. Grossly, the nodule was well circumscribed, homogenous, firm, white measuring 5x5x3 cm. Microscopic examination revealed fascicles of spindle cells that had no atypia. These spindle cells had ovoid nuclei with delicate chromatin and small inconspicuous nucleoli and eosinophilic cytoplasm. The tumor is immune-histochemically positive for α -SMA (smooth muscle actin).^(1,16)

Primary Leiomyosarcoma: Primary breast sarcomas are very rare tumors that originate from the mesenchymal tissue of the breast. In a study conducted by the Mayo clinic, its prevalence among breast cancers was found to be 0.0006%.⁽¹⁷⁾ A case of Leiomyosarcoma in a 58 years old woman was reported in our study. A well circumscribed nodule measuring 10 cms was present in the upper outer quadrant of the right breast. There was evidence of malignancy on fine needle aspiration biopsy. The patient underwent total mastectomy of the right breast with axillary lymph node dissection. Grossly, we received a necrotic tumor mass measuring 11x9x6cm in size with invasion in the overlying skin. Microscopically, the tumor was composed of pleomorphic spindle cells showing frequent mitosis and necrosis. Immunohistochemical staining was positive for smooth muscle actin (SMA). None of the 25 excised lymph nodes exhibited tumor metastasis, the surgical margins showed no trace of tumor. Leiomyosarcoma of the breast is thought to originate from the muscular blood vessels or from the smooth muscle of the nipple.⁽¹⁷⁾ It is impossible to diagnose leiomyosarcoma pre-operatively.⁽¹⁸⁾ The prognosis of leiomyosarcoma is better than that of other breast sarcomas.^(1,19) They require long term follow up because local recurrence and distant metastasis can occur long after operation.⁽¹⁹⁾

Neoplastic Lesions of Male Breast: Four cases of gynaecomastia were reported which is defined as the enlargement of the male breast. Three cases of male breast malignancies were reported in the present study. It has been mentioned in texts that the incidence of male breast carcinoma is less than 1% of all breast cancers.⁽¹⁾ All the cases were of invasive ductal carcinoma not otherwise specified type. In a study of 50 cases of male breast carcinoma, all the cases (100%) were invasive ductal carcinoma not otherwise specified type.⁽²⁰⁾

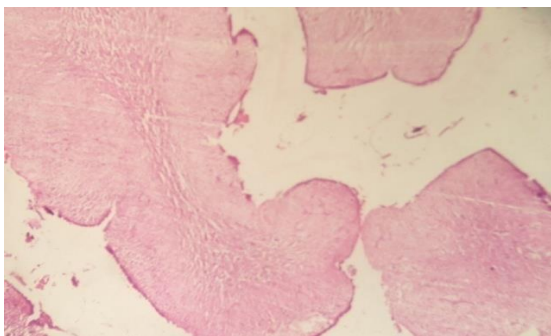


Fig. 3: Phyllodes tumor: Nodules of proliferating stroma covered by epithelium. Increased proliferational cellularity giving rise to typical leaf like architecture (10X, H&E)

Summary and Conclusions

1. There were a total of 225 breast biopsies in the three years. Out of these 210 were breast neoplasms. Out of which 118 were benign breast neoplasms (56.19%) while 92 were malignant breast neoplasms (43.8%).
2. The most common benign neoplasm was fibroadenoma.
3. Among the malignant neoplasms invasive ductal carcinoma not otherwise specified was the most common (85.8%)
4. We reported some rare breast lesions namely, malignant phylloides, leiomyosarcoma, angiosarcoma, schwannoma and lymphoma.

References

1. Rosai J, *Rosai and Ackerman's Surgical Pathology*, 10th edition Edinburgh Mosb, 2004.
2. Tavassoli F A, Devilee P (Eds).-World Health Organisation classification of the neoplasms. Pathology and Genetics of Neoplasms of the Breast and Female Genital Organs. *IARC press*: Lyon,2003.
3. *Globocan 2012*: Estimated cancer incidence, mortality and prevalence worldwide in 2012.
4. Bane A. L., Beck J.C., Bloiweiss I., Buys S. S., Catalano E., Daly M. B., et al. BRCA2 Mutation associated Breast Cancers exhibit a distinguishing phenotype based on morphology and molecular profiles from tissue microarrays. *Ann J Surg Pathol* 31:121-128, 2007.
5. Dossus L and Benusiglio P R. Lobular Breast Cancer: Incidence and genetic and non-genetic factors. *Breast Cancer Research* 17:37, 2015.
6. Santosh T, Bal A K, Patro M K, Choudhury A. Medullary Breast Carcinoma : A Case Report and review of literature. *J Cancer Sci Ther* 7:142-144, 2015.
7. Samir S.M., Fayaz M.S., Elbasmi A et al. Medullary carcinoma of the breast, ten years clinical experience of the Kuwait cancer control centre. *Gulf Oncol* 1:45-52,2011.
8. Ha K Y, Leon P D, Leon W D. Invasive mucinous carcinoma of the breast. *Proc (Bayl Univ. Med Cent)* 26(3):295-97,2013.
9. Ishikawa T., Hamaguchi Y., Ichikawa Y., et al. Locally advanced mucinous carcinoma of the breast with sudden growth acceleration: a case report. *Jpn J Clin Oncol* 2002,32:64-67.
10. Pal S K, Lau S K, Kruper L, Nwoye U, Garberglio C, Gupta R K, Paz B, Vora L, Guzman E, Artinyan A, Somlo G. Papillary carcinoma of the breast: An overview. *Breast Cancer Res Treat* 122(3):637-645,2010.
11. Fedko M G, Scow J S, Shah S S, Reynolds C, Degnim A C, Jakub J W, Boughey J C. Pure Tubular carcinoma and axillary nodal metastases. *Annals of Surg Oncol*;17 (338-42), 2010.
12. Cabral A.H., Recine M, Paramo J.C., Mc Phee M.M., Poppiti R, Mesko T.W. Tubular carcinoma of the breast: an institutional experience and review of the literature. *Breast J* 9:298-301,2003.
13. Bennani A, Chbani L, Lamchahab M, Wahbi M, Alaoui F F, Badioui, Melhouf M, Amarti A. Primary Angiosarcoma of the breast: a case report. *Diagnostic Pathology* 8:66;2013.
14. Dialani V, Hines N, Wang Y, Slanetz P. Breast schwannoma: case report. *Case Reports in Medicine Volume* 2011; 1-3, 2011.
15. Balci P, Pekcevik Y.T, Caferova S, Canda T, Seveine A, Saydam S. A case of benign schwannoma of the breast: mammographic, ultrasonographic and color Doppler ultrasonographic findings. *Breast J* 2009;15:417-418.
16. Koirala K, Shrestha M.L., Chalise P.R., Shrestha B.B., Shrestha R. Leiomyoma of the breast: a case report of rare case. *Nepal Med Coll J* 2008,10(3): 207-8.
17. Adem C, Reynolds C, Ingle J.N., Nascimento A.G. Primary breast sarcoma: clinicopathologic series from the Mayo clinic and review of the literature. *Br J Cancer* 2004,91:237-41.
18. Jayaram G, Jayalakshmi P, Yip C.H. Leiomyosarcoma of the breast: report of a case with fine needle aspiration cytologic, histologic and immunohistochemical features. *Acta Cytol* 2005,49:656-60.
19. Shinto O, Yashiro M, Yamada N, Matsuoka T, Ohira M, Ishikawa T et al. Primary leiomyosarcoma of the breast: report of a case. *Surg Today* 2002,32:716-9.
20. Fonseca R.R., Tomas A.R., Andre S., Soares J. Evaluation of ERBB2 gene status and chromosome 17 anomalies in male breast cancer. *Am J Surg Pathol.* 30:1292-1298,2006.