

Role of FNAC in the diagnosis of Head and Neck Lesion: A study from Garhwal region, Uttarakhand

Arvind Kumar^{1,*}, Sheela Choudhary², Deepa Hatwal³, Neha Batra⁴, S.K. Barpanda⁵

^{1,4}Assistant Professor, ²Professor, ^{3,5}Associate Professor, Dept. of Pathology, Veer Chandra Singh Garhwali Govt. Medical Science & Research Institute

***Corresponding Author:**

Email: drarvindkumar10@gmail.com

Abstract

Background and Objectives: The present study was intended to study the spectrum of disease by aspiration cytology as well as evaluating its diagnostic utility in palpable head and neck lesion of Garhwal population in Uttarakhand.

Materials and Method: Retrospective study conducted on 796 patients presented with palpable head and neck mass. FNAC procedure was done using 23-24 G needle. Smears were stained by Giemsa and Pap smear and special stains.

Results and Conclusion: Most common clinical presentation was cervical lymphadenopathy 67.8% and lesion was reactive lymphoid hyperplasia 33.3%. Metastatic carcinoma in cervical lymph node 58.57% was noted in majority of patient suffering from malignancy. FNAC proved to be fast, cost effective and reliable procedure for prompt diagnosis.

Keywords: FNAC, Head and Neck, Malignant Lesion, Cost Effective.

Introduction

Palpable head and neck lesion varies from benign to malignant in nature. A wide age group is involved from 1 to 95 years of age.⁽¹⁾ It is also a common site for metastatic deposit. In that situation especially when financial resources are limited, early detection with reliable diagnostic technique is needed. Fine needle aspiration cytology (FNAC) is an effective diagnostic tool in the diagnosis of head and neck masses.^(2,3) It is a safe, inexpensive, well tolerated and rapid procedure that categorizes the lesions.⁽⁴⁾ Follow up of cancer patient can easily be done by FNAC.⁽⁵⁾ FNAC is the only procedure for those patient that cannot with stand for small open biopsy.⁽⁶⁾

This is a first ever study from Garhwal region, Uttarakhand that evaluate the diagnostic value of FNAC as well as pattern of disease affecting head and neck masses.

Aims and Objectives

To study the utility of FNAC in the diagnosis of clinically suspected Head and Neck lesion and to evaluate pattern of disease in Garhwal region, Uttarakhand.

Materials and Method

Present study is a retrospective hospital based study in a span of five year duration from December 2010 to January 2015. FNAC was carried out on 796 patients that had clinically Head and Neck lesion in the department of Pathology, corresponding cytology slides were retrieved and reviewed from the archives of department of Pathology. Routine FNAC procedure was done using 23-24G needle. Smears were stained by Giemsa and Pap stain and special stains were carried out as and when

required. All clinical data were received from medical records.

Results

Over a period of five years total 796 cases with clinically palpable head and neck masses underwent FNAC procedure. Age ranges from 3 months to 82 years and male to female ratio was 1.3:1. Of the 796 cases, 592 cases were of lymphadenopathy, with age range from 18 to 82 yrs. and male to female ratio was 1:1.03, 110 cases of thyroid with age ranges from 4 to 70 yrs. and male to female ratio was 1:2.4, 34 cases of salivary gland age ranges from 28 to 60 yrs. with male to female ratio 1.8:1 and 60 of miscellaneous category. Age ranges from 12 to 57 yrs. with male to female ratio was 1.3:1. (Fig. 1)

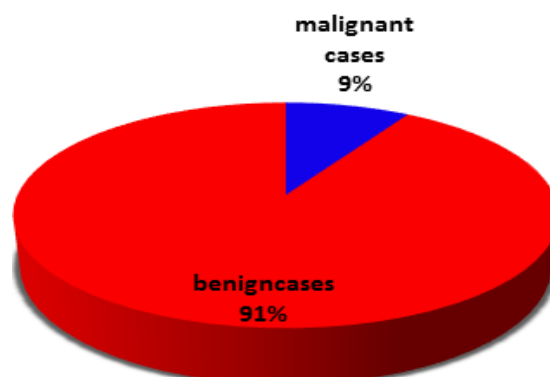


Fig. 1: Frequency of benign and malignant lesion

Lesions were broadly categorized in to benign 726 (91.20%) and malignant lesion 70(8.79%) (Fig. 2). Malignant lesions included lymph node malignancy that comprised of both 52(74.28%) metastatic lesion and lymphoma, thyroid neoplasm 15 (21.42%) and salivary gland tumor 3(4.28%). Further malignant lesions (n=70)

were grouped in to primary 29(41.43%) and secondary lesions 41(58.57%). Age ranges in primary lesions from 18 to 74 yrs. with male to female ratio 4.5:1. Age ranges in secondary lesions from 28 yrs. to 82 yrs. with 5.8:1 male to female ratio.

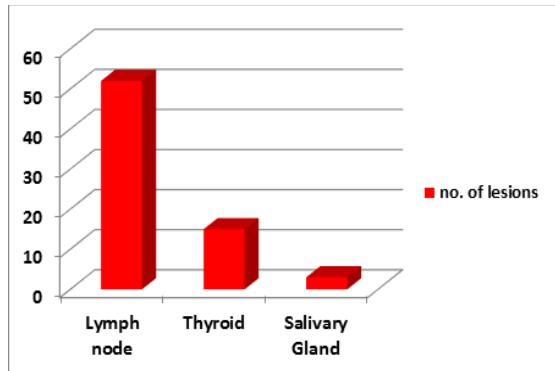


Fig. 2: Distribution of malignant lesion in relation to site

Clinically lymphadenopathy came up as the most common 540 (74.38%) benign lesion (n=726) in the head and neck region. Among this reactive lymphoid hyperplasia 180(33.33%) was the most common lesion followed by granulomatous lymphadenitis (AFB-ve), 160(29.62%), tuberculous lymphadenitis (AFB+ve), 140(25.92%) and abscess (AFB-ve) 60(11.11%). In these lesions age ranges from 7 month to 85 yrs. of age and male to female ratio varies from 1:1.2 to 1.4 that is female preponderance seen except in reactive lymphadenitis in which male to female ratio was 1.36:1. Occurrence of benign lymph node lesion were high in age group of 1-25yrs, these are tuberculous lymphadenitis 66(47.10%), granulomatous lymphadenitis 72(45.00%) and reactive lymphadenitis 112(62.20%). However incidence of abscess 26(43.0%) was more seen in age group 25-50 yrs. followed by age group 1-25 yrs. (Table 1).

Table 1: Incidence of tuberculous, granulomatous, suppurative and reactive lymphadenopathy in relation to age

Age group	Tuberculous lymphadenitis N=140				Granulomatous lymphadenitis N=160				Suppurative lymphadenitis N=60				Reactive lymphadenitis N=180			
	M	F	T	%	M	F	T	%	M	F	T	%	M	F	T	%
1-25yr	26	40	66	41.7	38	34	72	45.0	12	12	24	40.0	69	43	112	62.2
26-50yr	22	30	55	39.2	20	36	56	35.0	12	14	26	43.3	21	33	54	30.014
51-75yr	10	8	18	12.8	14	18	32	20.0	4	6	10	16.6	14	-	14	7.7
>75yr	4	-	4	2.8	-	-	-	-	-	-	-	-	-	-	-	-
Total	62	78	140		72	88	160		28	32	60		104	76	180	

Malignant lesions of cervical lymph node (n= 52) were divided in to in four age groups as 1 to 25, 26 to 50, 51 to 75 yrs. and more than 75 yrs. of age. Thirty two (61.50%) patient fall in 51 to 75 yrs. of age group followed by 26 to 50 age group. Male to female ratio was 3.7:1 (Table 2). Of the malignant lesions (n=52), 11 cases (21.15%) were of lymphoma and 41 cases (78.84%) were metastatic. In all metastatic lymph node cases (n=41,) majority of metastatic lymph node cases were from squamous cell carcinoma 34(82.92%) followed by metastatic adenocarcinoma cases 5(12.19%) and metastatic papillary carcinoma of thyroid 2(4.87%).

Table 2: Distribution of malignant lesion of cervical lymph node in male and female

Age group/sex	M	F	Total	%
1-25yr	3	-	3	5.7
26-50yr	9	3	12	23.0
51-75yr	25	7	32	61.5
>75yr	4	1	5	9.6
Total	41	11	52	100
M:F	3.7	1		

Of the thyroid lesion (n=110), colloid goiter with and without cystic change (n=35) along with adenomatous goiter (n=15) 50 (45.45%) constituted majority of thyroid lesion followed by thyroiditis mainly Hashimoto's thyroiditis 30(27.27%) and thyroglossal cyst 15(13, 60%) (Table 3). Age ranges from 4yrs to 70yrs with female predominance. Male to female ratio was 1:2.5.

Table 3: Frequency of lesion

Lymph node N=592	No.	%	Thyroid N=110	No.	%	Salivary gland N=34	No.	%	Miscellaneous N=60	No.	%
Reactive	180	30.4	Colloid goiter	25	45.4	Pleomorphic adenoma	8	23.5	Benign cystic lesion	44	73.3
			Adenomatous goiter	15							
Granulomatous (AFB-ve)	160	27.0	Thyroiditis	30	27.7	Warthin tumor	4	11.7	Lipoma	10	16.6
Tuberculous (AFB+ve)	140	23.6	Thyroglossal cyst	15	13.6	Benign epithelial lesion	5	14.7	Hemangioma	6	10.0
Abscess(AFB-ve)	60	10.1	Papillary ca of thyroid	9	8.1	Malignant salivary gland lesion	3	8.8	-	-	-
Lymphoma	11	1.8	Follicular neoplasm	6	5.4	Act sialadeniti	6	41.1	-	-	-
						Chr sialadenitis	8				

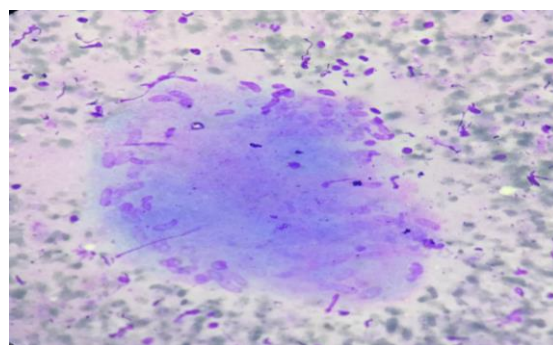
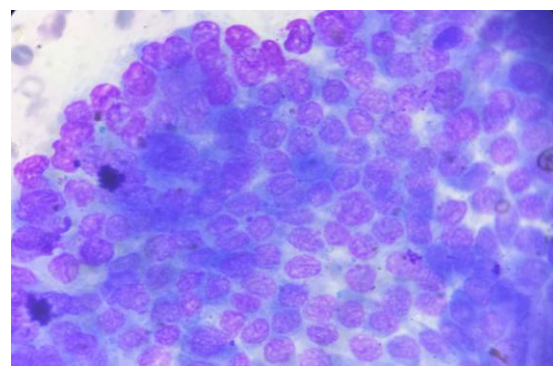
Age group 26-50yrs was frequently affected by the thyroid neoplasm that included papillary carcinoma of thyroid 9(8.10%) and follicular neoplasm 6(5.40%). Male to female ratio was 1:2 and age ranges from 28 yrs. to 75 yrs. (Table 4).

Table 4: Distribution of thyroid neoplasm according to age group

Age group	M	F	Total	%
1-25yr	-	-	-	-
26-50yr	3	4	7	46.66
51-76yr	1	4	5	33.33
>76yr	1	2	3	20.0
Total	5	10	15	
M:F	1	2		

Salivary gland lesions are not frequently seen, only 34 cases, that is 2.75% of total benign cases noted. Out of these only three (15.0%) cases turned out be malignant. Most common lesion of salivary gland was sialadenitis including both (41.10%) acute (n=6) and chronic sialadenitis (n=8) 14. Commonest tumor was pleomorphic adenoma 8(23.50%) followed by Warthin's tumor 4(11.70%) (Table 3). Age ranges from 28 yrs. to 60 yrs. with male and female ratio 1.8:1. Malignant lesion of salivary gland showed male gender inclination. Age ranges from 55 to 72 yrs.

Miscellaneous lesion (n=60) group was third in incidence after lymphadenopathy and thyroid gland lesion group. Lesions with frequency were benign cystic lesion 44(73.33%), lipoma 10(16.60%) and hemangioma 6 (10.00%) (Table 3). Age ranges from 12 to 57 yrs. with male to female ratio 1.3:1. No malignant lesion was noted.

**Fig. 3: Photomicrograph showing aggregate of epithelioid cell with necrosis in tuberculosis (Giemsa, 1000x)****Fig. 4: Photomicrograph showing syncytial aggregate of follicular epithelial cell with nuclear grooving in papillary carcinoma of thyroid (Giemsa, 1000X)**

Discussion

In the present study out of 796 aspirations only 70 (8.79%) cases were turned out to be malignant and 726(91.20%) cases were benign. This study shows that over all the most common lesion in Garhwal population is inflammatory lesion of lymph node that included reactive lymphoid hyperplasia 180(33.33%) which is most common followed by granulomatous lymphadenitis 160(29.62%) and tuberculous lymphadenitis 140(25.92%). Reactive hyperplasia is more common in first decade of life with male

predominance. This correlates with studies done by Maria et al, and lay field and Hirachand that observed cases predominated by reactive lymphoid hyperplasia.^(4,8,9) While other studies showed cases were predominated by malignant lymphadenopathy approved by Akeel A, Anila KR and Martin MR et al.^(2,5,10) Study from Manglore by Fernandes et al. showed most common site involved is thyroid 71.31% followed by lymph node in head and neck region, this in contrast to the most of the studies.⁽¹¹⁻¹⁴⁾ In our study we noticed incidence of tuberculosis was 25.95% preceded by granulomatous lymphadenitis 29.1% which is lower than the incidence noticed by Patra AL, Sarda AK, Bandyopadhyay SN and Patel MM et al.⁽¹⁵⁻¹⁷⁾ Age group frequently involved was 1- 25 yrs. with male predilection that is in accordance with R rani, S. ahmed and Patel MM et al.⁽¹⁸⁻²⁰⁾ Age ranges from 7 month to 85 yrs. this is closer to studies by Hirachand S. and Tilak V. et al. But none of the studies showed patient less than a year is suffering from tuberculosis.^(1,9) We observed male to female ratio 1:1.4 in tuberculosis patient that in concordance with work of Ahmed T and Fernandes et al.^(21,3) In our study malignant lesion comprised of only 70 cases (8.79%) of all the head and neck cases that included lymph node, thyroid and salivary gland lesions, and miscellaneous lesion. Study by Ahmed T and Akeel A showed over all malignant cases in head and neck region 14.05 % and 50.0% respectively.^(21,10) Most common age group affected in cases of malignant lesion was 51-75 yrs. (61.5%) followed by 26 -50 (23.0%). Anderson and Ridg JA et al. were also in favor of older age group for the occurrence of malignancy.^(22,29)

In this study male preponderance was strongly noted hence male to female ratio was 3.7:1 this is in accordance to study from Meerut by R Rani.⁽¹⁹⁾ Age ranges from 18 to 82 yrs. in malignant lesion of head and neck.

Out of total malignant cases of head and neck malignant lesion of lymph node was the most common malignant lesion 74%, comprised of metastatic lesion 41(58.7%) and lymphoma 11(15.7%) and is followed by thyroid neoplasm 15(21.42%). Of the metastasis cases, squamous cell carcinoma (82.9%) was the commonest. Most of the patient had the history of alcohol consumption and smoking that can cause the cancer of head and neck.^(29,30)

Majority of cancer patient present in advanced stage (Metastatic) due to the lacking of basic education and low literacy rate. Frequency of thyroid lesions are next to lymph node lesion and our study showed male to female ratio was 1:2.5 in all thyroid lesion, while in thyroid neoplasm male to female ratio was 1:2 indicating lesion shifting to male patient. Most common lesion of thyroid was colloid/adenomatoid goiter 45.4%. Malignant neoplasm that was diagnosed only based on cytology was papillary carcinoma of thyroid 8.1% followed by follicular neoplasm 5.4%. Age range of thyroid lesion was from 11 to 75 yrs. Garhwal region is a well-known Goitre endemic area in Uttarakhand.⁽³¹⁾

According to National Family Health Survey-3 (NFHS-3) in Uttarakhand 46% of house-holds were using iodized salt.⁽³²⁾ Hence patients of colloid goiter are frequent in this region.

Studies from Gwalior by Reena et al. from Ahamdabad by Setal et al. and Prasad et al. all agreed to age group, most common lesion colloid goiter and female predominance.⁽²³⁻²⁵⁾ If we compare with these studies, our study showed less gap in between male and female ratio, hence indirectly showing increasing frequency of male patient of thyroid. Neoplastic condition of thyroid like papillary carcinoma thyroid and follicular neoplasm were only diagnosed by aspiration cytology.

Majority of salivary gland lesion was occupied by sialadenitis 41.1% and most common tumor was pleomorphic adenoma 23.5%, while study by Setal et al. stated that pleomorphic adenoma was the most common lesion encountered in salivary gland. Our study reported benign cystic lesion 73.3% followed by lipoma 16.64% that formed the majority in miscellaneous lesion category. Whereas study by Setal et al. concluded lipoma 35.0% was the predominant lesion in miscellaneous lesion category. We experienced that FNAC by experienced pathologist significantly reduces the number of avoidable excisional/incisional biopsy, this is also in accordance to study by M. jain.⁽²⁶⁾ Aspiration cytology is the effective diagnostic tool in diagnosis of head and neck mass. We required full clinical history, radiological investigation and immunocytochemistry for definitive diagnosis in few case of lymphoma and poorly differentiated metastatic carcinoma. N. gupta et al. supporting these additional diagnostic tool.⁽²⁷⁾ In our study we noticed multiple pricking from different site proved vital in the diagnosis of thyroid lesion mainly neoplasm this statement is backed up by study of el Hag IA et al.⁽¹²⁾

Cytology and histology correlation was done as per the availability of corresponding biopsy in 93 cases (11.68%). That showed over all high accuracy of FNA procedure in head and neck lesion.^(11,28)

Our experience with fine needle aspiration cytology in head and neck region in the population of Garhwal, Uttarakhand proved to be safe, trustworthy and without any complication.⁽⁴⁾ Majority of the population of this region belongs to low socio-economic background with poor transportation facility, hence cost effective and rapid investigations expected. FNAC fulfills all this requirement.^(5,12) This is a first ever study from typical hill region from Uttarakhand that casts the light on spectrum of disease, age group, sex predilection and incidence of disease in head and neck region.

Conclusion

Cervical lymphadenopathy 67.8% was the most common clinical presentation in that reactive lymphoid hyperplasia 33.3% was the leading cause.

Over all male predilection was observed except in patient of thyroid lesion. Most common malignant lesion noted was metastatic deposit in lymph node 58.57% with 51-75 yrs. of age group commonly involved. FNAC is very fast and reliable procedure for prompt diagnosis when patient presented with palpable head and neck lump. It is sensitive and specific in the diagnosing of metastatic cancer. In our study we observed FNAC is not first line diagnostic tool in differentiating between reactive lymphoid hyperplasia and lymphoma (Hodgkin Lymphoma).

References

1. Tilak V, Dhadel AV, Jain R. Fine needle aspiration cytology of the head and neck masses. *Ind J Pathol Microbiol* 2002;45(1):23-30.
2. Martin MR, Santos GC. Fine needle aspiration cytology in the diagnosis of superficial lymphadenopathy: A 5 year Brazilian experience. *Diagn Cytopathol.* 2006 Feb;34(2):130-4.
3. Fernandes H, D'Souza C R S, Thejaswani B N. The role of fine needle aspiration cytology in palpable head and neck masses. *Journal of Clinical and Diagnostic Research (serial online)* 2009 October (cited: 2009 October 5).
4. Layfield LJ. Fine-needle aspiration in the diagnosis of head and neck lesions: a review and discussion of problems in differential diagnosis. *Diagn Cytopathol.* 2007;35(12):798-805.
5. Anila KR, Nayak N, George PS, Jayasree K. Utility of Fine Needle Aspiration Cytology in evaluation of lymphadenopathy. An audit from a cancer centre in south India. *Gulf J Oncolog.* 2015 Sep(19):50-6.
6. Orell SR, Sterrett GF, Walters MN, Whitaker D. *Manual and Atlas of Fine needle Aspiration Cytology*, 5th edition. ELBS Churchill Livingstone, 2012.
7. Shaha AR. Complications of neck dissection for thyroid cancer. *Ann Surg Oncol.* 2008;15(2):397-9.
8. MariaIngoldsdottir, Viggo Balle C Christoffer Holst Hahn. Evaluation of cervical lymphadenopathy in children: *Dan Med J.*60/8. Aug 2013:1-3.
9. Hirachand S, Lakhey M, Akhter J, Thapa B. Evaluation of fine needle aspiration cytology of lymph nodes in Kathmandu Medical College, Teaching hospital. *Kathmandu Univ Med J* 2009;7(26):139-42.
10. Akeel A. Khdhayer, Mazin Jasim Al-Azawi, Nawal Al-Alash. *Fine Needle Aspiration Cytology In The Diagnosis Of Head And Neck Masses.* *European Scientific Journal* February 2016 edition vol.12, No.9 ISSN: 1857-7881.
11. Jandu M, Webster K. The role of operator experience in fine needle aspiration cytology of head and neck masses. *Int J Oral Maxillofac Surg.* 1999;28(6):441-4.
12. Hag IA, Chiedozi LC, al Reyees FA, Kollur SM. Fine needle aspiration cytology of head and neck masses. Seven years' experience in a secondary care hospital. *Acta Cytol.* 2003;47(3):387-92.
13. J. Akhavan-Moghadam, M. Afaaghi. A. Reza Maleki, A. Saburi. Fine Needle Aspiration: An Atraumatic Method to Diagnose Head and Neck Masses. *Trauma Mon.* 2013 December; 18(3):117-21.
14. Tracy TF Jr, Muratore CS. Management of common head and neck masses. *Semin Pediatr Surg.* 2007;16:3-13.
15. Patra AK, Nanda BK, Panda AK. Diagnosis of Lymphadenopathy by fine needle aspiration cytology. *Indian J Pathol Microbiol* 26:273,1983.
16. Sarda AK. Bal S. Singh MK. Kanpur MM. Fine needle aspiration cytology as preliminary diagnostic procedure for asymptomatic cervical Lymphadenopathy. *J Assocphys Indian* 38(3):203-5,1990.
17. Bandyopadhyay SN, Roy KK, Dash, Anjal, Ghosh RN. Role of FNAC in diagnosis of lymphadenopathies. *Indian J Otolaryngol* 48(4):289-293,1996.
18. Patel MM, Italiya SL, Patel RD, Dudhat RB, Kaptan KR, Baldwa VM. Role of Fine Needle Aspiration Cytology to Analyze Various Causes of Lymphadenopathy. *Natl J Community Med* 2013;4(3):489-492.
19. .R Rani, R Bhargava, N Verma, C Prakash, S Sharma, N Malik. A Study Of Pattern Of Lymphadenopathy On Fine Needle Aspiration Cytology In And Around Meerut, U.P (India). *The Internet Journal of Pathology.* 2014 Volume 16 Number 1.
20. SS Ahmed, S. Akhtar, K. Akhtar, S. Naseem, T. Mansoor, S. Khaleel: Incidence of Tuberculosis from Study of Fine Needle Aspiration Cytology in lymphadenopathy and Acid Fast staining. *IJCM, Vol.30, No.2(2005-04-2005-06).*
21. Ahmad T, Naeem M, Ahmad S, Samad A, Nasir A. Fine needle aspiration cytology (FNAC) and neck swellings in the surgical outpatient. *JAMC.* 2008;20:30-2.
22. Anderson WAD, Damjanov I, Linder J. *Pathology Vol. 1, St. Louis: The CV Mosby Co., 1996.*
23. Reena J, Poonam W, Lokesh T et al: Evaluation of Thyroid Swellings by FNAC in Greater Gwalior Region- A Nine Year Retrospective Study: *JMSCR.* 2015 Oct;3(10):7852-7857,October 2015 201.
24. Setal Chauhan, Dharmendra Rathod, D. S. Joshi. FNAC of swellings of head and neck region. *Indian Journal of Applied and Basic Medical Sciences* 2011;13:16.
25. Pranesh Prasad: Comparative study of FNAC and histopathology in diagnosis of thyroid swellings: *Indian journal of surgery:* 54:287-291,1992.
26. Jain M, Majumdar DD, Agarwal K, Bais AS, Chouhury M. FNAC as a diagnostic tool in pediatric head and neck lesions. *Indian Pediatr* 1999;36:921-23.
27. Gupta N, Rajwanshi A, Srinivasan R, Nijwahan R. Pathology of supraclavicular lymphadenopathy in Chandigarh, north India: An audit of 200 cases diagnosed by fine needle aspiration. *Cytopathology.*2006;17:94-6.
28. Amedee R.G., Dhurandhar NR. Fine needle aspiration biopsy. *The Laryngoscope* 2001;111:1551-57.
29. Ridge JA, Glisson BS, Lango MN, et al. "Head and Neck Tumors" in Pazdur R, Wagman LD, Camphausen KA, Hoskins WJ (Eds) *Cancer Management: A Multidisciplinary Approach.* 11 ed. 2008.
30. Murata M, Takayama K, Choi B, Pak A (1996). "A nested case-control study on alcohol drinking, tobacco smoking, and cancer". *Cancer Detect Prev* 20(6):557-65.
31. Agarwal KN (2008). Iodine deficiency and endemic goiter: a national tragedy. *Indian Pediatr* 45:454-455.
32. International Institute for Population Science (IIPS) and Macro International, 2008. National Family Health Survey (NFHS-3), India, 2005-06: Uttarakhand. Mumbai: IIPS.