

Morphological spectrum of peripheral lymphadenopathy – A hospital based study

Suba G.^{1,*}, Jayaprakash H.T.², Shradha A.³

¹Assistant professor, ²Professor & HOD, ³Post Graduate, Dept. of Pathology, Dr. B. R. Ambedkar Medical College, Bangalore

***Corresponding Author:**

Email: suba_t@rediffmail.com, drsubag@gmail.com

Abstract

Background: Lymphnode is one of the commonest site for neoplastic and non-neoplastic diseases. This study was undertaken to analyse the patterns of lesions seen in peripheral lymphadenopathy cases.

Materials and Method: This retrospective study of 103 cases of lymphnode biopsies was carried out in the department of pathology for a period of 3 years. Relevant patient data were retrieved from the file. Slides were reviewed thoroughly and special stains were applied wherever necessary.

Results: Out of 103 cases, 88 (85.4%) were non-neoplastic lesions and 15 (14.6%) were neoplastic lesions. The most commonly biopsied group was cervical nodes. Tuberculosis was the most common condition 44 cases (42.7%) followed by reactive hyperplasia 41 cases (39.8%). Of the 15 cases (14.6%) of malignancy, 10 (9.7%) were metastatic deposits and 5 (4.9%) were lymphomas.

Conclusion: Tuberculosis is the leading cause of lymphadenopathy and young females are commonly affected. Histopathology is the gold standard in confirming the diagnosis of lymphnode lesions.

Keywords: Lymphnode, Lymphoma, Neoplastic, Tuberculosis.

Introduction

Lymphoid tissue is a vital part of our immune system, which consists of lymphnodes, spleen, tonsils, adenoid and thymus. Lymphnodes are bean shaped structures, distributed along the lymphatic pathway and play a major role in body's defence mechanism. There are approximately 600 lymphnodes spread throughout the human body and concentrated mainly in the neck, axilla, groin, mediastinum and mesenteries. Lymphadenopathy is defined as enlargement of lymphnodes (1cm or more) or alteration in their consistency / number. There are a list of conditions lead to lymphadenopathy, ranging from infections, autoimmune diseases, malignancies and various miscellaneous conditions. Though clinical examination, laboratory tests and imaging modalities help in the diagnostic workup, the definitive diagnosis would be arrived only with tissue biopsy which is a gold standard method. The aim of this study is to evaluate the pathological spectrum of various non-neoplastic and neoplastic lesions of lymphnodes.

Materials and Method

This retrospective study was conducted in the department of pathology over a period of 3 years from Mar 2012 to Apr 2015. There were 103 cases of peripheral lymphnode biopsies included in this study. Lymphnodes of known primary, which are part of a radical specimen, inadequate samples and deep seated nodes were excluded from the study. The specimens were grossly examined for size, appearance, matting, consistency, details of cut section and then fixed in 10% formalin for 24 hrs. The tissues were processed in routine paraffin technique and then stained with hematoxylin

and eosin. Special stains e.g. AFB, PAS etc. were used wherever necessary. Relevant patient data regarding age, sex, clinical details, results of imaging studies and provisional diagnosis were retrieved from the patient request forms and records. All the histopathological slides were reviewed in detail and classified into non-neoplastic and neoplastic category. Appropriate statistical tools were used to analyse the results.

Results

A total of 103 cases of superficial lymphnode biopsies were included in this study with the age range of 8yrs to 76 yrs. Female patients 56 cases (54.4%) slightly outnumbered the male patients 47 cases (45.6%). The male to female ratio is 1:1.2. Majority of the patients 45 (43.7%) are young adults between 10 – 30 yrs. Age wise distribution is given in Table 1.

Table 1: Age wise distribution of cases

Age (years)	No of cases (n=103)	Percentage (%)
0 -10	6	5.8
11-20	22	21.4
21-30	23	22.3
31-40	19	18.4
41-50	10	9.7
51-60	16	15.5
61-70	4	3.9
71-80	3	2.9

Maximum number of biopsies were from cervical region 93 (90.3%), followed by inguinal 6 (5.8%) and axillary the least, 4 cases (3.9%). Age wise distribution of lesions is given in Table 2.

Table 2: Distribution of various lesions in different age groups

Age	Type of lesion					
	TB	Reactive	Cat scratch disease	Acute non-specific lymphadenitis	Metastasis	Lymphoma
0-10	1	4	-	-	-	1
11-20	14	10	-	-	-	-
21-30	12	8	1	1	2	-
31-40	10	6	-	-	2	-
41-50	2	4	-	-	3	1
51-60	4	7	-	-	3	-
61-70	1	1	-	-	-	2
71-80	-	1	1	-	-	1
Total	44	41	2	1	10	5
Percentage	42.7%	39.8%	1.9%	0.9%	9.7%	4.9%

Out of 103 cases, non-neoplastic category constituted 88 (85.4%) and neoplastic lesions 15 (14.6%). Tuberculosis was the most common entity 44 cases (42.7%) diagnosed under non neoplastic category. Majority of the tuberculous patients were in the age range of 11-30 yrs. with the female preponderance of 25 cases (56.8%). Among 44 cases of tuberculosis, 42 showed typical caseating epithelioid granulomas. Ziehl Neelsen stain was positive in 7 cases.

The second most common category was reactive lymphadenitis which accounted for 41 cases (39.8%) and seen predominantly in males, 23 cases (56%). Microscopy revealed one of the following picture: follicular hyperplasia/ paracortical hyperplasia/ sinus expansion with histiocytosis or a mixed pattern of the above features. There were 2 cases of cat scratch disease and both were female patients. Microscopy showed granulomas with central satellite necrosis with neutrophils surrounded by palisading histiocytes.

Out of 15 cases (14.6) of malignancy, 10 (66.7%) showed metastatic deposit and 5 were (33.3%) lymphomas. Among the metastatic deposits, adenocarcinoma was found in 4 cases followed by squamous cell carcinoma and poorly differentiated carcinoma in 3 cases each. Metastatic deposit was commonly observed in patients above 40 years of age with female predominance of 8 cases (80%). PAS stain was positive in a case of metastatic signet ring cell adenocarcinoma.

Of the 5 cases of lymphomas (33.3%), Non Hodgkin lymphoma accounted for 4 cases (80% of all lymphomas) and 1 case (20%) of mixed cellularity type of Hodgkin lymphoma. All the NHL cases were seen between 60-80 years. Out of 4 cases of NHL 1 was follicular lymphoma (25%), 2 were CLL/SLL (50%), and 1 case of DLBCL (25%).

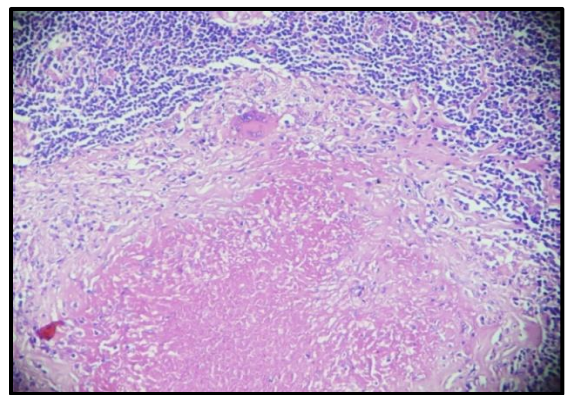


Fig. 1: Caseating epithelioid granuloma in a case of tuberculous Lymphadenopathy

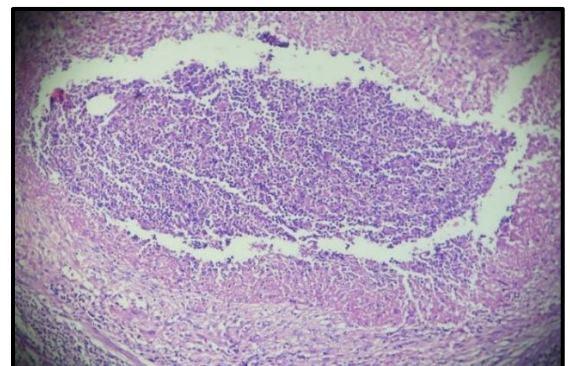


Fig. 2: Catscratch disease with necrotizing granuloma surrounded by palisading histiocytes

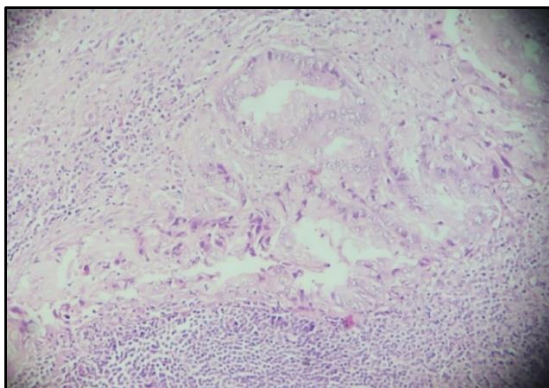


Fig 3: Metastatic adenocarcinoma in lymphnode

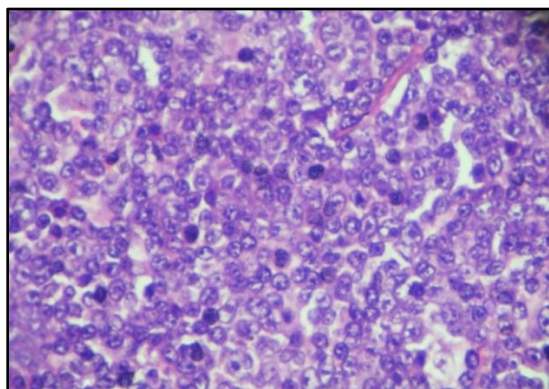


Fig 4: Non hodgkin lymphoma – SLL/CLL

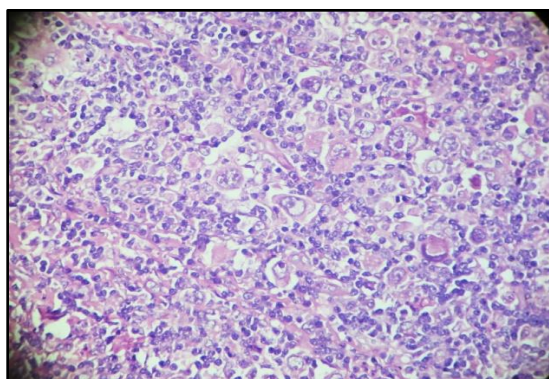


Fig 5: Classical Hodgkin lymphoma- Mixed cellularity subtype with RS cell and Hodgkin cells in a mixed cellular background

Discussion

In the present study, the most common diagnosis being non neoplastic lesions. Similar finding was observed in various other studies done within and outside India.^(1,2,3) In contrast the neoplastic lesions were found to be common in the studies done by Roy et al⁽⁴⁾ and Albarisi et al.⁽⁵⁾ This difference could probably be explained by the large volume of cases and tertiary setup where the study material had been taken from.

The most commonly biopsied group of lymph nodes in our study was cervical group (90.3%). It is consistent with many recent studies in literature.^(5,6,7,8) In our study

majority of the patients were in between 11-30 years, which is similar to both Roy et al⁴ and Albarisi AM⁽⁵⁾ et al.

In developing countries like India, tuberculosis is the most common cause for superficial lymphadenopathy.⁽⁹⁾ The most common form of extrapulmonary tuberculosis is lymphnode enlargement and mainly young people are affected in countries with high prevalence of tuberculosis.⁽¹⁰⁾ Tuberculosis was the most frequent of all lesions found in our study (42.7%). This is in accordance with various other studies.^(1,3,7,8) The high incidence could be due to low socioeconomic status and poor standard of living. The patients were predominantly females in the age group of 11-30yrs, which is consistent with other authors.^(1,2,6,8)

In contrast male predominance is reported in a study done by Ismail M et al⁽¹¹⁾ in Pakistan, which could probably be explained by social and cultural background of patients. TB is rare in western countries and malignancies like lymphomas are the major cause of lymphadenopathy.⁽¹²⁾ Many studies have documented the association between tuberculosis and HIV infection.^(13,14) But unfortunately we could not interpret the association because the HIV test was not done in our patients.

In our study 7 /44 cases (16%) of tuberculous lymphadenitis were showing positivity for ziehl neelsen stain. The frequency of AFB positivity in lymphnode biopsies varies from 2.1% - 61.7% as demonstrated by different authors.^(10,15-17) Formalin/ xylene would alter the cell wall property of mycobacteria which leads to low AFB positivity in formalin fixed sections. Fukunaga et al⁽¹⁷⁾ demonstrated that sensitivity of AFB stain significantly decreases with formalin/xylene treatment.

The second most common category in the present study was found to be reactive hyperplasia of lymphnodes (39.8%). Rahman A et al⁽¹⁾ and Panchal J et al⁷ found TB as the most common lesion followed by reactive lymphadenopathy, which is consistent with the present study. While Vachhani AB et al⁽²⁾ found reactive lymphadenopathy to be the most common lesion followed by TB. Malignant lesions comprised third most common cause of lymphnode enlargement in our study. Out of all the malignant lesions metastatic deposit accounting for 66.7% (9.7% of all lymph node lesions), whereas lymphomas 33.3% (4.8% of all lymph node lesions). This data is comparable with various studies.^(2,3,18) Whereas some studies reported lymphomas to be the commonest of all malignant lesions.^(1,4,5,7) Metastatic deposit was commonly observed in patients above 40 years of age in our study which is similar to Shreshta AK et al⁽¹⁹⁾ and Darnal HK et al.⁽²⁰⁾

Among the lymphomas, NHL was more common than HL comprising 3.9% of all lymphnode lesions. NHL has been reported by several other authors as the commonest type of lymphomas.^(1,3,4,8)

Conclusion

Peripheral lymphadenopathy is seen in wide range of age group and in both sexes. Tuberculosis is the leading cause of lymphnode enlargement and affects predominantly young females. Though we have many different tools to investigate lymphadenopathy, histopathology remains the gold standard for diagnosis.

References

- Rahman MA, Biswas MM, Siddika ST, Sikder AM. Histopathological evaluation of lymph node biopsies: A Hospital Based Study. *Journal of Enam Medical College*. 2012 Sep 24;2(1):8-14.
- Vachhani AB, Jasani JH, Tandon RK. Histopathological study of lymph node biopsy. *International Journal of Biomedical and Advance Research*. 2013 Nov 30;4(11):790-5.
- Kamat GC. A ten-year histopathological study of generalised lymphadenopathy in India. *South African Family Practice*. 2011 May 1;53(3):267-70.
- Roy A, Kar R, Basu D, Badhe BA. Spectrum of histopathologic diagnosis of lymph node biopsies: A descriptive study from a tertiary care center in South India over 5½ years. *Indian J Pathol Microbiol*. 2013;56:103–8.
- Albasri AM, El-Siddig AA, Hussainy AS, Alhujaily AS. Pattern of lymph node pathology in western Saudi Arabia. *Asian Pacific journal of cancer prevention: APJCP*. 2013 Dec; 15(11):4677-81.
- Khan MA, Shah W, Pervez SN et al. Cytomorphological pattern of superficial lymphadenopathy. *Gomal Journal of Medical Sciences*. 2015 Jan 21;12(4).
- Panchal J, Pai P. Spectrum of pathologic lesions in superficial lymph node biopsies—a one and half year study. *International Journal of Biomedical and Advance Research*. 2014 Sep 30;5(9):435-8.
- Ageep AK et al. Assessment of Adult peripheral lymphadenopathy in Red Sea state, Sudan. *Int J Trop Dis Health*. 2012;2:24-32.
- Nidhi P, Sapna T, Shalini M, Kumud G. FNAC in tuberculous lymphadenitis: experience from a tertiary level referral center. *Indian J Tuberc* 2011;58:102–107.
- Eshete A, Zeyinudin A, Ali S et al. M. tuberculosis in Lymph node biopsy paraffin embedded sections. *Tuberc. Res. Treat*. 2011:127817.
- Ismail M, Muhammad M. Frequency of tuberculosis in cervical lymphadenopathy. *J Postgrad Med Inst* 2013;27(3):342-6.
- Olu-Eddo AN, Ohanaka CE. Peripheral lymphadenopathy in Nigerian adults. *J Pak Med Assoc* 2006;56:405-8.
- Markowitz N, Hansen NI, Hopewell PC et al. Incidence of tuberculosis in the United States among HIV infected persons. *Ann Intern Med* 1997;126:123-32.8.
- Bem C, Patil PS, Bharucha H et al. Importance of human immunodeficiency virus-associated lymphadenopathy and tuberculous lymphadenitis in patients undergoing lymph node biopsy in Zambia. *Br J Surg* 1996;83:75-8.
- Mbata GC, Nweke IG, Egejuru RO, Omejua EG, Nwako OF, et al. (2015) South Eastern Histologic Pattern of Lymph Node Biopsies in a Tertiary Hospital in Nigeria. *J AIDS Clin Res* 6:475.
- Goel MM, Budhwar P (2007) Immunohistochemical localization of Mycobacterium tuberculosis complex antigen with antibody to 38 kDa antigen versus Ziehl Neelsen staining in tissue granulomas of extrapulmonary tuberculosis. *Indian J Tuberc* 54:24–29.
- H. Fukunaga, T. Murakami, T. Gondo, K. Sugi, and T. Ishihara, “Sensitivity of acid-fast staining for Mycobacterium tuberculosis in formalin-fixed tissue,” *American Journal of Respiratory and Critical Care Medicine*, vol. 166, no. 7, pp. 994–997, 2002.
- Shakya G, Malla S, Shakya KN, Shrestha R: A Study of FNAC of Cervical lymph nodes. *J Nepal Health Research Council* 2009;7:1–5.
- Shrestha AK, Chalise PR, Shrestha ML. Lymph node biopsies: a hospital based retrospective study. *JNMA J Nepal Med Assoc*. 2009;48:306–9.
- Darnal HK, Karim N, Kamini K, Angela K. The profile of lymphadenopathy in adults and children. *Med J Malaysia*. 2005;60:590–8.