

Primary Angiosarcoma of spleen –A rare case report from rural hospital

Varsha Pandey^{1,*}, V. Sudarshan², Shiv Chandraker³, K. S. Chandraker⁴

^{1,4}Assistant Professor, ²Professor & HOD, ³Professor, Dept. of Pathology, C.C.M. Medical College, Durg

***Corresponding Author:**

Email: varshanema@live.com

Abstract

Primary angiosarcoma of the spleen is a very rare malignant neoplasm. It comprises less than 1% of all splenic sarcomas. It may present with non-traumatic spontaneous rupture of the spleen and lethal hemorrhage. It is difficult to diagnose clinically and has a variable morphological spectrum. It is a highly aggressive malignant tumor having poor prognosis. It is usually found in adults above 40 years of age. A 22 year old female presented with abdominal pain and mass of four month duration. Physical examination revealed splenomegaly and diffuse tenderness all over the abdomen. Following computed tomography scan a possible clinical diagnosis of giant cavernous hamangioma of the spleen was made. Histopathology following splenectomy revealed angiosarcoma. We report this rare case along with review of literature.

Keywords: Angiosarcoma, Malignant, Primary Tumor, Spleen, Rare.

Introduction

Primary splenic angiosarcoma is highly aggressive, extremely rare, malignant neoplasm. It arises from endothelial cells lining splenic sinusoids. Approximately 200 cases have been reported in the literature.⁽¹⁾ The morphological spectrum of angiosarcoma is highly variable causing diagnostic difficulty.^(2,3) It shows frequent metastasis and has very poor prognosis. Majority of the cases are seen in adults above 40 years of age. Here we report a rare case of this clinical entity in a 22 year old female, along with a complete review of the current literature.

Case Report

A 22 year old female presented with abdominal pain and mass of four month duration. She also gave history of fatigue and low grade fever. Physical examination revealed splenomegaly and diffuse tenderness all over the abdomen. Laboratory findings showed anemia (Hb-6.9gm/dl) with a total leucocyte count of $10.6 \times 10^3/\text{mm}^3$ and platelet count of $350 \times 10^3/\text{mm}^3$. A computed tomography scan of the abdomen with contrast (CECT) revealed a huge superomedially exophytic splenic mass which showed heterogeneous enhancement on immediate CECT and peripheral fill up on delayed CECT. Two medium sized and a small hepatic parenchymal lesions were noted which were mixed iso and hypodense. Based on these findings a possible clinical diagnosis of giant cavernous hemangioma of the spleen, along with hepatic hemangiomas was made. Exploratory laparotomy was performed and splenectomy was done. Metastatic foci were also observed in the liver during this procedure. The splenectomy specimen weighed 980 grams, measuring 15cmx11cmx8.5cm in size. External surface was nodular with a large nodular area measuring 11cmx5cm. The cut surface showed grey brown friable growth with areas of necrosis, hemorrhage and cystic spaces, involving the whole of the spleen (Fig.

1). On microscopic examination most of the splenic parenchyma was found to be replaced by the neoplasm which consisted of dilated vascular channels lined by highly anaplastic malignant tumor cells with marked pleomorphic nuclei and high mitotic activity (Fig. 2). Few large multinucleated cells and intracytoplasmic hyaline globules were also seen. There were extensive areas of necrosis and hemorrhage (Fig. 3). Immunohistochemistry revealed strong positivity for CD31 (Fig. 4) and CD34 (Fig. 5) in the neoplastic cells and were non-reactive for smooth muscle antigen (SMA). Based on these findings a diagnosis of primary angiosarcoma of the spleen was made. The patient succumbed to the disease within one month of surgery before chemotherapy could be started.

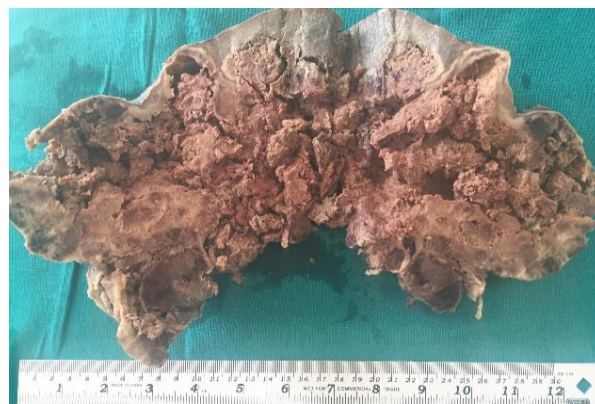

Fig. 1: Gross appearance – Cut surface of enlarged spleen showing grey brown friable growth with cystic spaces and areas of necrosis involving the whole spleen

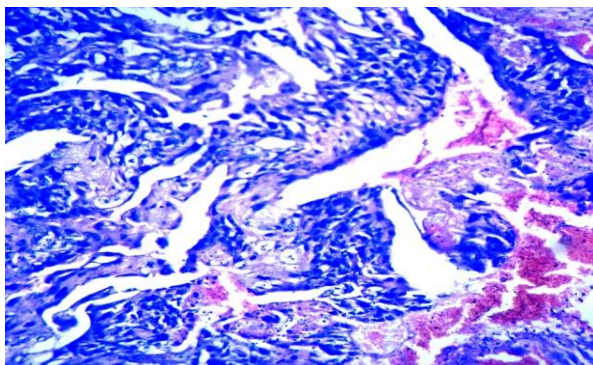


Fig. 2: Photomicrograph showing highly anaplastic malignant tumor cells, x400 H&E

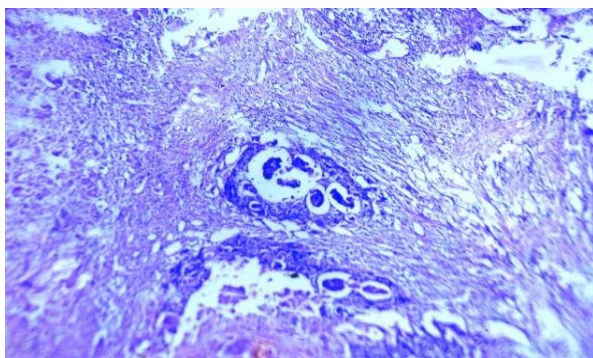


Fig. 3: Photomicrograph showing highly anaplastic malignant tumor cells with extensive areas of necrosis and hemorrhage, x100 H & E

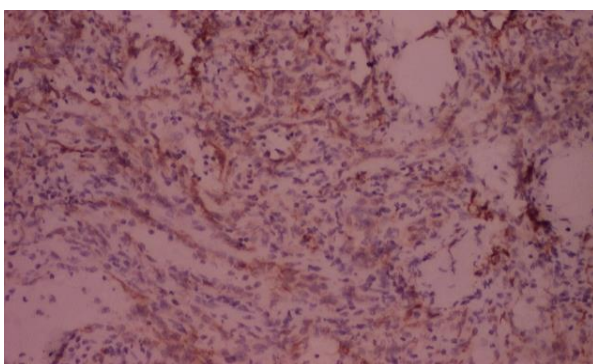


Fig. 4: Photomicrograph showing immunoreactivity for CD 31

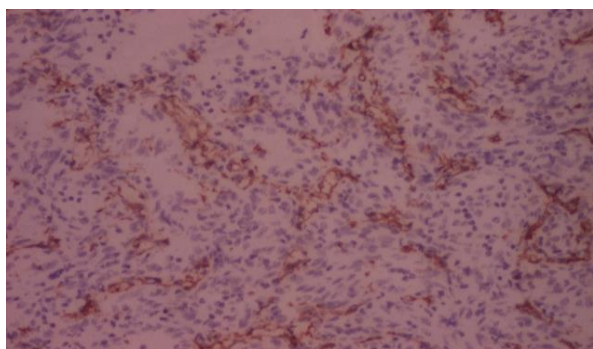


Fig. 5: Photomicrograph showing immunoreactivity for CD 34

Discussion

Primary angiosarcoma of the spleen is a rare and aggressive malignant neoplasm, with an incidence of 0.14-0.25 cases per million persons, first described by Theodor Langhans in 1879.^(1,2) It may be seen in any age group, from 14 months to 89 years of age but most of the cases are seen in adults above 40 years. It is slightly more common in males.^(2,3) Only 9 cases have been reported in the pediatric population.⁽⁴⁾ Our patient was a young 22 year old female. Unlike primary hepatic angiosarcoma, there is no known association between splenic angiosarcoma and occupational exposure to chemicals such as vinyl chloride or arsenic or prior injection with the contrast agent thorium oxide.^(2,3,5) There is some suggestion that primary splenic angiosarcoma may result from malignant transformation or persistence of benign splenic tumors like haemangioma, lymphangioma or haemangioendothelioma.⁽⁶⁾ There was no evidence of any of these factors involved in our case. Clinical presentation include non-specific symptoms like fatigue, abdominal pain, heaviness to features of hypovolemic shock post splenic rupture.⁽⁷⁾ Splenic rupture rates have been reported in 13-32% cases.^(1,5,8) Splenomegaly is the most common finding on physical examination.⁽³⁾ Hepatomegaly may also be present. Anemia is the most common hematological abnormality found in 75% to 81% of cases. Cytopenia is a common finding. Leucocytosis, thrombocytosis and elevated Erythrocyte sedimentation rates may also be seen.⁽²⁾ Peripheral blood picture may suggest hemolytic anemia.^(6,8) Imaging studies are also helpful for the diagnosis but lacking accuracy. CT scan may reveal an enlarged spleen with hypoattenuating or hyperattenuating areas with punctuate or massive calcification. On CECT, the tumors may exhibit peripheral or heterogeneous enhancement similar to that of hepatic cavernous hemangiomas as seen in our case which lead to the preoperative diagnosis of cavernous hemangioma. Biopsy is contraindicated in these cases, histological studies and final diagnosis can only be made after splenectomy. Grossly spleen usually weigh >1000g.^(2,5) Macroscopically, there may be diffuse involvement of the spleen. The entire splenic parenchyma may be replaced by the tumor with extensive areas of hemorrhage and necrosis.⁽⁵⁾ The microscopic appearance varied greatly. The tumor consists of disorganized anastomosing vascular channels and these are lined by large, atypical endothelial cells having with irregular, hyperchromatic nuclei.⁽⁵⁾ There may be sarcomatous, papillary and epithelioid growth patterns. Additional features may include foci of necrosis and hemorrhage, hemosiderin, extramedullary hemopoiesis, intracytoplasmic hyaline globules, calcification and thrombosis.^(2,3) Pathologically tumor size and mitotic counts are important prognostic factors, while histological appearance or grade of the disease has no prognostic value.^(9,10) Spontaneous or traumatic rupture of spleen is associated with the worse prognosis.

The only management is splenectomy which may result in long term disease free survival especially when performed prior to rupture.⁽²⁾ and these are highly refractory to adjuvant treatment with radiation and chemotherapy.^(1,3,5,6) Metastases may occur in 69% to 100% of cases of splenic angiosarcoma and are present at the time of diagnosis in the majority of cases. Metastases may be seen in the liver, lungs, lymph nodes and bone.⁽³⁾ Our patient had metastasis in the liver. Median survival is five months irrespective of treatment approach.⁽¹⁾ The longest survival reported is 16 years in a pediatric patient.⁽⁴⁾

Conclusion

Primary splenic angiosarcoma is a rare and aggressive malignant tumor which can be found in any age group although most of the cases occurs in adults over 40 years of age. The clinical and radiologic diagnoses are challenging. CT scans can mimic benign conditions like haemangiomas. In most cases the tumor has already metastasized at the time of diagnosis and is universally fatal despite treatment. Nevertheless, Splenectomy after early diagnosis and in the absence of metastatic disease, especially when performed prior to rupture may have a better prognosis. In spite being rare entity, the diagnosis should be kept in mind in any patient with splenomegaly and unexplained anemia, especially when a distinctive tumor of the spleen is revealed on imaging.

References

1. Badani R, Schaller G, Janik, Swamy R, Gupta S. Angiosarcoma of the spleen presenting as spontaneous splenic rupture: A rare case report and review of the literature. *Int J Surg Case Rep.* 2013;4(9)765-767.
2. Falk S, Krishnan J, Meis JM. Primary angiosarcoma of the spleen. A clinicopathologic study of 40 cases. *Am J Surg Pathol.* 1993;17:959-970.
3. Neuhauser TS, Derringer GA, Thompson LD, et al. Splenic angiosarcoma: a clinicopathologic and immunophenotypic study of 28 cases. *Mod Pathol.* 2000;13(9):978-987.
4. Hsu JT, Ueng SH, Hwang TL, Chen HM, Jan YY, Chen MF. Primary angiosarcoma of the spleen in a child with long-term survival. *Pediatr Surg Int.* 2007;23:807-810.
5. Kamran S, Hamid, Joaquin A, Rodriguez and Terry C. Laimare. Primary splenic Angiosarcoma. *JSL* 2010;14(3):431-435.
6. Sordillo EM, Sordillo PP, Hajdu SI. Primary hemangiosarcoma of the spleen: report of four cases. *Med Pediatr Oncol.* 1981;9:319-324 .
7. Jaya Kumar KL, Kuriakose VG, Somasekharannair DV, Govindan K, Varghese A. Primarynon metastatic angiosarcoma of the spleen. *Transl Gastrointest Cancer* 2015;4(4)316-319.
8. Mridula Shukla, Somprakash Basu, Vijay k Shukla, Mohan kumar. Fever, anemia and splenomegaly: A rare presentation of splenic angiosarcoma. *Indian Journal of Medical and Pediatric oncology* 2011;32(4)230-232.
9. Mark RJ, Poen J C, Tran LM, Fu YS, Juillard GF. Angiosarcoma. A report of 67 patients and a review of the literature. *Cancer.* 1996;43:702-708.

10. Naka N, Ohsawa M, Tomita Y, et al. Prognostic factors in angiosarcoma: A multivariate analysis of 55 cases. *J Surg Oncol.* 1996;61:170-176.