

## Von Willebrand disease - broadening our vision: a pediatric case report with dental considerations

Mridula Goswami<sup>1</sup>, Deepti Thakkar<sup>2,\*</sup>

<sup>1</sup>Professor & Head, <sup>2</sup>Senior Resident, Dept. of Pedodontics, Maulana Azad Institute of Dental Sciences, New Delhi, India.

**\*Corresponding Author:**

Email: dr.deeptithakkar@gmail.com

### Abstract

Von Willebrand disease is an autosomal inherited bleeding disorder caused due to the quantitative or qualitative defects of a multimeric glycoprotein, the Von Willebrand factor (VWF). VWF is a multi-adhesive protein that carries factor VIII in circulation and initiates aggregation of platelets to exposed sub endothelial collagen fibers. The deficiency or abnormality of VWF causes reduction in the levels of factor VIII, as seen in Hemophilia A patients. The common clinical manifestations of Von Willebrand disease include soft tissue and mucosal bleeding. The severity of the disease is determined by the extent of von Willebrand factor and factor VIII reduction in the circulation. Since symptoms are often mild, a significant majority of patients remain undiagnosed. This article presents the ongoing dental management of a seven-year old female diagnosed with Von Willebrand disease. The primary aim of the article is to focus on the diagnosis, management and dental considerations of this common yet overlooked disorder and distinguish it from Hemophilia.

**Keywords:** Von Willebrand disease, Von Willebrand factor, Bleeding disorders, Hemophilia A

### Introduction

Haemostasis plays a pivotal role in maintaining the integrity of blood circulation.<sup>(1)</sup> Normally, haemostasis occurs through two independent and related processes—the coagulation cascade and the platelet activation process.<sup>(2)</sup> The combined interaction of the endothelial cells, platelets and several coagulation factors results in haemostasis. A multimeric glycoprotein, Von Willebrand factor (VWF) produced by the endothelial cells and megakaryocytes circulates in a non-covalent complex along with factor VIII (FVIII), thereby protecting it from early proteolytic degradation. The high shear stress condition in the microvasculature propagates the binding of the sub-endothelial VWF to platelets. This causes the stimulation of platelets via the glycoprotein Ib–V–IX complex thereby, mediating platelet aggregation which results in consolidation of platelets with fibrin and formation of clot at the site of injury.<sup>(3,4,5)</sup>

Von Willebrand disease (VWD) is a family of inherited bleeding disorders arising from quantitative or qualitative defects in Von Willebrand factor (VWF), which plays a crucial role in the adhesion of platelets to the sub-endothelium during vascular injury and is essential for normal primary haemostasis to occur.<sup>(6)</sup> First described by Erik Adolf Von Willebrand in 1926 as 'pseudohaemophilia'. Von Willebrand disease is a congenital bleeding disorder characterized by a life-long tendency toward easy bruising, frequent epistaxis, haematomas, menorrhagia and heavy and delayed bleeding after oropharyngeal surgery.<sup>(7)</sup> The prevalence of VWD was assessed to be 0.6–1.3% in population based studies as compared to 0.005–0.01% in special centers where symptomatic patients with VWD are often referred.<sup>(8,9)</sup>

In the present report, we describe the ongoing dental management of a seven-year old female with Type 2N Von Willebrand disease focusing on the diagnosis, haematologic conditioning and dental considerations of the same. The aim of the review is to bring to the forefront the dental management of one of the most common yet overlooked bleeding disorder—Von Willebrand disease.

### Case Report

A seven-year old female reported to the Department of Pedodontics with the complaint of recurrent bleeding from upper right front tooth region. Her medical history revealed that she was a diagnosed case of Von-Willebrand disease. There was history of easy bruisability, epistaxis, gum bleeding in the past which used to stop after factor infusion under medical supervision. There was no history of consanguineous marriage of parents. The pedigree analysis of the family was done and none of the members of the family were affected suggesting either an autosomal recessive pattern of inheritance or de novo mutation. The patient had overall normal physical and mental development. Extra-oral examination revealed the absence of pallor, icterus, cyanosis, clubbing and lymphadenopathy. Intraoral examination revealed a root stump in relation to 52, the offending tooth from where recurrent bleeding occurred. There were multiple carious lesions in primary and permanent teeth (Fig. 1). An informed consent was taken from the haematologist prior to the extraction procedure. The patient's consent was taken and haematological investigations were carried out (Table 1). The treatment plan aimed at infusion of the VWF/ FVIII concentrate since VWF is the carrier protein for Factor VIII, establishment of haematologic

equilibrium followed by extraction of 52. The extraction was done 60 minutes after the infusion of Anti-haemophilic Factor (Inj. Immunate, 250 IU). The local haemostatis was achieved using Tranexamic Acid (TexidInj, 500 mg/5ml). Post extraction instructions were imparted and Acetaminophen 125 mg (15mg/kg/dose) analgesic was prescribed. The routine follow up of the child was done after 24 hours to check for post-operative bleeding. The child is presently undergoing conservative dental treatment involving restorations of the several carious primary and permanent teeth (Fig. 2). The complete treatment of the patient is a teamwork being done in close collaboration with the Haematologist.

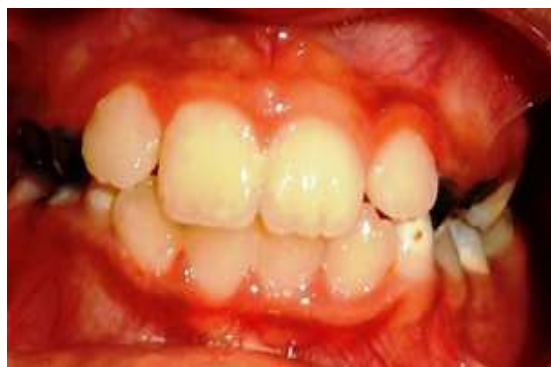

Fig. 2: Follow up post-operative picture

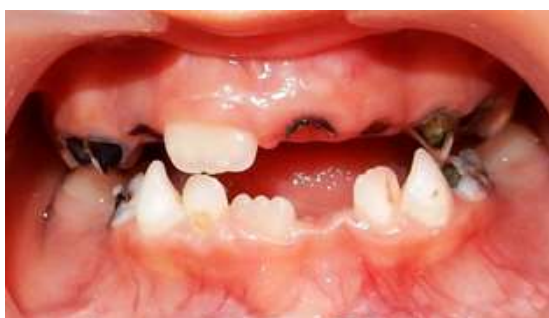

Fig. 1: Pre-operative picture

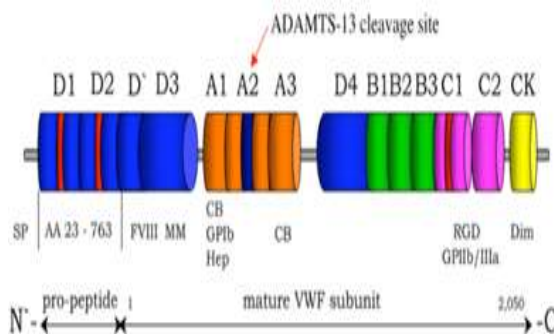


Fig. 3: Subunit structure of VWF

Table 1: Result of the pre-operative haematologic investigations

Investigation	Result	Normal Range
Hemoglobin Concentration (g/dL)	8.7	10.9-14.9
Platelet count (mm <sup>3</sup> )	4,80,000	150,000-500,000
Erythrocyte count (x 10 <sup>6</sup> /μL)	4.5	3.80-5.20
White cell count (x 10 <sup>3</sup> /μL)	9.5	4.5-11.5
Bleeding time (min)	2	1-4
aPTT (s)	34.59	25-35
Prothrombin time (s)	11.4	11-14
INR	1.85	0.8-1.2
Factor VIII (%)	29.05	50-100
Factor IX (%)	94.3	50-100

aPTT- activated partial thrombolastin time, INR- Internantional Normalized Ratio

Table 2: Classification and characterization of von Willebrand disease (VWD) types

Type	Pathogenetic mechanisms	Inheritance	Most frequent VWF gene defects
VWD1	Partial quantitative deficiency of VWF	Autosomal dominant	Missense mutations (85%), null alleles (15%), variable penetrance
VWD2A	Decreased VWF-dependent platelet adhesion due to a loss of High Molecular Weight	Autosomal dominant	Missense mutations, mainly in D3, A2, and CK domains
	VWF multimers	Autosomal	Missense mutations

		recessive	in propeptide
VWD2B	Increased affinity of VWF for platelet GPIIb/IIIa	Autosomal dominant	Missense mutations in A1 domain
VWD2M	Decreased VWF-dependent platelet adhesion without a loss of High Molecular Weight VWF multimers	Autosomal dominant	Missense mutations in A1 domain
VWD2N	Decreased binding affinity of VWF for factor VIII	Autosomal recessive	Missense mutations in D' and D3 Domains
VWD 3	Virtually complete deficiency of VWF	Autosomal recessive	Mainly null alleles, Large-small deletions

**Table 3: Laboratory assays for VWF activities**

Test	Pathophysiological Significance
Antigen VWF (VWF:Ag)	Antigen concentration
Ristocetin cofactor activity VWF (VWF:RCO)	VWF-GPIIb interaction as mediated by ristocetin in vitro
Factor VIII procoagulant activity (FVIII:C)	FVIII-VWF interaction
Binding of VWF to collagen (VWF:CB)	VWF-collagen interaction
Binding of FVIII to VWF (VWF:FVIII:B)	FVIII-vWF interaction
RIPA	Threshold ristocetin concentration inducing patient's platelet-rich plasma aggregation
Multimer analysis	Multimer composition of VWF
Closure time PFA-100	Simulates primary hemostasis after injury to a small vessel
Propeptide assay (VWFpp)	Measures the amount of VWF-pp released in plasma

## Discussion

VWF is a large multimeric adhesive plasma glycoprotein, composed of a series of dimers of mature subunits that has an essential role in both primary and secondary hemostasis.<sup>(10)</sup> The scheme of Von Willebrand factor monomer molecule along with its functional domains is shown in (Fig. 3). The pro-VWF polypeptide is indicated with amino acids numbered from the amino-(aa23) to carboxy-terminal portions (aa763). Binding sites are indicated for factor VIII (D' and D3 domains), platelet glycoprotein IIb/IIIa (GPIIb/IIIa) (A1 domain), collagen (A1 and A3 domains) and integrin  $\alpha$ IIb $\beta$ 3 (RGDS sequence within the C1 domain). The cleavage site (Tyr1605-Met1606) for ADAMTS13 is located at the central A2 domain of Von Willebrand factor.

Von Willebrand disease is one of the most common inherited coagulation disorder caused due to deficiency and abnormality of Von Willebrand factor. Its prevalence is nearly 0.6-1.3% as per the population based studies, however, clinically relevant cases have 10-fold lower prevalence.<sup>(4)</sup> The current classification proposes six different types of VWD based on the

pathogenic mechanisms, mode of inheritance and gene defects as summarized in (Table 2).

In VWD, bleeding episodes occur by two pathogenic mechanisms- (1) Impairment of platelet-VWF interactions. This is usually assessed in plasma by platelet-dependent VWF activity (PD-VWFact) in the presence or absence of ristocetin and by decreased VWF collagen binding activity (VWF:CB). (2) The reduction in FVIII levels that often accompany the VWF defect.<sup>(11)</sup>

The most common presenting symptoms in persons subsequently diagnosed with VWD are epistaxis, menorrhagia, bleeding after dental extraction, ecchymoses, bleeding from minor cuts or abrasions, gingival bleeding, postoperative bleeding, hemarthrosis, gastrointestinal bleeding.<sup>(12)</sup>

The three main criteria essential for correct diagnosis are: (i) Presence of positive bleeding history since childhood; (ii) Reduction in VWF activity in plasma; and (iii) History of bleeding in the family with autosomal dominant or recessive pattern of inheritance. Several clinical, laboratory and molecular parameters are useful for diagnosing the variant of VWD.<sup>(11)</sup>

The clinical factors include both personal and family history of muco-cutaneous and post-operative bleeding. The presence of other affected members within the family is important to determine the type of inheritance trait. Quantitation of mucocutaneous bleeding symptoms in children with VWD is done using the Pediatric Bleeding Questionnaire. The bleeding score 2 or more in children is a cut off to identify those with a bleeding diathesis requiring measurement of VWF related activities.<sup>(13)</sup> Several laboratory assays covering the entire spectrum of VWF activities essential in diagnosing VWD have been enumerated in (Table 3).<sup>(4)</sup>

In the present case, none of the family members were affected suggesting a recessive pattern of inheritance or de novo mutation. There was a deficiency in the binding of FVIII to VWF suggesting defect in the N-terminal region of VWF where the binding domain (D' and D3) for FVIII is located.

The molecular diagnosis is useful to verify and confirm the specific VWF defect in VWD families especially Type 2 VWD since mutations are clustered in specific exons of VWF gene. However, in Type 3 and Type 1 VWD gene defects are spread through the entire VWF gene.<sup>(14)</sup>

VWD3 is always classified as severe by definition since the VWF levels are undetectable in both plasma and platelets with relatively low amounts of FVIII:C (<20U/dL) in plasma. Conversely; VWD1, VWD2A, VWD2B, VWD2M, and VWD2N show a varied clinical presentation with the severity strictly correlating with the circulating levels of functional VWF activity. The severity of the bleeding tendency is comparative to the degree of the primary deficiency of VWF and to that of the secondary deficiency of FVIII, since VWF is the carrier of FVIII in circulating plasma.<sup>(15)</sup> Thus, in VWD the aim of therapy is to correct the abnormal platelet adhesion-aggregation defect of hemostasis and the abnormal intrinsic coagulation resulting from low levels of FVIII.<sup>(4)</sup> Desmopressin (DDAVP) which releases endogenous VWF from endothelial cells and replacement therapy with exogenous VWF/FVIII concentrate or VWF concentrates devoid of FVIII form the basis of treatment. VWF/FVIII concentrates are indicated for patients with Type 3 VWD, for patients with Type 2B (since DDAVP can induce transient thrombocytopenia) and, for all those patients with types 1 and 2 VWD who are unresponsive or who may have contra-indications to DDAVP. In the present case, Immunate 250 IU was used which is a FVIII/VWF concentrate since the patient was a case of 2N type VWD. Combined estrogen-progestogen drugs and anti-fibrinolytic agents (tranexamic acid and epsilon aminocaproic acid) are also significant in controlling bleeding during oral surgical procedures.<sup>(16,17)</sup>

## Conclusion

VWD is one of the most common inherited bleeding disorder due to the heterogeneity of VWF defects. It is thus imperative to have a thorough knowledge of diagnosis and classification of VWD to provide the best therapeutic approach to VWD patient.

## References

1. Stubbs M, Lloyd J. A protocol for the dental management of von Willebrand's disease, haemophilia A and haemophilia B. *Aust Dent J.* 2001;46(1):37-40.
2. Mann KG. Biochemistry and physiology of blood coagulation. *Thromb Haemost.* 1999; 82(2):165-174.
3. McNicol A, Israels SJ, Gerrard JM. Platelets In: Poller L, editor. *Recent advances in blood coagulation.* Vol. 6. Churchill Livingstone; 1993 p.17-79.
4. Castaman G, Goodeve A, Eikenboom J. Principles of care for the diagnosis and treatment of von Willebrand disease. *Haematologica.* 2013;98(5):667-674.
5. Federici AB, Bucciarelli P, Castaman G, Mazzucconi MG, Morfini M, Rocino A et al. The bleeding score predicts clinical outcomes and replacement therapy in adults with von Willebrand disease: a prospective color study of 796 cases. *Blood.* 2014;123(6):4037-44.
6. Lillicrap D. von Willebrand disease: advances in the pathogenesis understanding, diagnosis and therapy. *Blood.* 2013;122:3735-40.
7. Federici AB. Prophylaxis of bleeding episodes in patients with vonWillebr and's disease, *Blood Transfus.* 2008 Sept;6(2):s26-32.
8. Werner EJ, Broxson EH, Tucker E, Giroux DS, Shults J, Abshire TC. Prevalence of von Willebrand disease in children: a multiethnic study. *J Pediatr.* 1993;123:893-8.
9. Nichols WL, Hulting MB, James AH, Manco-Johnson MJ, Montgomery RR, Ortel T et al. Von Willebrand disease (VWD): evidence-based diagnosis and management guidelines, the National Heart, Lung, and Blood Institute (NHLBI) Expert Panel report (USA). *Haemophilia* 2008;14(2):171-232.
10. Yee A, Kretz CA. Von Willebrand factor: form for function. *Semin Thromb Hemost.* 2014;40:17-27.
11. Federici AB. Current and emerging approaches for assessing von Willebrand disease in 2016. *Int J Lab Hematol.* 2016;38(1):41-9.
12. Hambleton J. Diagnosis and incidence of inherited von Willebrand disease. *Curr Opin Hematol.* 2001;8(5):306-11.
13. Biss TT, Blanchette VS, Clark DS, Bowman M, Wakefield CD, Silva Met al. Quantitation of bleeding symptoms in children with von Willebrand disease: use of a standardized pediatric bleeding questionnaire. *J Thromb Haemost.* 2010;8(5):950-6.
14. Federici AB, Bucciarelli P, Castaman G, Baronciani L, Canciani MT, Mazzucconi MG et al. Management of inherited von Willebrand disease in Italy: results from the retrospective study on 1234 patients. *Semin Thromb Hemost.* 2011;37(5):511-21.
15. De Meyer SF, Deckmyn H, Vanhoorelbeke K. von Willebrand factor to the rescue. *Blood.* 2009;113(21):5049-57.
16. Rodeghiero F, Castaman G, Tosi A. How I treat von Willebrand disease. *Blood.* 2009;114(6):1158-65.
17. Mannucci PM. Treatment of von Willebrand's Disease. *N Engl J Med.* 2004;351(7):683-94.