

Conventional tooth supported overdenture with metal reinforced opposing complete denture: A case report

Himani Jain^{1,*}, Megha Nagpal², Siddharth Narayanan³, Manoj Kumar⁴, Amrita Pawar⁵

^{1,2,3}PG Student, ⁴Professor, ⁵Senior Lecturer, Dept. of Prosthodontics, I.T.S Centre for Dental Studies and Research, Muradnagar, Ghaziabad, Uttar Pradesh, India.

***Corresponding Author:**

Email: jjainhimani90@gmail.com

Abstract

The overdenture is a removable prosthesis that is supported by both selectively retained teeth and the residual ridge or mucosa. It is a versatile and successful means of achieving long-term restoration of a partially edentulous jaw. Insertion and removal of the denture and routine oral hygiene are easy to perform. The many advantages of root retention include alveolar bone maintenance, better prosthesis support, proprioceptive feedback, aesthetics and psychological benefits. As for the treatment plan a conventional complete denture opposing a tooth supported overdenture results in midline fracture of the prosthesis due to increased forces. Therefore it is suggested to fabricate a metal reinforced denture opposing tooth supported overdenture. This paper presents a case report of rehabilitation of a partially edentulous patient with a tooth supported overdenture in mandibular arch with metal reinforced maxillary complete denture.

Keywords: Tooth supported overdenture, Metal reinforced framework, Metal copings, Esthetics, Proprioceptive feedback

Introduction

Mastication, esthetics and phonation are 3 very important factors that should be given due consideration while performing any dental procedure to achieve a successful outcome of treatment. An individual often deals with esthetic, functional, psychological and social impairment following tooth loss.^(1,2) The use of conventional complete dentures/removable prosthesis is often accompanied with dissatisfaction of the patient due to instability of the prosthesis.⁽³⁾ This is commonly seen in the mandibular arch due to the movement of the denture on the soft tissue.⁽³⁾ Thus, the preservation of roots is an effective way to provide adequate retention to the denture and cause effective patient satisfaction.⁽³⁾ In 1978, Rissin et al⁽⁴⁾ found that overdenture patients had a higher chewing efficiency than complete denture patients in their study that compared the masticatory performance in patients with natural dentition, complete denture and over denture.⁽⁴⁾ Crum and Rooney (1978) found that retention of mandibular canine for over denture were the most effective teeth that helped in the preservation of the alveolar bone.⁽⁵⁾ Overdentures involve the use of retained teeth, tooth roots, or dental implants over which a removable complete denture prosthesis is placed. This is not a new concept and practitioners have been successfully using existing tooth structures or retained roots to assist with complete denture treatment for more than a century.⁽⁶⁾ Overdentures can be defined as a prosthesis that covers and is partially supported by natural teeth, tooth roots and dental implants.⁽⁶⁾ Rationale of an overdenture is to preserve a portion of major sensory inputs i.e. input from the periodontal proprioceptors.⁽⁷⁾ The periodontal receptors input are also protective against occlusal overloading.⁽⁷⁾

Overdentures are indicated when the result of the treatment would be same or higher to another line of treatment which involve few remaining healthy teeth with adequate periodontal support.⁽⁷⁾ Other indications would be poor prognosis for complete dentures, poorly defined sublingual fold space and poor residual ridge in edentulous areas.^(7,8,9) It is contraindicated in periodontally weak teeth, which cannot provide adequate support for the denture and patients with poor oral hygiene.^(8,9) Contraindications of endodontic treatment for preserved teeth are vertical fracture, mechanical perforation of root, internal resorption and broken instrument in root canal.^(8,9)

The aim of this clinical case report was to present oral rehabilitation of mandibular tooth-supported overdenture using a metal coping and mesh of metal to prevent fracture of denture and metal reinforced maxillary denture.

Case Report

A 62-year-old male patient reported to the Department of Prosthodontics at I.T.S. Centre for Dental Studies and Research, Muradnagar, with a chief complaint of missing teeth. No relevant medical history affecting the outcome of prosthodontic treatment was noted. His major desire was to improve his masticatory function by retaining natural teeth. On examination it was found that the patient had a completely edentulous maxillary arch (Fig. 1) and a partially edentulous mandibular arch (Fig. 2). The mandibular anterior teeth had sound periodontal and bone support. The patient had a low well-rounded ridge in the maxillary arch, and uneven mandibular ridge. Phonetic examination revealed sufficient inter- arch space.

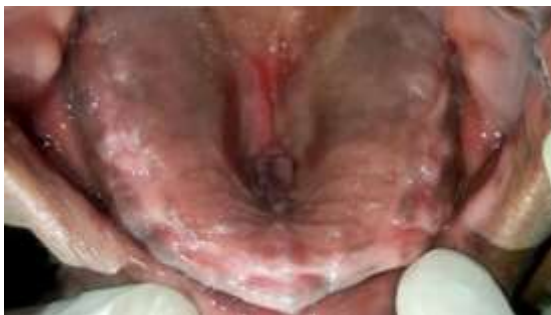

Fig. 1: Maxillary complete edentulous arch

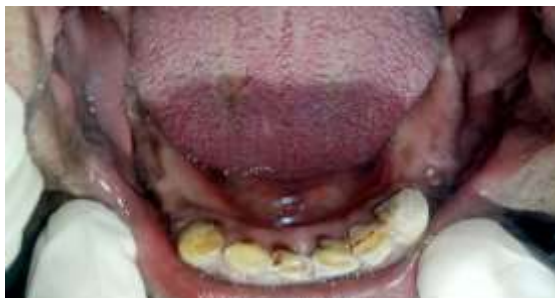

Fig. 2: Mandible partial edentulous arch (Kennedy's class I)

The patient was presented with different treatment options available that included complete dentures, removable partial dentures and dental implants. The patient was hesitant to undergo dental implants due to the need for additional surgery and extended treatment duration as well as an increase in cost of the procedure. Therefore an effective treatment plan was made that included a metal reinforced denture for the maxillary arch and a tooth supported overdenture for the mandibular arch using metal copings and metal meshwork to prevent fracture of the denture.

Clinical procedure: To obtain a favorable crown root ratio and avoid encroachment of the teeth into the interocclusal space the teeth were endodontically treated and reduced in size. A dome shaped preparation with a chamfer finish line was done for all the teeth (Fig. 3). Impressions were made using light body and cast was poured. The metal copings were fabricated on the obtained casts and finished and tried in the patient's mouth and were luted to the abutment teeth (Fig. 4).

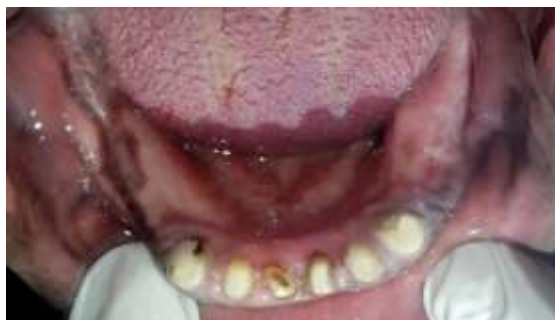

Fig. 3: Dome shaped teeth preparations

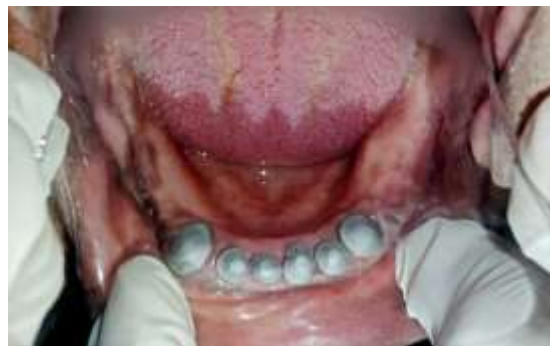

Fig. 4: Metal copings in patient's mouth

A primary impression of the maxillary arch was made with impression compound and a special tray with spacer was fabricated on the primary cast. Using conventional techniques border molding was done and secondary impression was made with zinc oxide eugenol paste (Fig. 5). Cast was poured in die stone and complete denture metal framework was fabricated (Fig. 6).

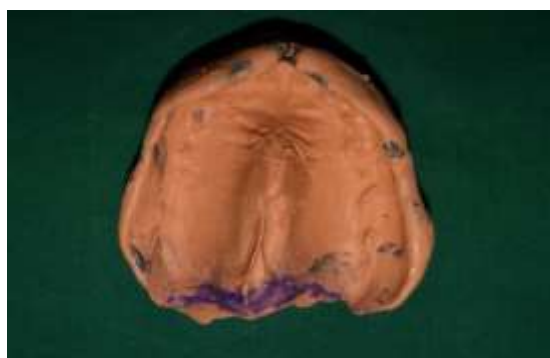


Fig. 5: Secondary impression of maxillary arch



Fig. 6: Maxillary complete denture metal framework

A primary impression of the mandibular arch was made with alginate and a special tray was fabricated on the primary cast after block out. Using conventional techniques border molding was done and secondary impression was made with light viscosity rubber base material (Aquasil TM Ultra Monophase, DECA Regular Set, Dentsply) (Fig. 7). Cast was poured in die stone and base plate was fabricated.

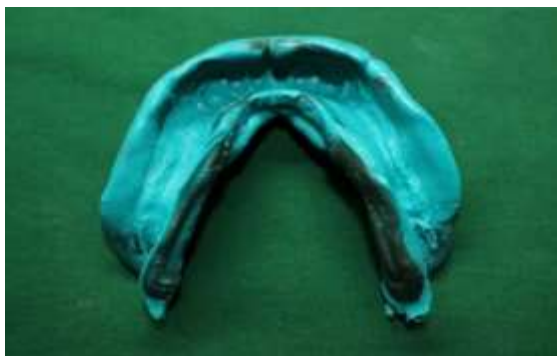

Fig. 7: Border molding and final impression of mandibular arch

Record rims were made and facebow transfer was recorded (Fig. 8) which was followed by recording of jaw relation. Teeth arrangement was done and a try-in (Fig. 9) was accomplished. After a satisfactory try-in, the waxed up denture was processed using heat cure acrylic. Mandibular denture has recess areas on the intaglio surface of the denture to accommodate the abutments.

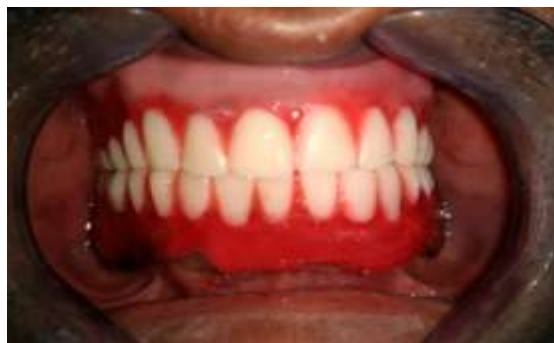

Fig. 9: Try in

The dentures were finished, polished and inserted into the patient's mouth (Fig. 10). Proper oral hygiene instructions along with practice for removal and insertion of the mandibular denture were given to the patient and the patient was recalled for periodic follow up appointments.

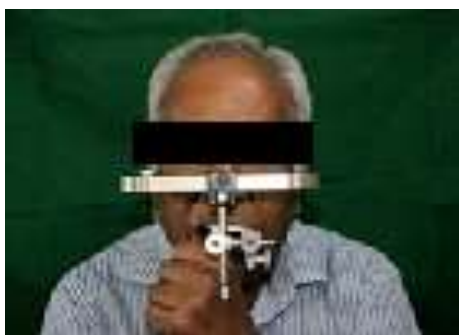

Fig. 8: Facebow transfer

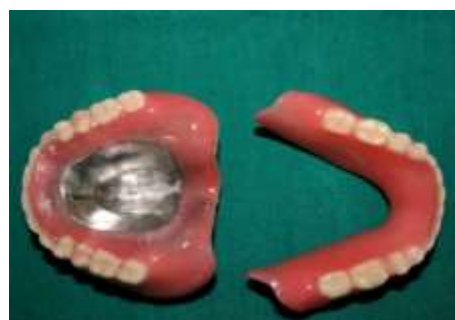

Fig. 10: Final Prosthesis

Discussion

Preventive prosthodontics deals with the use of procedures to delay or eliminate any kind of future problems that may be faced by the patient.^(7,8,9) The concept of overdentures basically deals with retaining natural teeth so as to preserve the residual ridge and the overlying soft tissues.^(7,8,9) Tallgren⁽¹⁰⁾ observed that the anterior mandibular ridge resorbed four times faster than the maxillary ridge in case of conventional dentures. Two 5 year studies^(5,11) concluded that retaining of the mandibular canines led to the preservation of the alveolar bone. Patients with overdenture were found to have a chewing efficiency that was one third higher than that of conventional denture wearers.^(4,11) The psychological advantage of



retaining the natural teeth in cases of patients with overdenture has been well documented in literature.^(11,12) Tooth supported overdenture can be an effective means in preventive prosthodontics since it conserves the few remaining natural teeth and in the process conserves the alveolar ridge.⁽¹³⁾ Two schools of thought can be related to this treatment; the first one states that there is continued preservation of alveolar bone around the retained teeth; while the second states that there is retention of the periodontal sensory mechanism that plays a part in the guidance and monitoring of the gnathodynamic functions.⁽¹³⁾ The most common failure seen with mandibular overdenture is its fracture at the midline due to the absence of central and lateral incisors in order to overcome this metal mesh incorporated in the denture during the packing of the heat cure acrylic.⁽¹⁴⁾ The improvement of the mechanical strength of acrylic denture bases using reinforcements has been the focus of research for many years and different reinforcement agents like cobalt-chromium wires, metallic wires have been found to have increased the strength of the Polymethyl methacrylate matrix considerably. The main advantage of mandibular overdenture is better retention and stability of the final prosthesis. The maxillary overdenture is of great value when it opposes remaining mandibular anterior teeth, because it aids in conserving the ridge against resorption from masticatory stresses.⁽¹⁴⁾ Fenton and Hahn (1978)⁽¹⁵⁾ showed the presence of caries on the abutment teeth and focused on the importance of application of sodium fluoride gel at regular intervals in order to reduce the cariogenic activity. Derkson and MacEntee (1982)⁽¹⁶⁾ showed that 0.4% stannous fluoride gel had a beneficial effect on the gingival health of the abutments. Root canal therapy is an important phase in overdenture treatment and single rooted or double rooted teeth with accessible canals are generally preferred.⁽¹⁷⁾ The short coping design showed least amount of stress than any of the other design like tapered coping design & tapered coping with occlusal bearing design.⁽¹⁷⁾ This design minimizes horizontal torque on the roots and provides ease of maintenance of oral hygiene.⁽¹⁷⁾ Proper patient selection and establishment of a mode of treatment satisfying both the patient and the dentist are significant factors that lead to success of an overdenture treatment.

Conclusion

Improvement in retention, stability and maintenance of proprioception make root supported overdenture a better alternative to conventional dentures. Prosthetic rehabilitation of partial anodontia helps in the improvement of function and esthetics along with providing a psychological boost in the morale of the patient especially if the patient is young. Good patient awareness about maintenance of proper oral hygiene is very important if the treatment has to remain satisfactory for a long period of time.

References

1. Okoje VN, Dosumu OO, Alonge TO, Onyeano C. Tooth loss: Are the patients prepared? *Niger J Clin Pract* 2012;15:172-5.
2. De Marchi RJ, Hilgert JB, Hugo FN, Santos CM, Martins AB, Padilha DM. Four-year incidence and predictors of tooth loss among older adults in a southern Brazilian city. *Community Dent Oral Epidemiol* 2012;40:396-405.
3. Brkovic-Popovic S, Stanisic-Sinobad D, Postic SD, Djukanovic D. Radiographic changes in alveolar bone height on overdenture abutments: A longitudinal study. *Gerodontology* 2008;25:118-223.
4. Rissin L, House JE, Manly R, Kapur K. Clinical comparison of masticatory performance and electromyographic activity of patients with complete dentures, overdentures, and natural teeth. *J Prosthet Dent* 1978;39:508-11.
5. Crum RJ, Rooney Jr GE. Alveolar bone loss in overdentures: a 5-year study. *J Prosthet Dent* 1978;40:610-3.
6. Sharma R, Kumar A, Chopra D, Tewari D. Implant-supported Overdenture. *J Dent Sci Oral Rehab* 2014;5:139-41.
7. Shrivastava R, Awinashe V, Srivastava R. Simple Overdenture Technique, Lasting Results-A Case Report. *J Prosthet Dent* 2012;1:37-41.
8. Winkler S. *Essentials of Complete Denture Prosthodontics*, 2nd Ed. WB Saunders Co., Philadelphia, 2000.
9. Rahn A, Heartwell C. *Textbook of Complete Dentures*, 5th Ed. WB Saunders Co., Philadelphia, 1993.
10. Tallgren A. The continuing reduction of the residual alveolar ridges in complete denture wearers: a mixed-longitudinal study covering 25 years. *J Prosthet Dent* 1972;27:120-32.
11. Gupta N, Goyal D, Agarwal M, Gupta P, Mathur M. Over denture with access post system: a case report. *Int J Dent Clin* 2012;4:77-9.
12. Fiske J, Davis D, Frances C, Gelbier S. The emotional effects of tooth loss in edentulous people. *Br Dent J* 1998;184:90-3.
13. Hatim AN, Mohammed TS. Solving complete denture problems by the use of Overdenture: Clinical Case Report. *Al – Rafidain Dent* 2011;11:238-43.
14. Polyzois GL. Reinforcement of denture acrylic resin: The effect of metal inserts and denture resin type on fracture resistance. *Eur J Prosthodont Restor Dent* 1995;3:275-8.
15. Fenton AH, Hahn N. Tissue response to overdenture therapy. *J Prosthet Dent* 1978;40:492-8.
16. Derkson GD, MacEntee MM. Effect of 0.4% stannous fluoride gel on the gingival health of overdenture abutments. *J Prosthet Dent* 1982;48:23-6.
17. Warren AB, Caputo AA. Load transfer to alveolar bone as influenced by abutment design for tooth-supported dentures. *J Prosthet Dent* 1975;33:137-48.