

## Use of Custom Bar in a Case of Implant Supported Over Denture – Case Report

**Amit Khattak**

Officer Commanding, Military Dental Centre Shillong,  
East Khasi Hills, Shillong - 793001, Meghalaya.  
E-mail: captkhat@rediffmail.com

---

### **Abstract:**

Denture fabrication for patients with severely deficient mandibular ridges has been a challenging task for dentists. The widespread use of implants in dentistry has opened up a wide variety of treatment options for rehabilitation of such patients. Depending on the condition of the hard and soft tissues the treatment plan can be customized for the patient. A case is presented where an implant supported overdenture is fabricated for a patient with severely resorbed mandibular ridge using three implants and a customized bar with clip attachments.

**Key Words:** Overdenture, Customized bar, Complete denture

---

### **Introduction:**

A severely resorbed ridge makes ideal denture (a denture with optimum retention, support and stability) fabrication a difficult task. The difficulty is compounded in the mandible due to mobile structures like tongue and cheeks in the proximity which tend to dislodge the denture more in absence of adequate support from the edentulous ridge. The advent of implants has brought forth numerous options for complete denture fabrication even in the absence of adequate support and retention from the ridge per se.

An implant supported overdenture can be fabricated using one to five implants in an arch depending on the retention and support which is available from the edentulous ridge. Ball-head implants, single stage/two stage implants with or without bar attachments can all be used for overdenture fabrication depending on the ridge conditions, the knowledge and expertise of the operator and the lab facilities available. The case report presents a case of complete denture fabrication for a patient with severely resorbed mandible using placement of three implants and a customized bar with clip attachments.

### **Case Report:**

A 68 year old lady patient reported to the Out Patient Department with complaint of inability to chew with her dentures. On examination it was found that the maxillary denture was retentive and well fitting, however the mandibular denture was lacking in retention as well as stability. She had been wearing complete dentures for the last nine years. Her present dentures were well fitting initially but became loose over time to reach the present state where she could not use them to masticate. Intraoral examination revealed a severely resorbed mandibular ridge (Fig.1).

Various treatment options were explained to the patient, the patient decided to go in for an option which offered improvement in masticatory ability

with minimum invasive surgery and hence we decided to go in for implant supported denture to improve the retention and support for the dentures. Three implants were placed in interforamina region to counter the anterior curvature of the mandible, by placing three implants we could improve the antero-posterior spread significantly without encroaching on tongue space. Initially conventional dentures were fabricated for the patient. A diagnostic OPG was then taken to plan areas of implant placement. Denta scan would have been a better option but it was unavailable at the place of surgery, dimensions were decided by taking an OPG with metal balls at the proposed site of implant placement and then using the formula:

$$\frac{X1}{X2} = \frac{Y1}{Y2} \text{ or } X1 = \frac{Y1 \times X2}{Y2}$$

Where

X1 = Actual distance between lower border of mandible and crest of ridge

X2 = Distance between lower border of mandible and crest of ridge on radiograph

Y1 = Actual size of metal ball

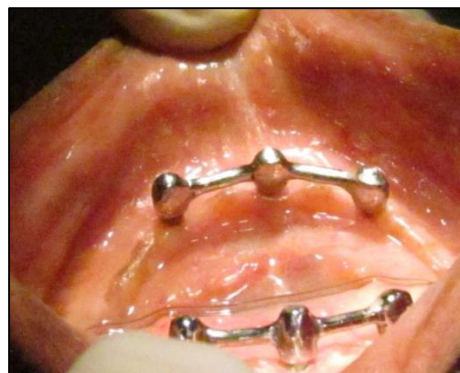Y2 = Size of metal ball on radiograph

Radiographic examination revealed sufficient height of bone between the two mental foramina for placement of three implants. Literature review indicates that implants placed in the anterior mandible (anterior to the foramen) have a success rate better than 95 percent.

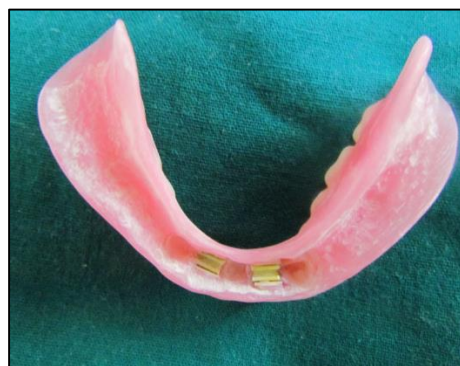The patient was administered 1000mg Amoxicillin one hour prior to surgery as a loading dose. Under aseptic conditions after suitable osteotomy three Bio-horizon implants were placed – one close to the midline and one each in the canine region of right and left side of mandible (Fig.2). Adequate primary stability was present on placement of the implants. The patient was prescribed Amoxicillin 500 mg and Ibuprofen-Paracetamol

combination thrice a day for three days. The patient was instructed to eat a soft diet for one week. Chlorhexidine 0.12% mouthwash was prescribed to be used three times a day starting 1 day post of surgery until seven days post operative. The patient was then dismissed.

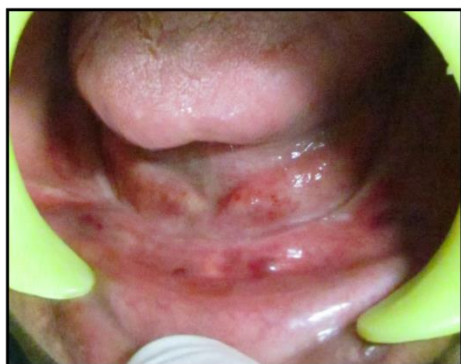The next day impressions were made, lab analogs attached and the impression poured. A customized framework of copings and bar was fabricated over the analogs in self-cure acrylic resin. This framework was tried in the patient's mouth, cast, polished and tried again intraorally. The framework was cemented with dual cure resin cement (Fig.3). Retention clips and metal encapsulators were placed over the bar and then transferred to the undersurface of the mandibular denture where adequate space had been created for this attachment assembly (Fig.4). The dentures were tried and minor adjustments done. They were then finished and polished (Fig.5). The patient was trained in insertion and removal of the denture and educated in denture care. Oral hygiene instructions were given. The follow up protocol included routine checkups every month. Hygiene maintenance was regularly reinforced. The patient was extremely satisfied with her new set of dentures (Fig.6).



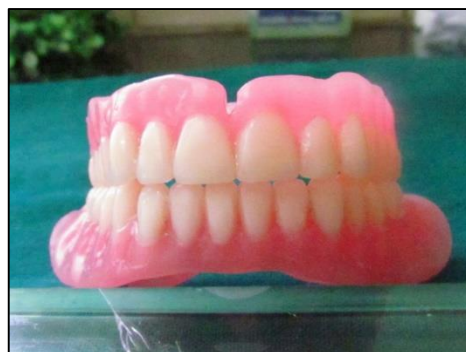**Fig.3: Bar in situ.**



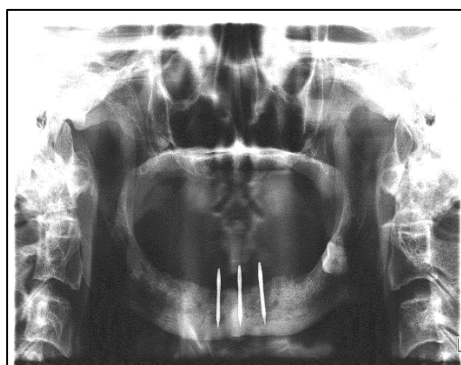
**Fig.4: Metal encapsulator and retention clips transferred to denture base**



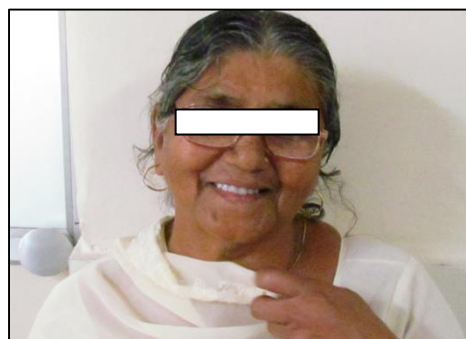**Fig.1: Pre op photograph showing severely resorbed mandibular ridge**



**Fig.5: Dentures in occlusion**



**Fig.2: Three single piece Implants (D-2.4mm, L-13mm) placed**



**Fig.6: Satisfied patient**

**Discussion:**

The conventional denture may meet the needs of many patients; others require more retention, stability, function and esthetics, especially in the mandible. The implant-supported prosthesis is an alternative to the conventional removable denture (1). Implant-supported mandibular overdenture treatment permits better biting and chewing function than conventional complete dentures (2) and may be more satisfying for edentulous patients than new conventional dentures (3). The use of implants in elderly completely edentulous patients who request better stabilization of the mandibular denture, is now well documented (4). In addition to the advantages offered by conventional tooth supported overdentures, implants have the benefit of offering more predictable results.

The complete denture prosthesis can be of fixed design or removable overdentures can be fabricated. The fixed design for implant prosthesis is only appropriate for patients with minimal resorption of the alveolar bone and an optimal maxillomandibular relationship. The removable overdenture may be indicated from the outset and is no longer restricted to patients with a compromised situation in which fixed implant prostheses are not feasible (5).

Using two or three implants for an overdenture is a very effective manner of increasing the support with minimal surgery and cost. A number of attachments like ball and O-ring, bar and clip are available for fabrication of implant supported removable overdentures. There has been no difference reported in the survival rate of implants when using bar with clip or ball attachments (6), however, the ball and O-ring and locator attachments normally used with implants tend to wear away on routine usage and require frequent replacements (7). In contrast the bar attachment not only offers better support but lesser maintenance and replacement of components. The bar supported overdenture also provides the advantage of splinting of implants, which improves the retention and stability, reduces forces on implants and therefore reduces crestal bone loss (8). Due to the excellent stability of this type of overdenture the extensions of the denture base can also be kept to a minimum.

Implant-supported removable prostheses definitely improve patients' satisfaction with treatment and quality of life. Improvements, especially in attachment elements have made this treatment method very predictable. However, some mechanical complications associated with implant-supported overdentures and implant-supported removable partial dentures like loss of retention of attachment systems, the need to replace retention elements and to relin or repair the resin portion of the denture, and implant fracture still remain. Despite

their success, implant-supported removable prostheses require periodic maintenance (9).

**Conclusion:**

Implant-supported overdentures in the mandible provide predictable results with improved stability, retention, function and patient satisfaction compared with conventional dentures. Implants placed in the anterior mandible have a very high success rate. When planning treatment for patients with severely resorbed edentulous mandibles, clinicians should consider the implant-supported prosthesis.

**References:**

1. Doundoulakis JH1, Eckert SE, Lindquist CC, Jeffcoat MK. J Am Dent Assoc. The implant-supported overdenture as an alternative to the complete mandibular denture. 2003 Nov; 134(11):1455-8.
2. Bakke M, Holm B, Gotfredsen K. Masticatory function and patient satisfaction with implant-supported mandibular overdentures: a prospective 5-year study. Int J Prosthodont. 2002 Nov-Dec; 15(6):575-81.
3. Emami E, Heydecke G, Rompré PH, de Grandmont P, Feine JS. Impact of implant support for mandibular dentures on satisfaction, oral and general health-related quality of life: a meta-analysis of randomized-controlled trials. Clin Oral Implants Res. 2009 Jun; 20(6):533-44.
4. Regina Mericske-Stern. Treatment outcomes with implant-supported overdentures: Clinical considerations. J Prosthet Dent. 1998; 79(1):66-73.
5. Nicola U, Zitzmann, Carlo P, Marinello, Nicola U, Zitzmann, Carlo P, Marinello. Treatment plan for restoring the edentulous maxilla with implant-supported restorations: Removable overdenture versus fixed partial denture design. J Prosthet Dent. 1999; 82(2):188-196.
6. Bergendal T, Engquist B. Implant-supported overdentures: a longitudinal prospective study. Int J Oral Maxillofac Implants. 1998; 13(2):253-262.
7. Sethi T, Kheur M, Harianawala H, Jambhekar S, Kantharia N, et al. Immediate Loading of a Single Implant Retained Mandibular Complete Denture Utilising a Magnetic Attachment: A Case Report. J Dent App. 2014; 1(3): 33-36.
8. Misch CE. Dental Implant Prosthodontics. St Louis: Elsevier Mosby 2005: 577-81
9. Vahidi F1, Pinto-Sinai G. Complications associated with implant-retained removable prostheses. Dent Clin North Am. 2015 Jan; 59(1):215-26.