

## Role of MRI in evaluation of Compressive myelopathy

Aparna Dodia<sup>1,\*</sup>, Palak Patel<sup>2</sup>, Arochala Taxak<sup>3</sup>, Harshad Shah<sup>4</sup>, Asutosh Date<sup>5</sup>

<sup>1,2,3</sup>Resident, <sup>4</sup>Professor & HOD, <sup>5</sup>Professor, Dept. of Radiology, CU Shah Medical College & Hospital, Surendranagar, Gujarat

**\*Corresponding Author:**

Email: dodiaaparna15491@gmail.com

### Introduction

- Compressive Myelopathy is the term used to describe the spinal cord compression either from outside or within the cord itself.
- Spinal cord injury is the major cause of quadriplegia and disability.
- Plain radiographs have a low sensitivity for identifying traumatic spinal lesions. Therefore trauma victims with plain films negative for spine injury but with a high clinical suspicion of injury should undergo MR for a more definitive evaluation of the spine.
- MRI is the definitive modality in assessing spinal soft tissue injuries, especially in evaluation of spinal cord, intervertebral discs and ligaments.
- In case of spinal trauma, MRI demonstrates the relationship of fractured / subluxated vertebral bodies to the cord and highlights a significant stenosis. The signal abnormalities within this cord can be identified, helping to localize and define the degree of trauma.
- In case of suspected cord compression due to neoplasm MRI serves as an excellent method for imaging tumor involving spinal column, canal and cord.
- Many spinal cord diseases are reversible if recognized and treated at an early stage; thus they are amongst the most critical of all Neurologic emergencies.
- The role of MRI is to distinguish compressive from non-compressive myelopathy. Once compressive lesions have been excluded, non-compressive cause of acute Myelopathy that are intrinsic to the cord are considered primarily vascular, inflammatory and infectious etiologies.

### Objectives of the study

- To evaluate various causes of compressive myelopathy.
- MR characterization of spinal cord compressive lesions.
- To classify the lesions based on location into extradural / intradural compartments and according to their most commonly involved level of spinal cord.

### Materials and Method

- The data was collected from patients referred to the Department of Radiodiagnosis, C.U. Shah Medical College and Hospital, Surendranagar, Gujarat.
- The patients who were clinically suspected of compressive myelopathy were investigated with MRI. The study group included a sample size of 30 patients from April 2016 to July 2016.

#### Inclusion criteria:

- All age groups
- Both sexes
- All symptomatic cases of compressive myelopathy

#### Exclusion criteria

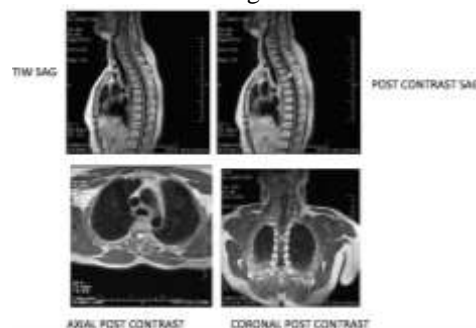
- Cases of non – compressive myelopathy.
- Degenerative disc herniation.

#### Equipment

- Seimens 1.5 tesla MRI machine- MAGNETOM ESSENZA.

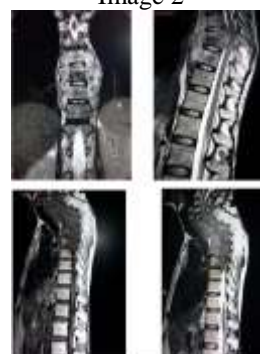#### Intradural extramedullary neurofibroma with extension into neural foramina

Image 1



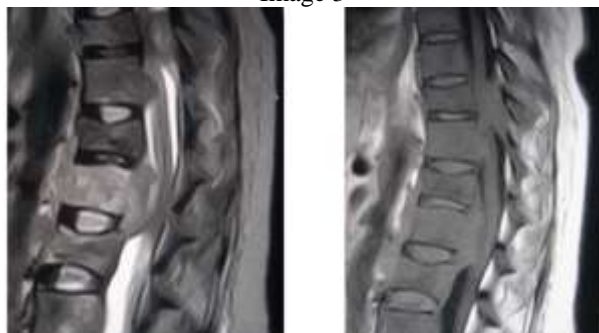#### Tuberculosis of spine with cold abscess

Image 2



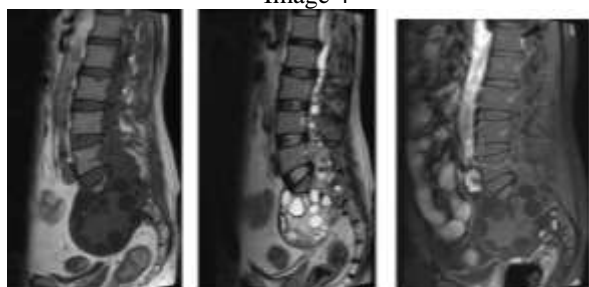
**Multiple Metastasis**

Image 3



**Spinal Hydatid**

Image 4



**Traumatic Myelopathy**

Image 5

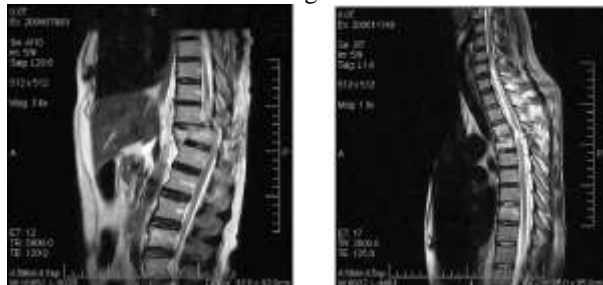

Table 1

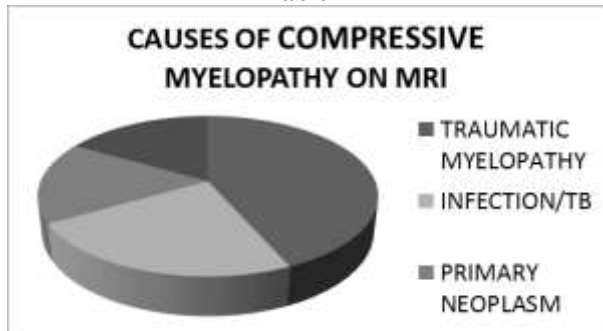


Table 2

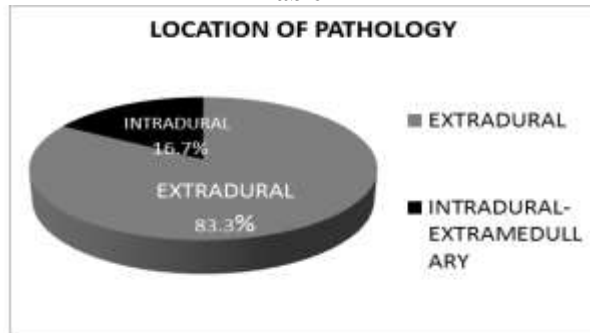


Table 3: Causes according to various compartments

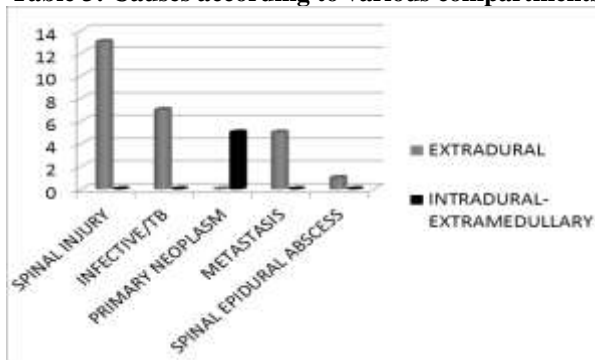


Table 4

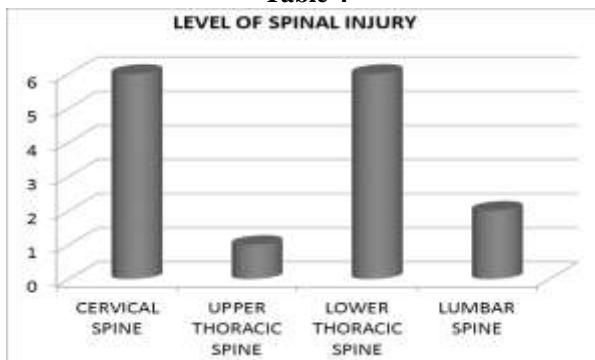


Table 5

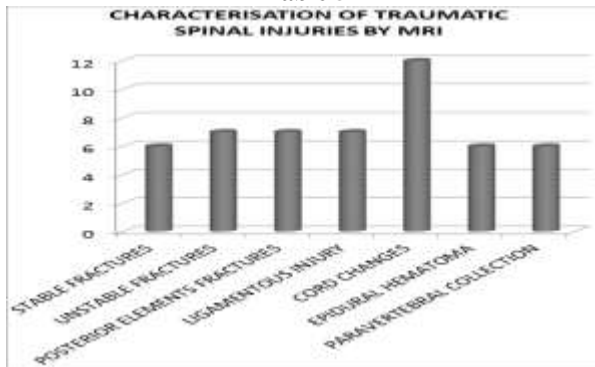
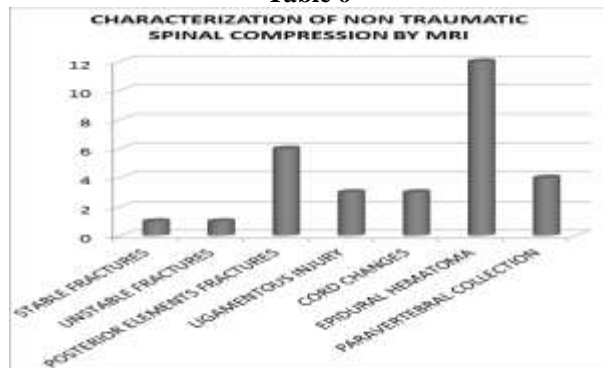


Table 6



### Discussion

- The ability of MRI to show the spine and spinal cord with greater sensitivity and specificity than myelography and CT is well established for trauma, neoplastic, congenital, & degenerative disorder.
- MRI is the modality of choice to image spine and spinal cord pathologies because of its ability to depict cross sectional anatomy in multiple planes without ionizing radiation, exquisite soft tissue delineation and non – invasiveness.
- In our study of 30 cases of compressive myelopathy we found various different causes for compression and amongst these trauma (13) was the most common followed by infectious causes (07), primary neoplasms (05) and secondary neoplasm (05).
- Most common causes for spinal trauma are RTA and fall from height.
- Extradural compressive lesions (83.3%) are the most common cause for compressive myelopathy.
- Spinal injuries and infections are the common causes for extradural compression while primary neoplasms are more common in intradural compartment in our study.
- Majority of the patients of spinal injury and primary neoplasms are among adults/middle age group(20-49 years). While majority of patients of spinal infection and metastasis are in the older age group(>50 years).
- Most of the spinal injury occur in male population while spinal infection, primary neoplasms as well as metastasis are more common in female population.
- In spinal injury, the common site involved is the thoracic spine followed by cervical spine.

### Conclusion

- MRI is the definitive modality in assessing soft tissues of the spine and spinal cord abnormalities.
- It is the best modality to evaluate cord edema/contusion and integrity of the intervertebral discs and ligaments.

- MRI is very sensitive and considered the imaging modality of choice to detect and characterize the spinal tumors and spinal infections.
- So in the end I can conclude that MRI is very definitive, accurate, though costly but non invasive, radiation free modality for evaluation of Compressive myelopathy.

### References

1. Choi KH, Lee KS, Chung SO, et al. Idiopathic transverse myelitis: MR characteristics. *AJNR Am J Neuroradiol.* 1996;17:1151–60.
2. Matsumoto M, Toyama Y, Ishikawa M, Chiba K, Suzuki N, Fujimura Y. Increased signal intensity of the spinal cord on magnetic resonance images in cervical compressive myelopathy: does it predict the outcome of conservative treatment? *Spine.* 2000;25:677–82.
3. Morio Y, Teshima R, Nagashima H, Nawata K, Yamasaki D, Nanjo Y. Correlation between operative outcomes of cervical compression myelopathy and MRI of the spinal cord. *Spine.* 2001;26:1238–45.
4. Chen CJ, Lyu RK, Lee ST, Wong YC, Wang LJ. Intramedullary high signal intensity on T2-weighted MR images in cervical spondylotic myelopathy: prediction of prognosis with type of intensity. *Radiology.* 2001;221:789–94.
5. de Seze J, Lanctin C, Lebrun C, et al. Idiopathic acute transverse myelitis: application of the recent diagnostic criteria. *Neurology.* 2005;65:1950–3.
6. Brinar VV, Habek M, Brinar M, Malojcic B, Boban M. The differential diagnosis of acute transverse myelitis. *Clin Neurol Neurosurg.* 2006;108:278–83.
7. Fernandez de Rota JJ, Meschian S, Fernandez de Rota A, Urbano V, Baron M. Cervical spondylotic myelopathy due to chronic compression: the role of signal intensity changes in magnetic resonance images. *J Neurosurg Spine.* 2007;6:17.
8. Brinar VV, Habek M, Zadro I, Barun B, Ozretic D, Vranjes D. Current concepts in the diagnosis of transverse myelopathies. *Clin Neurol Neurosurg.* 2008;110:919–27.
9. Kumar N. Pearls: myelopathy. *Semin Neurol.* 2010;30:38–43.
10. Kelley BJ, Erickson BJ, Weinschenker BG. Compressive myelopathy mimicking transverse myelitis. *Neurologist.* 2010;16:120–2.
11. Awad A, Stüve O. Idiopathic transverse myelitis and neuromyelitis optica: clinical profiles, pathophysiology and therapeutic choices. *Curr Neuropharmacol.* 2011;9:417–28.
12. Kang YS, Lee JW, Koh YH, et al. New MRI grading system for the cervical canal stenosis. *AJR Am J Roentgenol.* 2011;197:W134–40.