

Dolicho ectasia of vertebro basilar artery presenting as Trigeminal neuralgia: Case report

Shigha Koli Ramesh^{1,*}, Subodh Raju²

¹Neurosurgeon, ²Chief Neurosurgeon, Dept. of Neurosurgery, Kamineni Hospital, Hyderabad, Telangana

***Corresponding Author:**

Email: srameshns1@gmail.com

Abstract

We present a case of trigeminal neuralgia caused by vertebrobasilar dolicho ectasia treated with micro vascular decompression. A 56-year-old presented with recurrent lancinating left facial pain in V2 and V3 trigeminal territories. On Evaluation, found to have Dolicho ectasia of vertebro basilar artery system causing compression over trigeminal nerve. On initial conservative management patient had temporary relief with resurgence of pain in increased in severity and number of episodes of facial pain. He underwent Retro mastoid craniotomy and micro vascular decompression of trigeminal neuralgia.

Introduction

Trigeminal neuralgia is well known entity, characterized by paroxysmal, electric shock like pain in trigeminal nerve distribution. Dolicho ectatic vertebro basilar system presenting as trigeminal neuralgia is a rare entity. Vertebrobasilar dolicho ectasia (VBD) is a rare disease characterized by significant expansion, elongation, and tortuosity of the vertebrobasilar arteries. We present a case of Trigeminal neuralgia due to Vertebrobasilar dolicho ectasia (VBD) and successfully managed with micro vascular decompression (MVD).

Case Presentation

56 year old male Non Diabetic, Hypertension (denovo) presented with recurrent lancinating left facial pain in V2 and V3 trigeminal territories for 8 months. Pain is occurs in bursts lasting less than 2 minutes and severe in intensity. On evaluation, MRI with CISS sequences showed both vertebral arteries are dilated and tortuous. Tortuous right vertebral artery crossing the midline, joining the left vertebral artery forming the basilar artery. Basilar artery is tortuous, dilated measuring 6mm compressing left trigeminal nerve and anterior aspect of pons.[Fig. 1] Patient initially had temporary relief with conservative management but had resurgence of pain. He was explained and taken up for Left retro mastoid craniotomy and micro vascular decompression of trigeminal nerve. Intra operatively trigeminal nerve was significantly compressed and flattened by large artery [Fig. 2]. Post-operative period was unevent full. No similar episodes of pain in trigeminal nerve distribution.

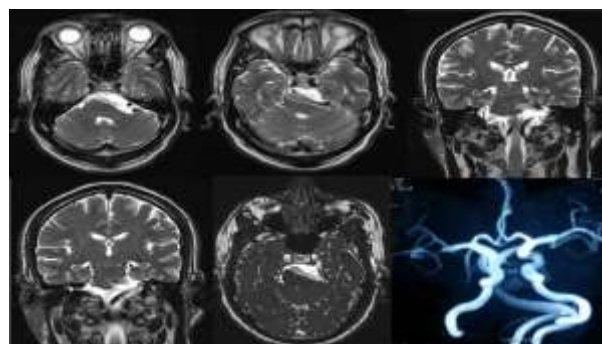


Fig. 1: MRI brain with Angio: Bilateral vertebral arteries are dilated and elongated forming basilar arteries on left side. Basilar artery is also dilated and during its course it is significantly compressing the brain stem

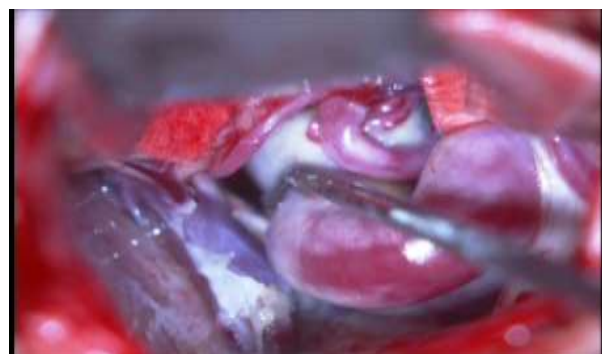

Fig. 2: Intra op image: Ball probes separated the dilated and tortuous artery from the trigeminal nerve

Discussion

Dolicho ectasia of intracranial arteries is a rare entity. Vertebro basilar dolichoectasia characterized by significant expansion, elongation and tortuosity of the vertebro basilar artery. No current data exists on incidence in general population angiographic and autopsy results suggests that over all incidence less than 0.05 %.⁽⁷⁾

Elongation of vertebro basilar artery system is considered if the basilar artery lies lateral to the margin of clivus or dorsum sellae or if it bifurcates above the plane of supra sellar cistern. Ectasia is to be considered to be present if the basilar artery has a diameter greater than 4.5mm.⁽⁶⁾

Etiology of VBD is not clear, histological examination revealed wide spread defects and fractures of internal elastic lamina which were secondary to smooth muscle atrophy and reticular fiber deficiency.⁽³⁾ Other authors consider dolicho ectasia may be due to congenital anomaly and its evolution may be influenced by arterial hypertension and super imposed atherosclerosis.⁽⁵⁾ VBD can develop without any symptoms. In cases of obvious symptoms, most common symptom is ischemic stroke, followed by brainstem and cranial nerve compression, hydrocephalus and cerebral hemorrhage.⁽⁷⁾ Trigeminal and facial nerves are the commonest cranial nerves involved. In patients with VBD, the compression has a very slow progression, but brainstem can functionally tolerate severe distortion without clinical manifestations, which may explain why most patients with VBD are asymptomatic.⁽⁴⁾

Proposed mechanism for Trigeminal neuralgia is vascular compression at root entry zone (REZ). Root entry zone vulnerable to continued pulsatile pressure which may result in focal demyelination and short circuiting of impulses.⁽¹⁾ Decompression of nerve root produces rapid relief of symptoms due to separation of demyelinated axons from focal distortion. It reduces and abolishes spontaneous generation of impulses and prevents their epileptic spread.

A variety of treatments are available to control VBD-induced drug-refractory trigeminal neuralgia includes Micro vascular decompression, radiofrequency ablation, gamma-knife, percutaneous balloon compression and botulinum toxin injection.

Micro vascular decompression for trigeminal neuralgias has been proven to be highly effective and safe surgical procedure for trigeminal neuralgia decreasing the effects of neurovascular compression. It holds good even in vertebrobasilar artery dolichoectasia. Long-term follow-up studies showed most postoperative recurrences for trigeminal neuralgia occurred in the first 2 years after surgery. Female sex, H/o facial pain more than 8 years and a lack of immediate postoperative cessation of trigeminal neuralgia were significant predictors of recurrence.⁽²⁾

In Natural course VBD patients may experience mainly cerebrovascular event. There are various mechanisms by which VBD may promote brain ischemia, including occlusion of small perforating vessel, distortion and stretching of the branches of basilar artery (duret hemorrhages), reduction of antegrade flow in dilated artery and superimposed atheromatous changes. This is very essential information in patient outcome in case of trigeminal

neuralgia with VBD because natural tendency to over value facial pain instead of dolicho ectasia and its complications

In our case, patient responded to Micro vascular decompression and he is being regular follow up for other symptoms of Vertebro basilar artery dolicho ectasia and Trigeminal neuralgia recurrence.

References

1. A.R. Moller, "The cranial nerve vascular compression syndrome: II. A review of pathophysiology," *Acta Neurochirurgica* (1991) 113,24-30.
2. Jorge Luiz Kraemer, Arthur de Azambuja, Pereira Filho, Gustavo de David, Mario de Barros Fariaq. Vertebrobasilar dolichoectasia As a cause of trigeminal neuralgia, the role of microvascular decompression. *Neuropsychiatr* (2006) 64,128-31.
3. Lou M, Caplan LR. Vertebrobasilar dilative arteriopathy (dolichoectasia). *Annals of the new york academy of sciences*(2010) 1184,121-33.
4. M. Baquero, "Vertebro-basilar dolichoectasia," *Revista de Neurologia* (1998) 26,143-48.
5. S.G. Passero and S. Rossi. "Natural history of Vertebro basilar artery dolicho ectasia". *Neurology*. (2008)70,66-72.
6. S. love and H.B. Coakham. Trigeminal neuralgia: pathology and pathogenesis *Brain*(2001) 124, 2347-60.
7. Yong-Jie Yuan, Kan Xu, Qi Luo, Jin-Lu Yu. Research Progress on Vertebrobasilar Dolicho ectasia. *International Journal of Medical Sciences*(2014)11,1039-48.