

Shaft humerus fractures treated with interlocking nails vs. locking compression plates; a comparative study

Angad Jolly^{1,*}, Rahul Bansal²

^{1,2}P.G. Student, Dept. of Orthopaedics, Mysore Medical College and Research Institute

***Corresponding Author:**

Email: angad.yahoo.hotmail@gmail.com

Abstract

Shaft humerus fractures account for approximately 2 to 3 % of all fractures and are commonly encountered in clinical practice. Many can be managed conservatively and those that are operated can be treated by either plating or nailing techniques. This study was done to compare the two commonly performed surgical techniques. 60 patients who were admitted with fracture shaft of humerus and given operative treatment were studied for functional outcome, radiological outcome and complications of the procedure. 30 of these patients were treated with ORIF with Locking Compression plates and the remaining 30 were treated with CRIF with IMIL nails. The two groups were comparable at baseline when the demographic characteristics were compared. Follow up showed a statistically significant difference in the operative time, operative blood loss and hospital stay post-surgery all in favour of the IMIL nail group. Functional outcome in both the groups was comparable except for a statistically significant increase in the incidence of shoulder related complications, and increased risk of implant failure in the IMIL nail group. No significant difference was seen in the radiological outcome between the groups. We concluded that ORIF with locking compression plates is a better surgical option for managing humerus shaft fractures as compared to CRIF with IMIL nails due to a better functional outcome and lesser chance of implant failure, despite there being a larger volume of intra-op blood loss and longer duration of surgery.

Keywords: Shaft Humerus, Locking Compression Plates, Intramedullary Nails.

Introduction

Shaft humerus fractures account for approximated 2 to 3 % of all fractures and are commonly encountered in clinical practice.⁽¹⁾ Many of these fractures can be managed conservatively with functional braces or hanging casts and acceptable results are obtained with this method as malunion is tolerated well in humerus.⁽²⁾ There exist definitive indications for internal fixation of shaft humerus fractures including compound fractures, radial nerve injuries, polytrauma, floating elbow or shoulder, comminuted fractures, pathological fractures and vascular injuries.⁽³⁾ Apart from this there is an increasing trend towards internal fixation of humerus shaft fractures to avoid complications of conservative treatment like malunion, non-union and shoulder stiffness. The common techniques used to internally fix humerus shaft fractures include plate and screw fixation and intramedullary nailing. Both these procedures come with inherent advantages and disadvantages. Plating demands extensive soft tissue dissection and periosteal stripping with a long operating time but can provide a more stable fixation, can reduce chances of malunion and it allows for direct visualization of the radial nerve. Intramedullary nailing on the other hand offers lesser operating time and minimal soft tissue damage at the cost of shoulder related complications, iatrogenic radial nerve injury and incomplete reduction of the fracture.⁽⁴⁾ Thus this study was done to compare the functional results, radiological outcomes and complications of two methods available to fix humerus shaft fractures; i.e. ORIF with locking compression plates and CRIF with Intramedullary nails.

Materials and Methods

A prospective comparative study was conducted in K.R Hospital, Mysore, attached to Mysore Medical College and Research Institute between 2013 and 2016. All patients who were included in the study were thoroughly examined after history taking and an informed consent was taken. The patients were randomly assigned into either the plating or the nailing group. 30 of the patients underwent ORIF with locking compression plates and 30 underwent CRIF with intramedullary interlocking nails. All patients aged more than 17 years (with humerus physes closed), with shaft humerus fractures less than 2 weeks old requiring surgery were included in the study. Patients aged less than 17 years, those with pathological fractures, those with neurovascular deficits, patients medically unfit for surgery and compound fractures of Grade 3 were excluded from the study.

The patients in the plating group were operated with either the posterior approach or antero-lateral approach. The posterior approach was preferred in fractures of upper-middle and middle quarters of shaft humerus where it was possible to identify and secure the radial nerve before fixation. The antero-lateral approach was preferred for fractures in the distal quarter. The fracture was fixed with a 4.5mm Locking Compression Plate. A minimum of 6 cortices were purchased on either side of the fracture with 4.5 mm cortical screws or 4.5 mm locking cortical screws.

The patients in the nailing group were operated with antero-grad nailing using a humerus

intramedullary nail. After taking an appropriate incision and entering the bone with an awl, serial medullary reaming was done and the nail with largest possible diameter was inserted over a guide wire. Before inserting the proximal locking bolts, the soft tissues were meticulously dissected and any overlying neurovascular bundles were retracted. The nail was then locked proximally and distally with cortical bolts under fluoroscopic guidance.

Postoperative radiographs were taken to confirm adequate reduction. The patients were given injectable antibiotics and analgesics for 3 days and then switched onto oral medication. The patients were kept in an arm sling following surgery and encouraged to perform pendulum exercises and passive followed by active range of movements of the elbow from the 1st post-operative day. The patients were discharged on 4th to 7th postop day once they were pain free and adequately mobilized.

The patients were followed up in the outpatient department at 2 weeks, 1 month, 3 months, 5 months, 10 month and at 1 year. The patients were examined clinically at each visit to look for signs of surgical wound infection, range of movements at elbow and shoulder and any other complications. At every visit a plain radiograph was taken and signs of hardware failure, screw back out and signs of union were looked for. The fracture was said to have united if bridging callus was visible on at least 2 orthogonal view radiographs. The normal union time was taken as 4 months, delayed union as that occurring between 4 to 6 months and non-union as no signs of fracture union beyond 6 months. The functional status of each patient was assessed at the end of 1 year using the ASES score (American Shoulder and Elbow Surgeons score). This scoring gives a maximum of 4 points to 13 different activities of daily living that are required by patients. The maximum score given is 52. Functional results were also graded by the criteria of Rommens et al.⁽⁵⁾ Shoulder and elbow functions were graded excellent, moderate or poor depending upon the loss of range of motion in any direction, subjective complaints like pain was also taken into account.

Table 1

Grade	Range of motion (ROM) (Shoulder/elbow)	Subjective Complaints
Excellent	<10° loss of ROM in any direction	None
Moderate	Loss of ROM between 10° to 30° in any direction	Mild
Poor	Loss of ROM >30° in any direction	Moderate to Sever

The results were tabulated and finally a comparative analysis was done between patients belonging to the two groups.

Results

In our study, 30 patients underwent internal fixation with interlocking nails, and 30 with locking compression plates.

The baseline demographics were as follows:

Table 2

Characteristics	Nailing group	Plating group
Males : Females ratio	17 : 13	14 : 16
Average age (range)	45.3 (18 – 76)	49.5 (20 – 71)
Mode of injury:		
RTA	40% (12)	53.3% (16)
Fall from height	33.3% (10)	16.6% (5)
Trivial trauma	10% (3)	16.6% (5)
Others	16.6% (5)	13.3% (4)
Pre-existing comorbidities:		
Diabetes Mellitus	13.3% (4)	23.3% (7)
Cardiac diseases	6.6% (2)	6.6% (2)
Respiratory diseases	10% (3)	6.6% (2)
Fracture classification:		
AO type A	63.3% (19)	56.6% (17)
AO type B	23.3% (7)	33.3% (10)
AO type C	13.3% (4)	10% (3)

No statistically significant difference was noted between the two groups when the baseline demographics were compared making the two groups comparable.

The perioperative parameters were compared and the results tabulated.

Table 3

Characteristics	Nailing group	Plating group
Average delay between admission and surgery	6.4 days	7.5 days
Average Duration of surgery (SD)	43.6 mins (12.33)	68.2 mins (15.78)
Average blood loss (SD)	121.5 ml (16.44)	336.4 ml (14.96)
Average Post-operative analgesics requirement (SD)	3.9 days (1.4)	4.4 days (2.2)
Average duration of hospital stay after surgery (SD)	6.3 days (2.02)	12.2 days (2.45)
Surgical wound infection	2 patients	4 patients

A statistically significant difference was noted in the average duration of surgery, average blood loss and average duration of hospital stay after surgery (p<0.05) between the two groups, all in favour of the nailing group.

The nailing group had 2 and plating group had 4 patients with surgical wound superficial infection, which were all treated by appropriate antibiotics and

debridement. No deep infections or osteomyelitis cases were reported in either group.

The functional and radiological outcome and complications that were recorded at each follow up were tabulated and compared.

Table 4

Parameter	Nailing group	Plating group
Radiological outcome:		
1. Union	26	27
2. Delayed union	2	2
3. Non-union	2	1
Average duration for normal radiological union (SD)	14.6 weeks (2.33)	15.7 weeks (3.88)
Functional outcome:		
1. Average ASES score at 1 year	46.8	50.4
2. Shoulder stiffness	9 (23.30%)	2 (6.6%)
3. Elbow stiffness	2 (6.6%)	1 (3.3%)
4. Rommens scoring:		
(a) Poor	5	3
(b) Moderate	2	3
(c) Excellent	23	24
Complications:		
1. Radial nerve palsy	4	2
2. Superficial infections	2	3
3. Deep infections	0	0
4. Delayed union	2	2
5. Non-union	2	1
6. Implant failure	2	1

Most patients in both the groups had union on x-rays before the 16th week of follow up after surgery. 2 cases of delayed union were seen in both the groups that eventually went on to unite. 2 cases of non-union in the nailing group were treated with nail removal and internal fixation with compression plates with autogenous bone graft. The 1 case of non-union in the plating group was treated with autogenous bone grafting. All these cases ended up with union of the fracture.

The average ASES scores were comparable in both the groups at the end of 1 year following surgery although the nailing group showed an increased incidence of shoulder stiffness which was statistically significant ($p < 0.05$). The Rommens scores at 1 year follow up showed an excellent result in both the groups in a majority of the patients, 76% in nailing group and 80% in plating group.

The most common complication observed in the nailing group was shoulder stiffness, which was treated with physiotherapy and gradual range of movements exercises. All patients recovered and had a good functional range of movements at shoulder at the end of 1 year following surgery.

We recorded 6 cases of post-operative radial nerve palsy which were all neuropraxias. 4 were seen in the nailing group and were attributed to manipulation of fracture during surgery. 2 cases were seen in the plating group and were attributed to irritation by hardware. All the patients recovered completely within 3 months with splinting and physiotherapy.

No cases of axillary nerve injury were recorded in either group in our study.

The nailing group had an overall increased complication rate as compared to the plating group, though not statistically significant.

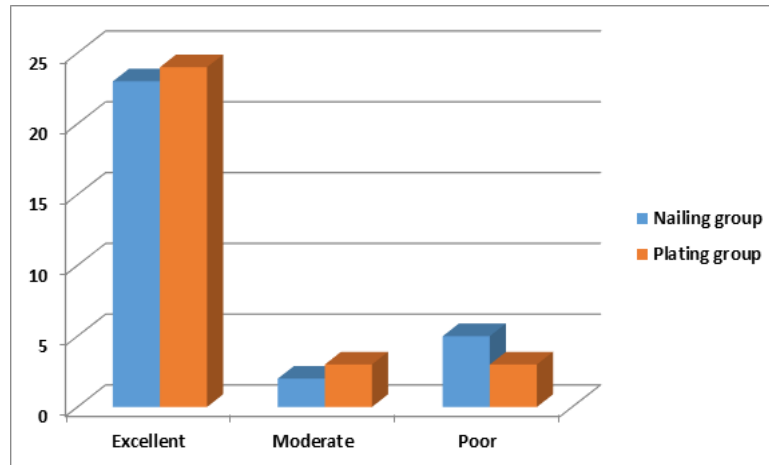
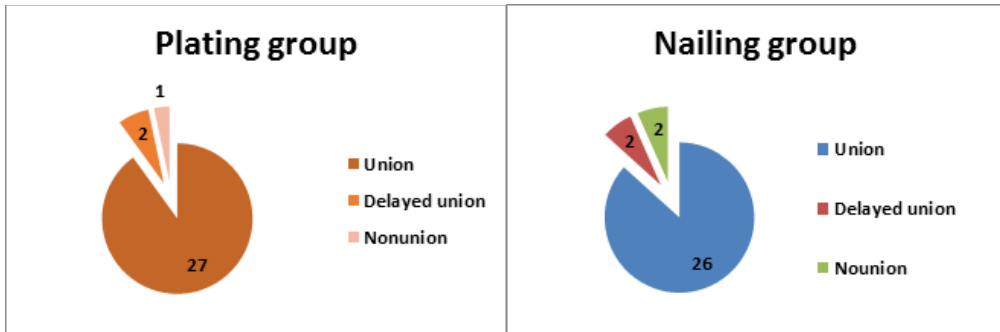


Fig. 1: Rommens Scoring

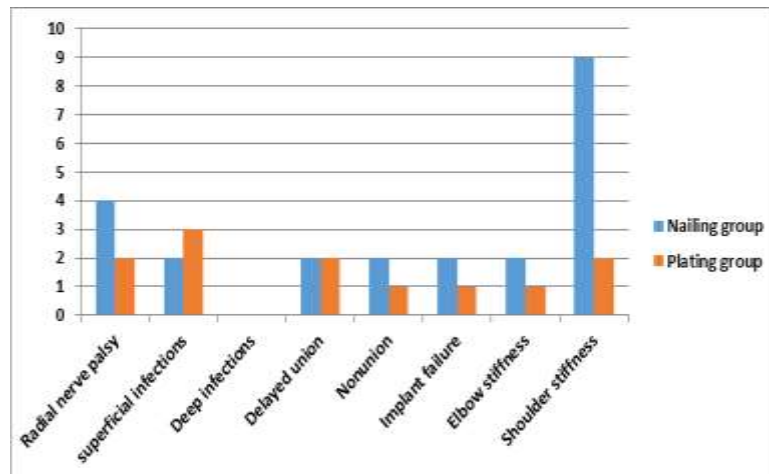


Fig. 2: Complications

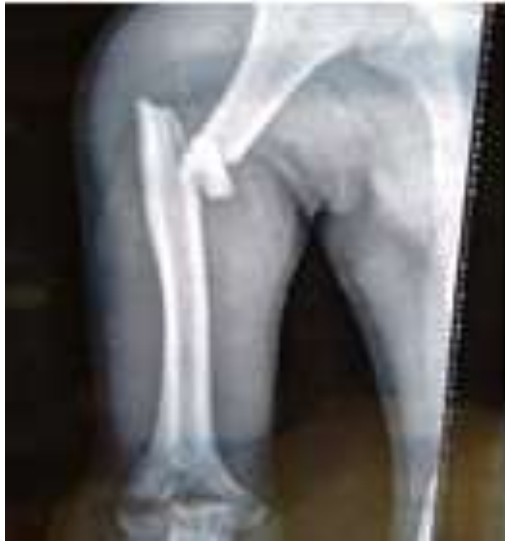

Fig. 3: Fracture shaft of right humerus of a 27 year old male

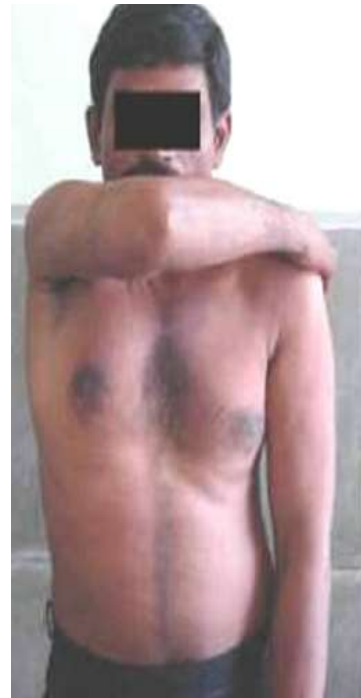

Fig. 3: Forward flexion

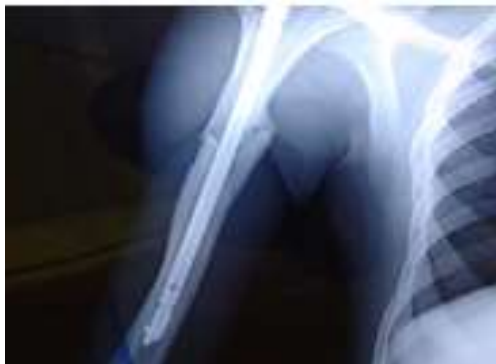

Fig. 4: 10 weeks post-surgery of the patient treated with CRIF with IL nail showing signs of union

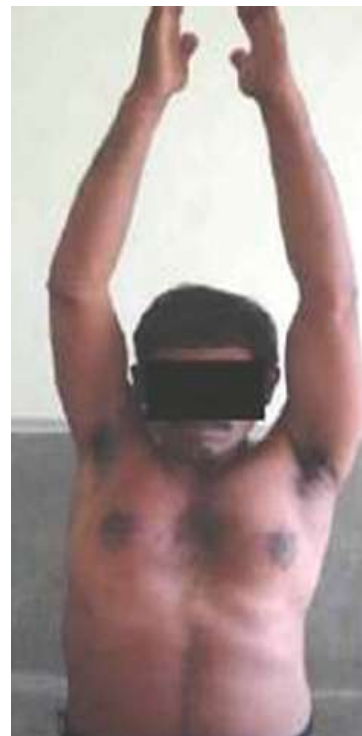

Fig. 4: Abduction

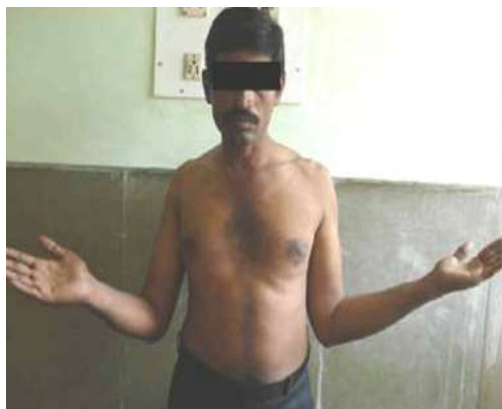

Fig. 5: External Rotation

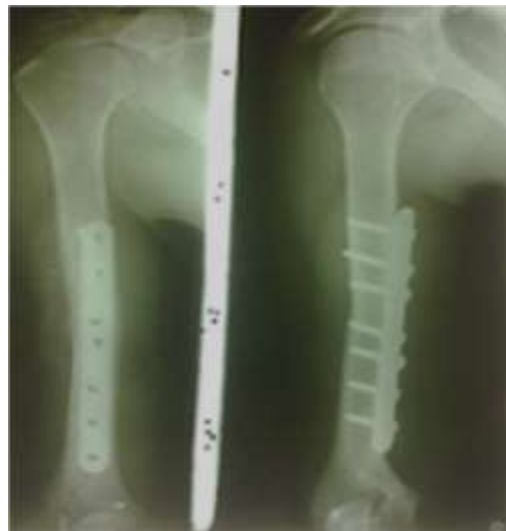

Fig. 8: Follow up x-ray after 1 year showing complete union

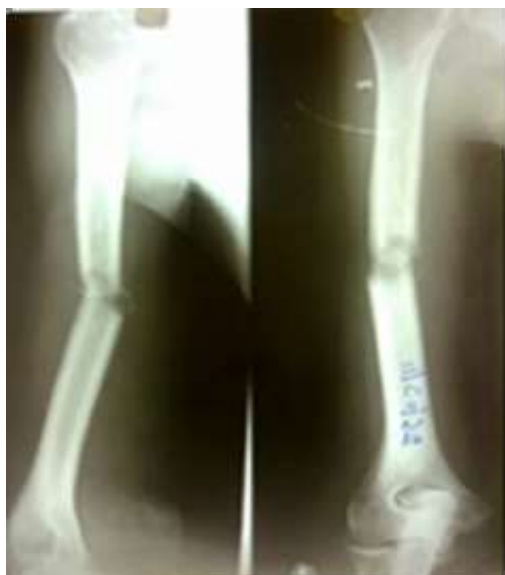

Fig. 6: Fracture shaft right humerus of a 43 year old male following RTA

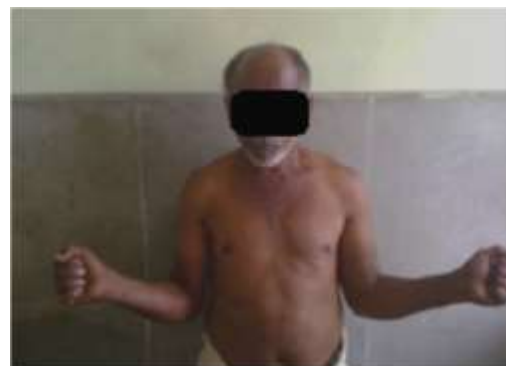

Fig. 9: External rotation

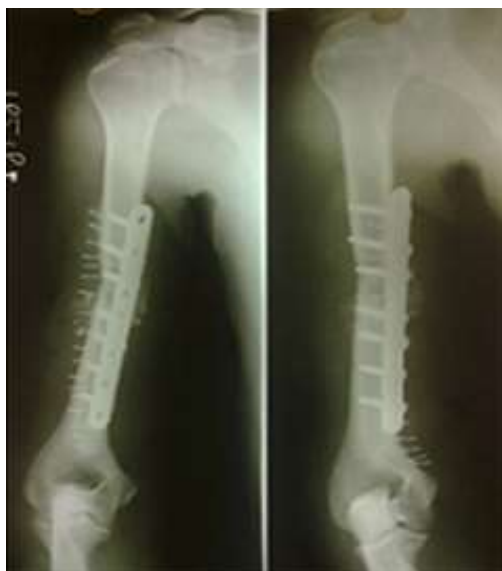

Fig. 7: Post-operative x-ray showing satisfactory reduction

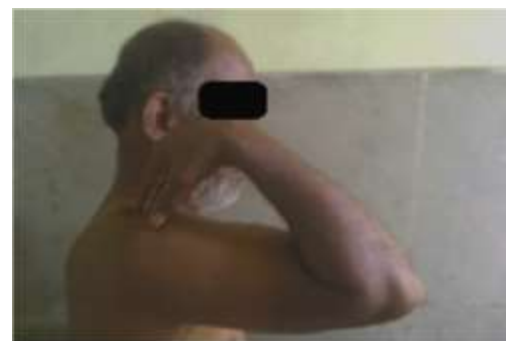

Fig. 10: Flexion

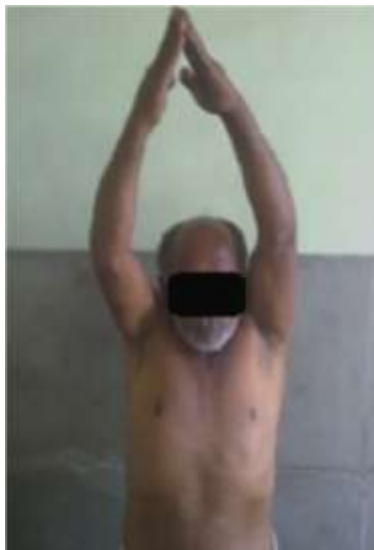

Fig. 11: Abduction

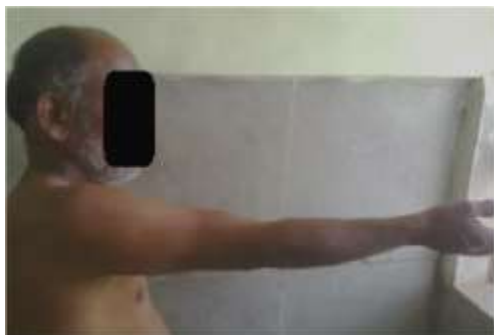

Fig. 12: Extension

Discussion

An acceptable functional result can be achieved in shaft humerus fractures even if 3cm of shortening, 30 degrees of rotation and 20 degrees of angulation exists after fracture union, making many of these fractures amenable to conservative treatment.⁽⁶⁾ Despite this, an increasing trend towards operative management is being seen nowadays to allow patients an early return to their daily activities and occupation. Open reduction with plating has been the gold standard of operative treatment for shaft humerus fractures, but the blood loss and risk of damaging radial nerve during surgery stimulated many to look for an alternative mode of treatment. CRIF with Intramedullary nails was known to be less invasive and had a lower incidence of intraoperative radial nerve damage. Thus it has arisen as a viable option for treating humerus shaft fractures. An extensive meta-analysis was done to compare the results of intramedullary nailing and plating techniques in the treatment of these fractures by Ouyang et al.⁽⁷⁾ They concluded that no significant difference exists between the two techniques except for an increased incidence of shoulder related complications in the nailing group. Ma et.al. also performed a meta-analysis

to compare these two implants in treating shaft humerus fractures and found that nailing had an increased incidence of shoulder related complications, fracture comminution during surgery, higher rate of implant failure and resurgery, with no significant difference seen in time to union or radial nerve injuries.⁽⁸⁾ Similar results were also reflected in our study, where we recorded no significant difference in radiological outcome and time to union between the two groups. We observed that the functional outcome was also similar except for a statistically significant increase in the incidence of shoulder stiffness following surgery in the nailing group. A higher rate of implant failure was also noted in the nailing group.

Conclusion

Based on our operative results and follow up of cases, we concluded that ORIF with locking compression plates had an overall better result, lesser complications and was a better suited implant to treat shaft humerus fractures, despite having a significantly higher intra-op blood loss and duration of surgery and a higher incidence of wound infections. CRIF with intramedullary nailing reported an overall higher incidence of complications, implant failure and shoulder stiffness which makes it less preferable an option as compared to plating.

References

1. Brinker MR, O'Connor DP. The incidence of fractures and dislocations referred for orthopaedic services in a capitulated population. *J Bone Joint Surg Am*. 2004;86:290-297.
2. Sarmiento A, Kinman PB, Galvin EG, Schmitt RH, Phillips JG (1977) Functional bracing of fractures of the shaft of the humerus. *J Bone Joint Surg Am* 59:596-601.
3. Schemitsch EH, Bhandari M. Fractures of the diaphyseal humerus. In: Browner BD, Jupiter JB, Levine AM, Trafton PG, editors. *Skeletal trauma*. 3. Toronto: WB Saunders; 2001. pp. 1481-1511.
4. Rommens PM, Kuechle R, Bord T, Lewens T, Engelmann R, et al. (2008) Humeral nailing revisited. *Injury* 39: 1319-1328.
5. Chapman JR, Henley MB, Agel J, Benca PT. Randomised prospective study of humeral shaft fractures fixation; intramedullary nails versus plates. *J Orthop Trauma* 2000;149(3):162-166.
6. Pappasoulis E, Drosos GI, Ververidis AN, et al. Functional bracing of humeral shaft fractures. A review of clinical studies. *Injury*. 2010;41:e21-e27. doi: 10.1016/j.injury.2009.05.004.
7. Ouyang H, Xiong J, Xiang P, Cui Z, Chen L, Yu B. Plate versus intramedullary nail fixation in the treatment of humeral shaft fractures: an updated meta-analysis. *J Shoulder Elbow Surg*. 2013;22:387-395. doi: 10.1016/j.jse.2012.06.007.
8. Ma J, Xing D, Ma X, et al. Intramedullary nail versus dynamic compression plate fixation in treating humeral shaft fractures: grading the evidence through a meta-analysis. *PLoS One* 2013;8:e82075.