

## Prospective study of distal tibia fracture with anterolateral plating by MIPPO technique

Kosalaraman Padmanaban<sup>1,\*</sup>, Major Kamalanathan<sup>2</sup>, Balamurugan Palaniswamy<sup>3</sup>, Vivekanandan Ramasamy<sup>4</sup>, Ajay Paul Cyriac<sup>5</sup>

<sup>1</sup>Associate Professor, <sup>2</sup>Professor, <sup>3,4</sup>Assistant Professor, <sup>5</sup>Junior Resident, Dept. of Orthopaedics, Coimbatore Medical College and Hospital, Coimbatore, Tamil Nadu

**\*Corresponding Author:**

Email: pkrvidya.2002@gmail.com

### Abstract

**Background:** The management of distal Tibia fractures has been a great challenge to orthopaedic surgeons due to soft tissue damage, extensive comminution, intra-articular extension and lack of vascularity.

**Materials and Methods:** Twenty five adult patients treated by anterolateral 3.5mm distal Tibial LCP by MIPPO technique between December 2014 and July 2016 were included in the study. The radiological outcome was assessed by Tenny and Wiss score and the functional outcome by AOFAS scale.

**Results:** Of the 25 patients in the study, 18 were males and 7 were females. The mean age was 49.32 years (range: 21-75 years). The majority of cases were AO type 43A3 (36%). Complete fracture union was achieved by 21 weeks (14-30 weeks). At final follow up 18 fractures united with no angulation at fracture site while 1 united in valgus (<10°) and 1 varus (<5°) and 3 in sagittal angulation (<10° angulation in both) which were consistent with acceptable limits. The mean AOFAS score was 79.16 after 8 months, with 4 cases having excellent outcome, 14 good, 3 acceptable and 4 cases with bad outcome. The complications in this study were angular deformity 5(20%), Infection 4 (16%), non-union 2 (8%), implant breakage 1 (4%).

**Conclusion:** Anterolateral distal Tibial plating by MIPPO technique gives good functional and radiological outcome with advantage of minimal soft tissue dissection without stripping the periosteum and preventing subsequent devascularisation of fracture fragments but it requires a long learning curve. Thus we conclude that anterolateral distal Tibial locking plate is a good option for managing the distal Tibial fractures.

**Keywords:** Distal Tibia fracture, Anterolateral Plating, Functional Outcome, MIPPO technique.

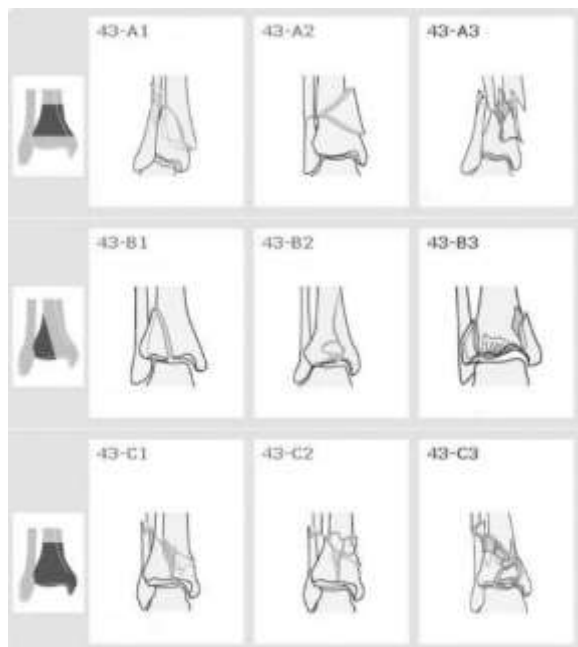
### Introduction

Tibial Pilon (Tibial Plafond) is a descriptive term where talus acts as a hammer, impacting and fracturing the distal Tibia.<sup>(1)</sup> Tibial pilon fractures account for 1% to 10% of all lower extremity injuries.<sup>(2)</sup> Treatments of these fractures remain challenging<sup>(2)</sup> due to the precarious vasculature around the ankle. Subcutaneous location of the Tibia adds to wound complications. Low energy fractures occur in older age group due to rotation injury resulting in extra articular fracture without much soft tissue injury with fewer incidences of wound complications and infection.<sup>(3)</sup> High energy fractures occur in younger age group due to axial loading resulting in comminuted intra articular fractures with severe soft tissue injury, edema and skin blisters around the ankle, which makes the decision regarding line of management difficult. Internal fixation was considered gold standard in 1980s by Ruedi of the AO group. The enthusiasm was soon lost due to wound breakdown, sepsis, with resultant osteomyelitis. External fixation like conventional ankle spanning external fixator, hybrid fixator emerged as a successful technique to avoid the above complications. Open reduction and internal fixation has recently gained popularity due to better assessment of soft tissue envelope and development of Locking Compression Plate. Medial plating using LCP resulted in significant rate of wound dehiscence and deep infection. Recently

anterolateral LCP fixation by MIPPO technique has gained popularity due to its potential advantages compared to medial approach.

### Materials & Methods

This Prospective study was conducted from December 2014 to July 2016 at Department of Orthopaedics, Coimbatore Medical college Hospital. There were totally 25 patients of which 18 were males and 7 were females. All the patients were selected based on strict inclusion and exclusion criteria. Inclusion criteria were skeletally mature patients, AO type 43 A, B and C fractures, closed fractures, grade one and two open fractures. Exclusion criteria were grade III C compound fractures with bone loss, associated tarsal fractures, associated spinal and abdominal injuries, pathological fractures, bedridden patients, patients with neurological disorder, psychiatric and pregnant patients. The fracture distribution is illustrated in Table 1.



**Fig. 1: AO Classification of distal Tibia fractures**

**Table 1: Fracture distribution in the study**

Sex	M	18	25
	F	7	
Side	R	11	25
	L	14	
Mode of injury	Slip and fall	7	25
	RTA	15	
	Fall from height	3	
Fracture Type	Closed	17	25
	Grade 1	4	
	Grade 2	4	
Age distribution	18-30	1	25
	31-40	6	
	41-50	4	
	51-60	11	
	61-70	2	
	>70	1	
AO classification	A1	7	25
	A2	1	
	A3	9	
	C1	3	
	C2	4	
	C3	1	
Total no of patients	25		

**Pre-operative Assessment:** Detailed clinical and radiological examination was carried out in all patients in orthopaedic emergency-Trauma Ward/ OPD. Ankle Mortise views were taken if malleolar fractures or ankle joint injuries were suspected. A 3D CT scan may be required to assess any intra-articular fractures. Most of

the patients were immobilized with above knee slab and some were given calcaneal pin traction if severe swelling and blisters were present as well as for compound fractures till wound has healed. Patients were taken up for surgery after the initial swelling and blisters has resolved and after the appearance of wrinkle sign. The average period from time of admission to surgery was 12 days.

**Features of anterolateral LCP:** The 3.5mm anterolateral distal Tibial plate is a LCP system made of stainless steel with limited-contact shaft profile. The combi-holes in the LCP shaft combine a dynamic compression unit (DCU) hole with a locking screw hole. Locking screws provide the ability to create a fixed-angle construct especially in osteopenic bone and multi-fragmentary fractures where screw purchase is compromised. Features of this include anatomically shaped, 3.6mm shaft thickness which tapers to 2.0mm distally, 60° twist in shaft is contoured for the distal Tibial anatomy, tapered tip for sub muscular insertion. Distal locking screws provide support for the articular surface, targeted locking for Volkmann's triangle and Chaput fragment.



**Fig. 2: Anterolateral distal Tibia LCP**

**Surgical Technique:** In all cases, fibula is fixed first in order to maintain the length of the affected limb and also to achieve indirect reduction of fracture by using 1/3<sup>rd</sup> tubular plate through postero-lateral approach. It is also fixed using 2-3 mm K-wires in patients where the skin condition over the lateral malleolus was compromised. In MIPPO technique, the skin incision of 3-4 cm is made at the ankle joint, along the fourth metatarsal distally and runs between the Tibia and fibula proximally. Full-thickness skin flaps should be raised and the superficial peroneal nerve beneath the skin must be protected and retracted. Next the extensor retinaculum is incised and the anterior compartment tendons are retracted medially. Minimum gap between fibular and distal Tibial incision should be above 5 cm to facilitate skin closure without any compromise. Reduction and articular congruity is verified under Carm after provisional fixation with k wires. LCP with

minimum of 5-6 holes above the fracture site was selected. A submuscular plane is made using the Cobbs elevator and a pre-contoured plate was slid beneath the anterior compartment muscles and the neurovascular bundle. The proximal most hole of the plate was identified by C arm and was provisionally fixed by k wire. To achieve proper seating 3.5 mm cortical screws are applied in most cases. Later 3.5mm locking screws were applied in the sequential manner first in the distal horizontal holes and then proximal holes in alternate manner with least three screws in the diaphyseal segment. In some cases 3.5 mm cortical screws were used to achieve inter-fragmentary compression. Wound closed in layers after haemostasis over a suction drain.

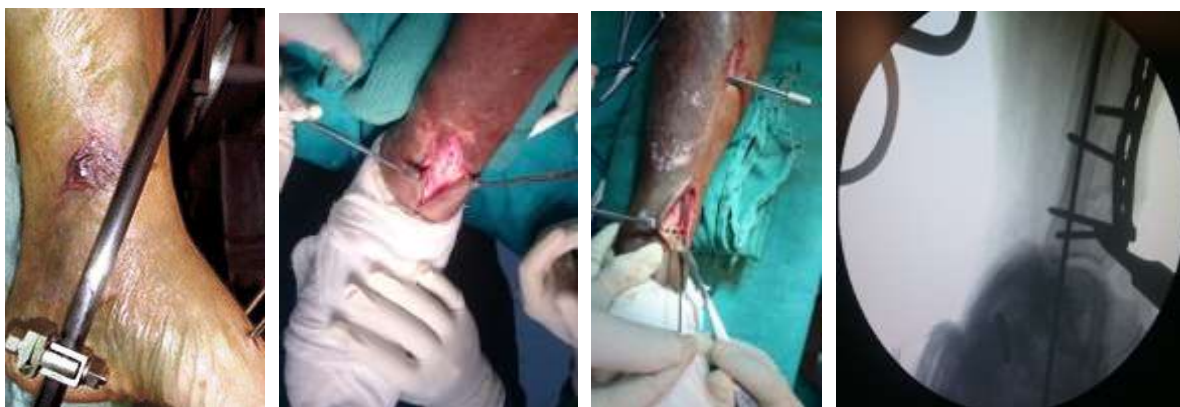

Fig. 3: Wrinkle sign, skin incision, plate introduction and intra-operative c arm image

#### Assessment of Functional and Radiological Outcome:

The American Orthopaedic Foot & Ankle Society (AOFAS) scale was used in our study to assess the functional outcome. This scale consists of subjective and objective variables classified into three major categories: pain (40 points), function (50 points), and alignment (10 points).

#### Total Score Functional Outcome

Above 89 points Excellent

From 80 to 89 points Good

From 70 to 79 points Acceptable

Less than 69 points Bad

Radiologically acceptable outcomes includes the fracture union with  $<5^\circ$  of angulation in both sagittal and coronal plane, 1cm shortening, with articular step less than 2mm. We have used the Tenny and Wiss<sup>(4)</sup> score to assess quality of post-operative reduction.

Table 2: Tenny and wiss radiological score

Anatomical site	Score		
Quality of reduction	1	2	3
Lateral malleolus displacement	0-1 mm	2-5 mm	5 mm
Medial malleolus displacement	0-1 mm	2-5 mm	5 mm
Posterior malleolus displacement	0-0.5 mm	0.5-2 mm	2 mm
Mortise widening	0-0.5 mm	0.5-2 mm	2 mm
Fibular widening	0-0.5 mm	0.5-2 mm	2 mm
Talar tilt	0-0.5 mm	0.5-2 mm	2 mm
Articular gap	0-0.5 mm	2-4 mm	4 mm
Final Score	Radiologic Outcome		
9	Anatomic		
10-12	Good		
13-16	Fair		
>16	Poor		

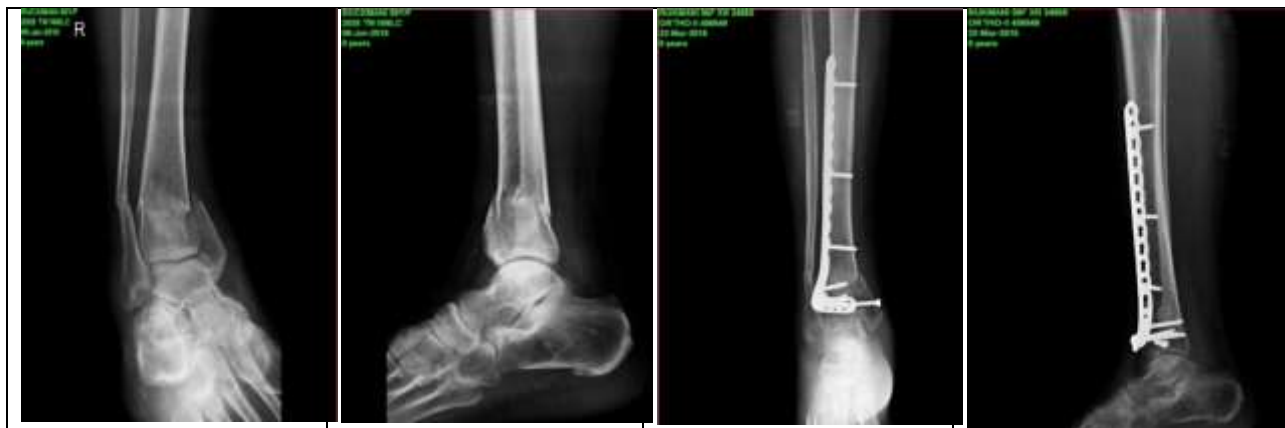

Fig. 4: Pre op X-ray AO 43 C1 Post op X-ray

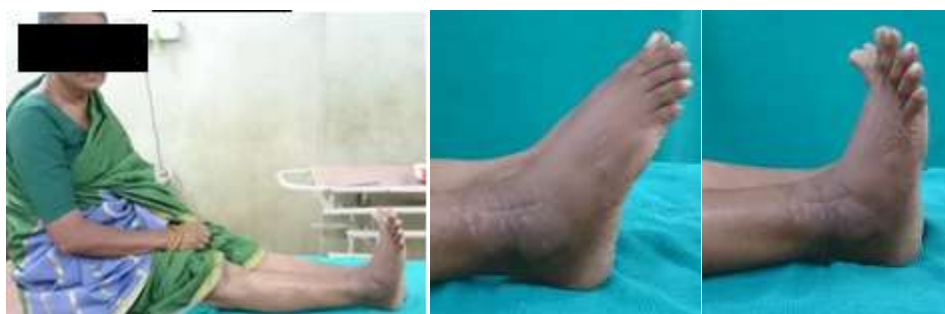

Fig. 5: Clinical picture with functional outcome

### Discussion

Distal dia-metaphyseal Tibial fractures are one of the most problematic injuries to manage. Conservative management should be reserved for undisplaced fractures and in those patients with absolute contraindications to surgery. Disadvantages of non-operative treatment include non-union, malunion, post traumatic stiffness of ankle due to prolonged immobilization with subsequent reflex sympathetic dystrophy. Surgical management includes plate and screw fixation - DCP/LCP by ORIF or MIPPO technique. Intramedullary nails like regular interlocking nails and specialized expert Tibial nail can be used. External fixation devices like ring fixators, ankle sparing/spanning, delta frame fixators and hybrid fixator or combinations of the above are used. The advantages of MIPPO are biological reduction, reduced duration of surgery, lesser tourniquet time and smaller incision.

Results of operative treatment depend on the severity of the initial injury, the quality of bone and soft tissue, stability of the reduction, the degree of comminution and articular incongruity.

The mean age of the patients in our study was 45.44 years and the most common mechanism of injury was road traffic accidents. The mean duration from the time of trauma to surgery was 12 days and in another study by Collinge C, et al<sup>(5)</sup> the same interval was 7 days. Most cases were managed by definitive anterolateral plating as single stage surgery. In those

cases with grade I and grade II compound fractures initial calcaneal pin traction and in two cases delta frame external fixator for soft tissue healing were applied. Later all patients were taken up for definitive fixation by MIPPO technique. Of the 25 cases 5 cases had fibula fracture at the supra syndesmotom level for which internal fixation of fibula was not done, 8 cases with grade I and grade II compound fracture were fixed with k wire and remaining 12 cases with fracture at trans-syndesmotom and infra-syndesmotom level was fixed using 1/3<sup>rd</sup> tubular plate. We achieved post-operative anatomical alignment in 20 of the 25 cases (80%) with less than 5 degrees of angulation in coronal and sagittal plane and 1 cm of shortening. Mean duration of surgery was 80 min and average intra operative blood loss was 200ml.

### Follow up and Results

All the cases were followed up at 6 weeks, 10 weeks, 20 weeks upto a minimum period of 8 months and were assessed for fracture union, alignment, implant failure and articular congruity. Weight bearing in our study was started at around 14 weeks (10-26 weeks). Complete fracture union was achieved by 21 weeks (14-30 weeks). At final follow up 18 fractures united with no angulation at fracture site while one united in mild valgus and one in varus and three in sagittal angulation (<10° angulation in both) with less than 1 cm shortening of affected limb. The final range of average dorsiflexion in our study was 15 degrees and plantar flexion of 25 degrees. The mean AOFAS score

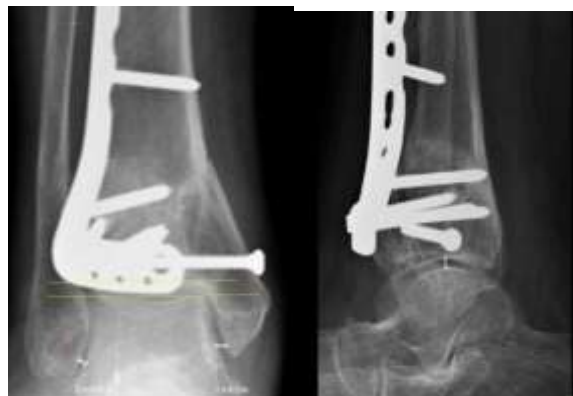was 79.16. Final functional and radiological outcome is shown in Table 3.

**Table 3: Functional And radiological outcome**

<b>AOFAS Scale (Functional Outcome)</b>	<b>Outcome</b>	<b>No of cases</b>
>89	Excellent	4
80-89	Good	14
70-79	Acceptable	3
<69	Bad	4
<b>Teeny and Wiss score (Radiological outcome)</b>	<b>Outcome</b>	<b>No. of cases</b>
9	Anatomic	5
10-12	Good	13
13-16	Fair	3
> 16	Poor	4

The decision regarding postoperative weight bearing was made based on clinical and radiological evaluation. Guo J, et al<sup>(6)</sup> in their study allowed partial weight bearing once radiological signs of union were present usually by 6-8 weeks. Nork S, et al<sup>(7)</sup> and Oh W, et al<sup>(8)</sup> in their study followed protocol of splinting the limb for 48-72 hours and strict non weight bearing till clinical and radiological signs of union are evident but those who were unable to follow the non-weight bearing instructions were immobilised in cast for 6-8 weeks and then depending on signs of union decision on weight bearing made. In our study, we allowed weight bearing only after signs of union usually by 12-16 weeks.

The normal post-operative alignment achieved during this study was comparable to the existing studies on intramedullary nail fixation alone, i.e., Nork et al and Ehlinger et al,<sup>(9)</sup> as well as the comparative study on LCP and intramedullary nailing by Yang et al<sup>10</sup> and Mauffery et al.<sup>(11)</sup>



**Fig. 6: Post op X ray showing Radiological alignment**

**AP view:** 1-Medial clear space; 2- Lateral clear space; 3- Talar tilt **Lateral view:** 1-Articular gap

**Time for Fracture Union:** The mean time of union in our study was 21.4 weeks and 13 fractures (73%) united between 12-20 weeks, another 4 fractures between 20-24 weeks and all the rest within 30 weeks. Two cases had gone for non-union. The comparison of time of fracture union and AOFAS score among various studies was given as in Table 4.

**Table 4: Comparison of fracture union time and AOFAS score in various studies**

<b>Study group</b>	<b>Time for fracture union (weeks)</b>
Ronga et al <sup>(12)</sup>	18 union in 22.3 weeks
Nork et al	23.5
Lau et al <sup>(13)</sup>	18.4 19.4 in infection cases
Krzysztof Piątkowski et al <sup>(14)</sup>	19
Collinge et al.	26 union in 35 weeks
<b>Our study</b>	<b>21.43</b>
<b>Study group</b>	<b>AOFAS score</b>
Guo et al	83.9
Collinge et al	85
Gülabi et al. <sup>(15)</sup>	78.33
<b>Our study</b>	<b>79.16</b>

**Complications:** The complications encountered in other studies in comparison with our study is given in Table 5.

**Table 5: Comparison of complication of various studies**

<b>Study group</b>	<b>Infections</b>	<b>Implant breakage</b>	<b>Varus angulation</b>	<b>Valgus angulation</b>	<b>Sagittal angulation</b>	<b>Non union</b>
Ajeet Dhakar et al., <sup>(16)</sup>	8%	8%	4%			
Gülabi et al.	9.1%	-	-			
Lau et al	17%	4%				
Ronga et al.	14.7%		14.3%	4.7%	9.5%	4.7%
Our study	16%	4%	4%	4%	12%	8%

Out of four cases of infection three were superficial which settled with antibiotics and the case with deep infection was treated with implant removal and fracture was managed conservatively which united by 26wks. In our study 3 cases (12%) had antero-posterior angulation < 8 degree with convexity posteriorly, one case of varus angulation (4%) due to premature weight

bearing and a case of implant breakage (4%) due to improper fixation and early weight bearing. After 4 months fracture had united with AOFAS score of 80.

The comparison of results of different methods of surgical management including the average duration of fracture union, complications and final AOFAS score is shown as in Table 6.

**Table 6: Comparison of overall results of various studies**

Name of the study	No of patients	Average age of patient (in yrs.)	Average time to union	Post-operative Infection (%)	Malalignment (%)	Delayed/ Non-unions (%)	Mean AOFAS score at union (Max 100)
Borg et al <sup>(17)</sup>	21	-	5.44m	14.3	28.5	19	-
Bahari et al <sup>(18)</sup>	42	35	22.4wks	7.14	-	-	-
Mafulli et al <sup>(19)</sup>	20	-	-	0	36.8	5.3	-
Redfern et al <sup>(20)</sup>	20	38.3	23wks	5	5	0	-
Hasenboehler et al <sup>(21)</sup>	32	45	75% 6m, 84% 9m	3.4	0	17.2	-
aWilliams et al <sup>(22)</sup>	20	-	-	10.5	-	31.5	-
Lau et al	48	-	18.7	16.7	-	10.4	-
Gupta et al <sup>(23)</sup>	71	-	-	3.8	2.5	12.7	-
Ronga et al	21	-	-	42.3	19	4.8	-
Sitnik et al <sup>(24)</sup>	80	43	87.5% by 6m	9	6	13	-
Hazarika et al <sup>(25)</sup>	20	44.7	58.3% at 6m	5	-	10	-
J JGuo et al <sup>(26)</sup>	54	-	17.6wks	14.6	-	-	83.9
Collinge et al	38	-	21wks	all infection superficial	2.63	2	85
Gülabi et al.	60						78.33
Current study	25	49.32	21.43	16%	20%	4%	79.16

## Conclusion

Anterolateral distal Tibial LCP plating by MIPPO technique has advantage of not stripping the periosteum with retention of fracture hematoma and preventing subsequent revascularization of fracture fragments. The surgical techniques to achieve good anatomical reduction, sliding of the plate sub-periosteally without opening the fracture site and subsequent application of locking screws subcutaneously using the sleeve require a long learning curve. The added advantages of this anterolateral plating are that it has minimal soft tissue complication unlike antero-medial plating. Thus we conclude that anterolateral distal Tibial locking plate is a good option for managing the distal Tibial fractures.

## References

1. Rockwood and Green's, "Fracture in adults" 7th edition, chapter 56, 1928-29.
2. Campbell's Operative Orthopaedics, Twelfth Edition, S. Terry Canale, MD, Harold B. Boyd Professor and Chair, Department of Orthopaedics Surgery, University of Tennessee- Campbell Clinic Memphis, Tennessee, James H. Beaty, MD, Professor, Department of Orthopaedic Surgery, University of Tennessee- Campbell Clinic, Chief of Staff, Campbell Clinic Memphis, Tennessee.
3. Schatzker J, Tile M, The rationale of operative fracture care, 3rd edition: p 475-76.
4. Deniz GÜLABI,1 Özgür TOPRAK,1 Cengiz ŞEN,2 Cem Coşkun AVCI,1 Erkal BİLEN,3 Fevzi SAĞLAM1 The mid-term results of treatment for Tibialpilon fractures, Turkish Journal of Trauma & Emergency Surgery: Ulus Travma Acil Cerrahi Derg 2012;18(5):429-435.
5. Collinge C, Kuper M, Larson K, Protzman R "Minimally



- Invasive Plating of High-Energy Metaphyseal Distal Tibia Fractures". *J Orthop Trauma*; 21(6):355-360.
6. Guo J, Tang N, Yang H, Tang T. "A prospective, randomised trial comparing closed intramedullary nailing with percutaneous plating in the treatment of distal metaphyseal fractures of the Tibia". *J Bone Joint Surg Brit* 2010;92-B (7):984-988.
  7. Nork S, Schwartz A, Agel J, Holt S, Schrick J, Winquist R "Intramedullary nailing of distal metaphyseal Tibial fractures". *J Bone Joint Surg Am*. 2005;87(6):1213-21.
  8. Oh CW, Kyung HS, Park IH, Kim PT, Ihn JC. Distal Tibia metaphyseal fractures treated by percutaneous plate osteosynthesis. *ClinOrthopRelat Res*. 2003;408:286-291. doi: 10.1097/00003086-200303000-00038.
  9. Ehlinger M, Adam P, Gabrion A, Jeunet L, Dujardin F, Asencio G; Sofcot. "Distal quarter leg fractures fixation: The intramedullary nailing alone option". *OrthopTraumatolSurg& Res*. 2010;96(6):674-82.
  10. Yang SW, Tzeng HM, Chou YJ, Teng HP, Liu HH, Wong CY. Treatment of distal Tibialmetaphyseal fractures: plating versus shortened intramedullary nailing. *Injury* 2006;37:531-5.
  11. Mauffrey C, McGuinness K, Parsons N, Achten J, Costa ML. A randomized pilot trial of locking plating fixation versus intramedullary nailing for extra-articular fractures of distal Tibia. *J Bone Joint Surg Br* 2012; 94: 704-8.
  12. Ronga M, Longo U, Maffulli N "Minimally Invasive Locked Plating of Distal Tibia Fractures is Safe and Effective". *ClinOrthopRelatRes*. 2010;468(4):975-982.
  13. Lau T, Leung F, Chan F, Chow S, "Wound complication of minimally invasive plate osteosynthesis in distal Tibia fractures". *IntOrthop*. 2008;32(5):697-703.
  14. Piątkowski, K., Piekarczyk, P., Kwiatkowski, K. et al. Comparison of different locking plate fixation methods in distal Tibia fracture *International Orthopaedics (SICOT)* (2015) 39:2245. doi:10.1007/s00264-015-2906-4.
  15. Deniz Gülabi, M.D.,1 Halil İbrahim Bekler, M.D.,1 Fevzi Sağlam, M.D.,1 Zeki Taşdemir, M.D.,1 Gültekin Sıtkı Çeçen, M.D.,1 Nurzat Elmalı, M.D.2; Surgical treatment of distal Tibia fractures: open versus MIPO ; *Ulus Travma Acil Cerrahi Derg*, January 2016, Vol. 22, No. 1.
  16. Ajeet Dhakar et al., Minimally Invasive Plate Osteosynthesis with Locking Plates for Distal Tibia Fractures *Journal of Clinical and Diagnostic Research*. 2016 Mar, Vol-10(3): RC01-RC04.
  17. Borg T, Larsson S, Lindsjo U. Percutaneous plating of distal Tibial fractures- preliminary results in 21 patients. *Injury*. 2004;35:608e614 Sarmiento A, Latta LL. 450 closed fractures of the distal third of the Tibia treated with a functional brace. *ClinOrthopRelat Res*. 2004;428:261-271.
  18. Bahari S, Lenehan B, Khan H, Mcelwain JP. Minimally invasive percutaneous plate fixation of distal Tibia fractures. *ActaOrthop Belg*. 2007;73:635e640.
  19. Maffulli N, Toms A, McMurtie A, et al (2004) Percutaneous plating of distal Tibial fractures. *International Orthopaedics*; 28159-162.
  20. Redfern DJ, Syed SU, Davies SJM. Fractures of the distal Tibia: minimal invasive plate osteosynthesis. *Injury*.2004;35:615e620.
  21. Hasenboehler E, Rikli D, Babst R. Locking compression plate with minimally invasive plate osteo-synthesis in diaphyseal and distal Tibial fracture: a retrospective study of 32 patients. *Injury*.2007;38:365 e 370.
  22. Williams T, Schenk W. Bridging- minimally invasive locking plate osteosynthesis (Bridging-MILPO): technique description with prospective series of 20 Tibial fractures. *Injury*. 2008;39:1198e1203.
  23. Gupta RK, Rohilla RK, Sangwan K, Singh V, Walia S. Locking plate fixation in distal metaphyseal Tibial fractures: series of 79 patients. *IntOrthop*. 2010;34:1285e1290 Guo J, Tang N, Yang H, Tang T. "A prospective, randomised trial comparing closed intramedullary nailing with percutaneous plating in the treatment of distal metaphyseal fractures of the Tibia". *J Bone Joint Surg Brit* 2010;92-B (7):984-988.
  24. Sitnik AA, Beletsky AV. Minimally invasive percutaneous plate fixation of Tibia fractures: results in 80 patients. *ClinOrthopRelatRes*. 2013;471:2783e2789.
  25. Hazarika S, Chakravarthy J, Cooper J. Minimally invasive locking plate osteosynthesis for fractures of the distal Tibia. Results in 20 patients. *Injury*. 2006;37:877e887.
  26. Guo JJ, Tang N, Yang HL, Tang TS. A prospective, randomised trial comparing closed intramedullary nailing with percutaneous plating in the treatment of distal metaphyseal fractures of the Tibia. *J Bone JtSurg Br*. 2010;92-B:984e988.