

Lower End radius fracture: a retrospective study of patients treated with external fixator, a minimal invasive method

Zulfikar M. Patel¹, Kaushal R. Patel^{2,*}, Sulay A. Sachdev³, Ranjan B. Patariya⁴, Bhavya B. Shah⁵

¹Associate Professor, ^{2,3,4,5}Resident, Dept. of Orthopaedics, Civil Hospital, Ahmedabad

*Corresponding Author:

Email: kaushal71190@gmail.com, sullusachdev@gmail.com

Abstract

Introduction: Fractures of lower end radius remains the most common fracture in emergency room and mostly treated with closed reduction followed by cast of paris of plaster or some surgical procedure in term of minimal invasive or invasive procedure. The minimal invasive procedure includes k wire followed by cast or external fixator.

Objective: To evaluate the effectiveness of external fixation in all types of distal end radius fractures.

Materials and Methods: This is the retrospective study of fractures of distal end of radius treated by external fixator in Civil Hospital, Ahmedabad from 2013 to 2015.

Results: This is a retrospective study of 200 consecutive unstable distal radius fractures.

- There were 66 females and 134 males.
- Fractures were classified according to AO classification.
- Complications included pin tract infection loss of reduction, reflex sympathetic dystrophy and tendon attrition.
- The patients were reviewed at a mean of 6 months after surgery for radiological and functional assessment.
- Average volar tilt on follow up was 9.6 degrees,
- Average radial length on follow up was 9.7 mm
- Average radial inclination on follow up was 20 degrees.
- Ao type C2 and C3 and osteoporotic bone shows loss of reduction.
- 150 patients had excellent or good anatomical results, according to Sarmiento criteria.
- 170 patients had excellent or good functional results. According to Gartland and Werley scoring system.

Conclusion: Thus close reduction followed by percutaneous pinning (k –wire) in term of external fixator is valuable technique for displaced and intra articular type of lower end radius fracture. The method is relatively simple, minimally invasive and reliable.

Keywords: lower end radius, External fixator, K (kirschner) wire, Minimal invasive.

Introduction

Fractures of distal End radius account for approximately 16% of all fractures that are seen and treated by orthopedic surgeons. These fractures are notorious to have varying degrees of comminution with volar or dorsal displacement; articular extension; depression or involvement of major fragment with or without involvement of radio carpal and radio ulnar joint. So far, conventional method of closed reduction and cast for this fracture has resulted in unsatisfactory anatomical and functional results. With varying degrees of deformity and disability. The more comminuted Intra articular fractures (AO-C2-C3) occurring in younger population treatment quite difficult and complication rate evidently high and no consensus. On treatment modality regaining pre-injury activity level is least for these lesions.

Increasing functional demand and improved methodologies of achieving and maintaining anatomical, reduction, restoration of length, angulation and congruity of joint have generated renewed interest in addressing the anecdotal comments in more precise way. External fixation is an outstanding technique because of ability to restore and maintain the radial length and also prevention of metaphysical collapse, can be done also in pilon (AO-c2-c3). Loss of reduction commonest

complication can be prevented with application of external fixation. It also has been shown to be effective in surgical management of unstable, intra articular fractures with minimal range of complication. Concern for best method of treatment has led a numbers of surgeons to use method other than conventional method to hold reduction, avoid unphysiological positions of immobilization. These have included external pin fixation other reduction and pin or plate fixation, perpinning, bone grafting, fragment specific fixation and arthroscopic fixation.

Our main aim is to do a prospective study of external fixation for all types of fractures of distal end of radius and review their outcome.

Materials and Methods

This is the retrospective study of 200 fractures of distal end of radius (196 patients) treated by external fixator.

Inclusion criteria-All fractures of distal end radius-AO classification except- A1

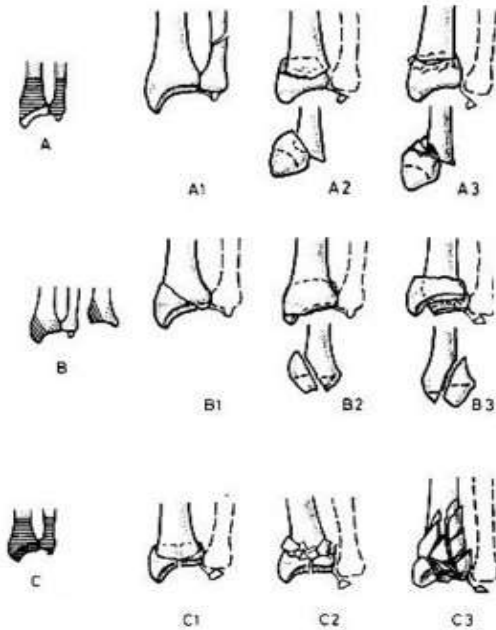


Fig. 1

All patients were treated by modular external fixator with additional fixation done with K wires in unstable fractures and bone graft in comminuted fractures by elevating intra articular depression and filling metaphyseal defects with bone graft. Volar BE slab given post-operatively.

All the patients were followed-up regularly upto 6 months post-operatively.

Observation and Analysis

Most common age group considered in this fractures series was 21-40 years among which 50% of the patient falling into this age group.

Mean age: 37.4 years

Range: 18-62 years

Table 1: Age distribution

Age Group(yrs.)	No. of Fractures	Percentage
Upto 20	22	11
21-40	100	50
41-60	68	34
Above 60	10	5
Total	200	100

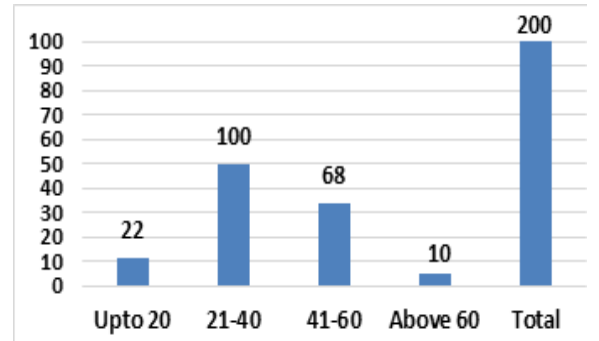


Fig. 2: Age Distribution

- Among 200 fractures in this study, 2/3 fractures were seen in males whereas 1/3 fractures were seen in females.
- Most common mode of injury in our study was RTA and domestic injury in form of fall on out stretched hand.

Table 2: Side involved

Side	Dominant	Non Dominant	Total No. of Fractures
Right	136	04	140
Left	4	56	60
Total	140	60	200

Table 3: Interval between injury and treatment

<6 hours	70%
6 to 24 hours	24%
2-4 days	4%
>4 days	2%

Table 4: Type of fracture

Classification	No of Patients	Percentage
A2	16	8%
A3	34	17%
B1	40	20%
B2	16	8%
B3	24	12%
C1	26	13%
C2	20	10%
C3	24	12%

We have found AO classification to be very convenient and ideal for this study for determining results in all fractures.

Discussion

The results are evaluated view of time for Union, complications, functional aspects including range of movements, grip, strength and subjective evaluation and anatomical aspects including radiological assessment.

Procedure: Procedure involves reduction of fracture by applying longitudinal traction in Palmar flexion and

ulnar deviation to achieve ligamentotaxis then placement of external fixator and tightening of fixator in distracted/reduced state followed by K-wire placement for extra stabilization of fractured segment.

Time for union: Based on mobility, tenderness and radiology, our study showed average time for union of this fractures to be 8-10 weeks.

No case of non-union/ delayed union was observed in our study.

Younger, healthier person had union as early as 6 weeks as compared to older patients or patients with comorbid conditions and poor compliance.

Complications:

- i) Pin tract Infection (One patient)- staphylococcus aureus infection
- ii) Pin loosening (One patient due to osteoporotic bone)
- iii) Loss of reduction (two patients)
Required adjustment and re-reduction.
- iv) Reflex sympathetic dystrophy (two patients)
This subsided with vigorous physiotherapy, paraffin wax bath, elevation, NSAIDs and proteolytic enzymes.

Functional results:

i) Movements

Degrees	DF (No. of Fractures)	PF (No. of Fracture)
0-30	5%	10%
31-60	10%	12%
61-90	85%	75%

For routine functional activities 30° of dorsiflexion and 45% palmar flexion of wrist is minimal requirement.

>30° DF- 90%

>45° PF- 80%

Anatomical results:

i) Radial Length

Shortening and collapse at the fracture site, decreased radial length contribute to deformity

Radial Length	Pre-pinning	Post-pinning	Follow up
5 to 0	20	-	-
1 to 5	100	20	20
6 to 10	60	70	80
11 to 15	20	110	100

a) Pre-pinning radial length

Average-5.3 mm

Range- 2 to 13 mm

b) Post Pinning radial length

Average -9.7 mm

Range -5 to 14 mm

On an average we were able to gain 83% patients to the pre-pinning radial length. At final follow up only 10% had radial length loss of less than 5 mm.

ii) Palmar tilt

Palmar tilt(in degrees)	Pre-pinning	Post-pinning	Follow up
>-20	80	10	10
-20 to -11	70	-	-
-10 to -6	10	30	30
-5 to -1	20	-	20
0 to 5	10	20	20
6 to 10	-	20	20
11 to 15	-	90	80
16 to 20	10	20	20
>20	-	10	10
Total	200	200	200

Contributes to dinner fork deformity and mid carpal instability due to changes in load distribution

Average Palmar tilt in degrees

Pre-pinning – 15.3 deg Post-pinning- 9.8 deg Follow up- 9.6 deg

iii) Ulnar Variance (in mm)

Pre-pinning	Post-pinning	Follow up
0.3	0.7	0.65

iv) Radial tilt

Radial Tilt in degrees	Pre-pinning	Post-pinning	Follow up
<0	10	-	-
0 to 5	-	-	-
6 to 10	10	-	-
11 to 15	30	10	30
16 to 20	60	30	110
21 to 25	80	150	70
26 to 30	10	10	-
Total	200	200	200

Average radial tilt

Pre pinning: 16.3°

Post-pinning: 22.3°

Follow up: 20.0°

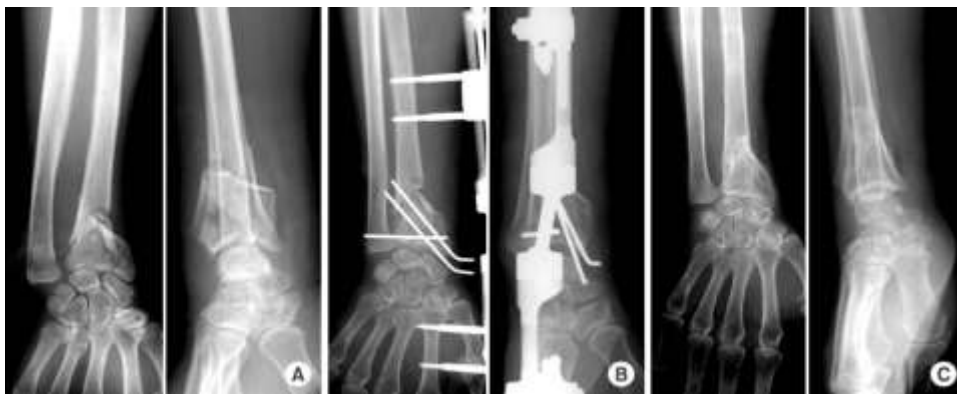Case 1

Fig. 3: A) Pre-op X ray; B) Immediate post-op x ray; C) Follow up x ray after 6 weeks

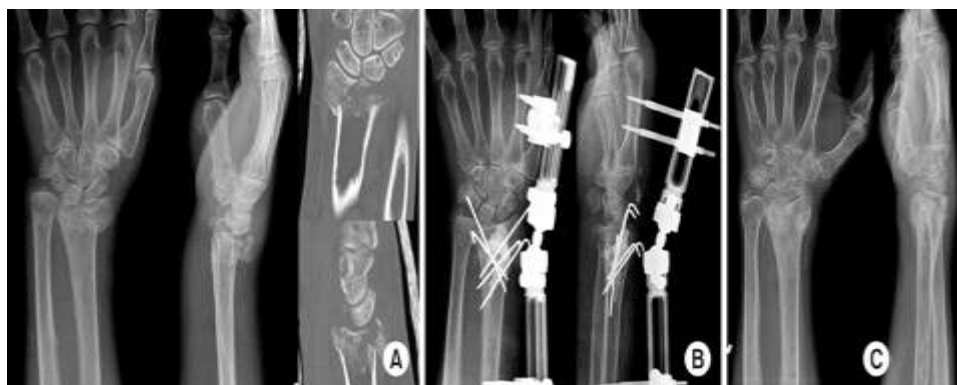Case 2

Fig. 4: (A) Pre-op x ray; (B) Immediate post op x ray; (C) Follow up x ray after 6 weeks

Conclusion and Summary

- This is a retrospective study of 200 consecutive unstable distal radius fractures.
- There were 66 females and 134 males in our study making male to female ratio 2:1.
- The average age in our study was 37.4 years.
- 140 dominant and 60 non dominant extremities were involved.
- Fractures were classified according to AO classification.
- Complications included pin tract infection, pin loosening, loss of reduction, reflex sympathetic dystrophy.
- No non-union was reported.
- There was also no delayed union reported.
- The patients were reviewed upto 6 months after surgery for radiological and functional assessment.
- Average volar tilt on follow up was 9.6 degrees,
- Average radial length on follow up was 9.7 mm
- Average radial inclination on follow up was 20 degrees.
- AO type C2 and C3 and osteoporotic bone showed more complications.
- 150 patients had excellent or good anatomical results, according to Sarmiento criteria.

- 170 patients had excellent or good functional results. According to Gartland and Werley scoring system

Result	No. of Fractures	Percentage
Excellent	100	50%
Good	70	35%
Fair	20	10%
Poor	10	05%
Total	200	100%

External fixation of all types of distal end radius fractures- unstable, comminuted and complex intra-articular fracture provide effective mean to treat these fractures with satisfactory anatomical and functional outcomes with minimally invasive technique.

Advantages of Aesculap clamp

- being small in size offers good ergonomics in placement of hardware
- eases reduction achievement
- increases patient compliance because of its light weight

References

1. Campbell's operative orthopedics. 13th edition. Distal radius fractures.
2. Cunningham's manual of practical anatomy, 15th edition, 80-81.
3. Manual of Internal fixation techniques recommended by Ao ASIF group, 3rd edition, 135.
4. Watson Jones, 6th edition, Distal radius fractures.
5. Rockwood and Green, 3rd edition R.M. Atkins.
6. Green's operative hand surgery 1 29 Fractures of the distal radius Diego L. Fernandez and Andrew K. Palmer.
7. The comprehensive classification of Fractures of Long Bones, 1990-M.E. Muller, S. Nazarian, P. Koch, J. Schatzker.
8. No.4. oct. 1951, Evaluation of healed Colle's Fractures John Gartland Jr., Charles W. Werley.
9. July 1953, colle's fractures, a study of 2000 cases from Newyork compensation board R.W. Bacorn, John Kurtzke.
10. Vol. 47B, No.4. November, 1995, Smith and Barton fractures James Ellis.
11. Vol 62A, June, 1990. Complications of Colle's fractures William P. Cooney.
12. July 73 A, No.3, March 1997, Current concepts Review Fractures of the distal end of the radius Jesse B. Jupier.
13. March 2003 Randell W. CWP M.D.
14. Current concept Review-Randell W. CWP-MD.