

## Evaluation the outcomes of flexible intramedullary nailing fixation of displaced midshaft clavicle fractures

Hemant Kumar<sup>1,\*</sup>, Ravinder K. Banga<sup>2</sup>, RS Boparai<sup>3</sup>, Jaspal Singh<sup>4</sup>

<sup>1,2</sup>Junior Resident, <sup>3</sup>Professor, <sup>4</sup>Assistant Professor, Dept. of Orthopaedics, Govt. Medical College, Amritsar, Punjab

**\*Corresponding Author:**

Email: hementsingle@gmail.com

### Abstract

**Introduction:** Fracture of the clavicle is common in occurrence with incidence of approximately 5% of all fractures seen in hospital emergency. These fractures are generally managed conservatively. Now days, titanium elastic nails are emerging as a minimally invasive treatment for displaced mid-clavicular fractures, which may be an alternative to plate fixation or even non-operative treatment.

**Objective:** The aim of this study is to assess the cosmetic outcome (malunion, asymmetry, scar formation), rate of bone healing and alignment of the clavicle (<30° or >30°) related to the flexible intramedullary nailing of midshaft fracture clavicle.

**Methods:** Between June 2012 to June 2014 in GMC & Hospital Amritsar, 50 patients with displaced, non-comminuted fracture of midshaft clavicle of either side underwent flexible intramedullary nailing with titanium elastic nail. Implant removal was performed in 90% cases after the fracture united completely.

**Results:** In this study, all fractures were united. Mean duration of radiological union was 10.3 weeks ranging from 6 to 20 weeks. Mean DASH score after 6 months of follow up was 7.7 ranging from 0.8 to 44.2. Mean constant self evaluated score was 80.2 ranging from minimum 43 to maximum 98 after 6 months of follow up.

**Conclusion:** Flexible intramedullary nailing is a minimally invasive technique for stabilization of displaced midshaft clavicle fractures and it is a simple procedure with excellent functional outcome in terms of quick return to activities and a high patient satisfaction rate with very good cosmetic outcome.

**Keywords:** Intramedullary clavicle nailing, Middle 1/3<sup>rd</sup> clavicle fractures, Titanium elastic nailing System (TENS).

### Introduction

Fractures of the clavicle is very common in occurrence with incidence of approximately 5% of all fractures seen in hospital emergency admissions. Out of which midshaft clavicular fractures are clearly the most common,<sup>(1)</sup> with a reported variable incidence of 69.2% to 76.2%<sup>(2,3)</sup> of total cases, in which 3/4<sup>th</sup> of the midshaft fractures are appreciably displaced.<sup>(2,3)</sup> The clavicle fractures are more commonly occurred in men (68%) than women (32%)<sup>(4)</sup> with road traffic accidents are the most common cause of the injury as reported in studies.<sup>(4)</sup>

Standard treatment for clavicular fracture is non-operative, using an arm-sling or figure-of-eight bandage for external fixation.<sup>(4)</sup> But it is noted in studies that conservatively treated displaced clavicular fractures have a higher incidence of non-union in between 10 to 15% and, even when they unite, result in an unsightly cosmetic deformity in the centre of the clavicle, shoulder dropping, shoulder discomfort, and patient dissatisfaction.<sup>(5,6)</sup> Pain and disability during the first three weeks of conservative treatment is an another disadvantage. Further it may also be associated with venous congestion of arms and a displaced fragment can compress the brachial plexus leading to neuropraxia after conservative treatment.<sup>(7)</sup> Furthermore decreased shoulder function due to clavicular shortening of more than 1-2 cm after non-operative fracture management has been reported. In athletes, either professional or amateur<sup>(8,9,10)</sup> restoration of the clavicle length and early

return to full activity with unimpaired function is of great importance. So the paradigm is now shifting towards operative treatment for displaced midshaft clavicular fractures.<sup>(11)</sup>

The gold standard for the surgical treatment has been open reduction and plate fixation through a large incision,<sup>(12)</sup> however, plating requires relatively extensive periosteal stripping, which can jeopardise the blood supply at the fracture site, thus adversely affecting fracture healing. Further stress shielding produced by rigid plates can lead to an 8% refracture rate after plate removal. In plate fixation surgical time is considerable, and infection rates of up to 18% have been reported. Additionally, the relatively long scar can be a cosmetic issue in some patients, and some individuals experience discomfort induced by the plate underneath the skin, thereafter additional procedures required for plate removal.

Another operative treatment is the intramedullary devices, which behaves as internal splints that maintain alignment without rigid fixation. Intramedullary device have advantages of a smaller incision, less dissection, load sharing fixation with relative stability that helps in copious callus formation.<sup>(13)</sup>

So in this study, our aim is to evaluate the outcomes of flexible intramedullary nailing fixation in displaced midshaft clavicle fractures.

## Materials and Method

The present prospective study comprised of a total of 50 cases of either sex of different age groups, with displaced non-comminuted fracture midshaft clavicle of either side admitted from June 2012 to June 2014 in the department of orthopaedics of Government Medical College Amritsar.

Clinical history, general physical examination and local examination were performed. Patients were accordingly investigated for operative and anaesthetic complications. The supportive and prophylactic therapy in the form of analgesics, antibiotics, anti-tetanus injection, Intravenous fluids, matched blood transfusion, wherever required, were given to stabilize the patient. There after the injured part was X-rayed to confirm bony injury and fracture geometry. Classification of fracture clavicle was done according to AO classification and an informed written consent of the patient was obtained before inclusion in the study. Exclusion criteria from the study was-

- Patients having undisplaced fracture middle third of clavicle.
- Patients having fracture clavicle in medial and lateral third.
- Patients with bony injuries of ipsilateral upper limb, nerve injuries were not considered for the study as it would affect the outcome.

**Operative Technique:** The patient was laid supine on a radiolucent operation table, under general anaesthesia. Part was scrubbed, painted and draped with sterile sheets with the respective arm so to be freely movable. A small incision of 1–1.5 cm was made near the sternal end of the clavicle. The antero-inferior edge of the cortex was opened after soft tissue dissection with an awl or a drill bit. The thickness of the nail was determined according to the diameter of medullary cavity. The original curvature of the nail tip was straightened slightly in order to facilitate better gliding in narrow medullary canal. The small and flattened tip helped in negotiating the nails against far cortex and preventing perforation of the cortex. A flexible nail of appropriate thickness was mounted on a Jacob's chuck and inserted in the medullary canal manually. Under image intensifier, the nail was advanced to the fracture site. When the tip reached the fracture, reduction was performed manually or percutaneously by means of a reduction clamp and the nail was pushed into the distal fracture fragment (Fig. 1 and 2). In case of failure of closed reduction, open reduction was done and the tip of the nail introduced under direct vision through a second small (2–3-cm) skin incision directly over the fracture site. The soft tissue, if found interposed, was cleared. Then the nail was advanced manually or with a gentle tap of a hammer into the distal fracture fragment. At the transition to the acromial end of the clavicle, accurate maneuvering of the tip of the nail was done under image intensifier control to avoid perforation of the curved thin dorsal cortex, thus, After reaching the end position, the nail was cut

close to the entry point in order to minimize soft tissue irritation, at the same time leaving sufficient protruding end for extraction later. Then the surgical wound at entry point was closed with skin suturing. If second incision over fracture site was given during reduction, wound closure was done with subcutaneous tissue suturing and skin suturing. Aseptic dressing done and arm pouch was applied for few days.

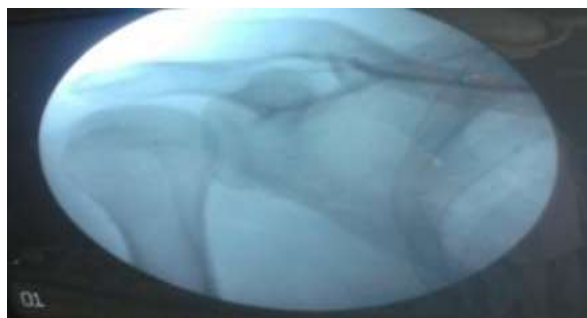


Fig. 1




Fig. 2

**Postoperative Care:** Appropriate post-operative antibiotics and analgesics were given for few days. Active movements of the shoulder started as early as possible within tolerable limit. Overhead abduction or flexion was restrained for 6 weeks, since increasing rotational loads on the clavicle could result in proximal migration of the nail. The first postoperative dressing was done on the third day. Stitches were removed on 11<sup>th</sup> day. Patients were called for follow up every 3-4 weeks, till complete union achieved.

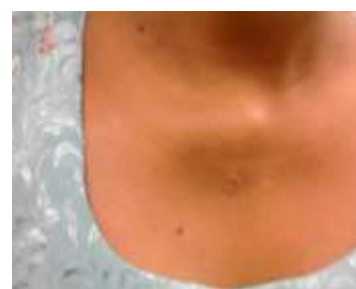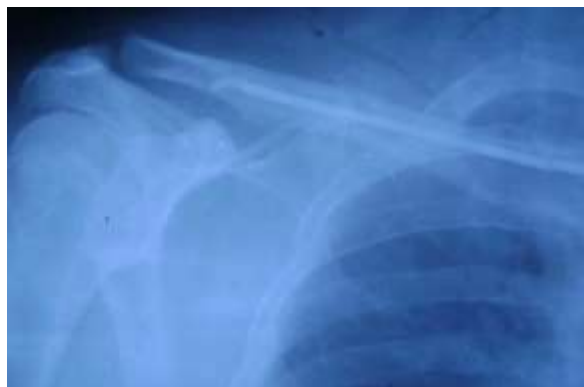### Outcome Assesment done by

- Disabilities of Arm Shoulder and Hand (DASH) score: 0 (best) to 100 (worst).
- The self-evaluated Constant score (0- 100 points).
- Subjective data were evaluated with reference to the cosmetic outcome (malunion, asymmetry, scar formation), bone healing and complications (nonunion).

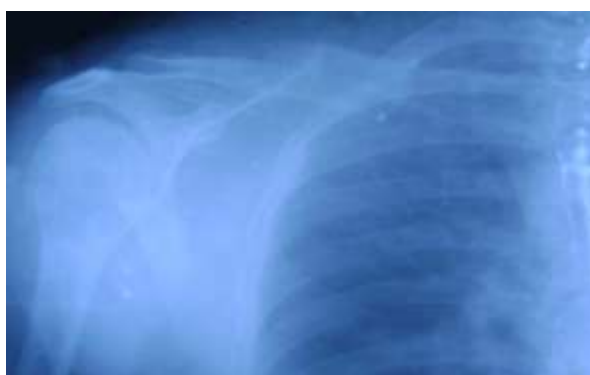### Results

A total of 50 patients met the inclusion criteria of diaphyseal midshaft, non-comminuted clavicle fractures. In this study, mean age of patients was 31.2 years

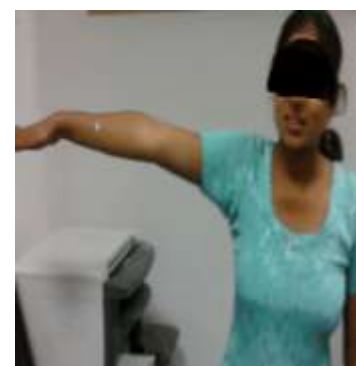ranging from minimum 18 years to maximum 54 years. Males were 32 and females were 18 in this study. Right side was involved in 29 cases and left side in 21 cases. Mechanism of injuries were roadside accident in 33 patients, fall from height in 12 patients, assault in 3 patients and sports injury in 2 patients. According to AO classification 36% were type B1, 60% type B2 and 4% cases were type B3. The duration from injury to surgery was less than 1 week in 41 patients, 8 patients were operated within 2-3 weeks of injury and 1 patient operated after 28 days. During surgery closed reduction succeeded in 52% and open reduction needed in 48% cases. The mean time of surgery was 54.8 minutes ranging minimum 25 minutes to maximum 85 minutes. All fractures were united. Mean duration of radiological union was 10.3 weeks ranging from 6 to 20 weeks. Soft tissue irritation at entry point in 8 patients. Hypertrophic scar formation over scar of entry point of nail in 2 patients. Proximal migration of nail in 2 patients. None of the patients had infection, nonunion and implant breakage. Most of the patients had well aligned union and no patients had angulation more than 30 degree. In the present study nail removal was done in 45 cases and in 5 cases implant was not removed because of refusal of patients. The mean time of nail removal was 7.1 months. In the present study mean Disabilities of Arm Shoulder and Hand (DASH) score after 6 months of follow up was 7.7 ranging from 0.8 to 44.2. Mean constant self-evaluated score was 80.2 ranging from minimum 43 to maximum 98 after 6 months of follow up.



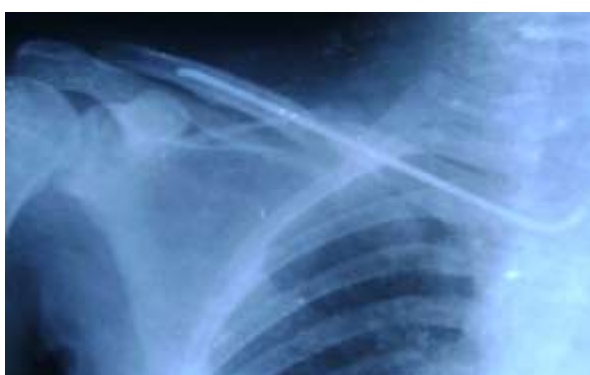6 weeks of follow up Single scar



Pre-operative x-ray



Functional Recovery at follow up of 6 months



Post-operative x-ray

### Discussion

This study was done with objective to study the outcome of operative treatment with flexible intramedullary nail. In the present study mean age of patients was 31.2 years. This incidence is in accordance with study done by Mackee<sup>(9)</sup> in 2006, which shows the

mean age of fracture clavicle is 37 years. This highest incidence in young age group is seen because they are most commonly involved in travelling, driving, sports activities and also are victims of assault.

In our study displaced midshaft fracture clavicle seen predominantly in males comprised of 32 males (64%) and 18 females (36%). The sex distribution of earlier reported study by Novak<sup>(14)</sup> in 2000 were 70% male and 30% female. Hence the incidence in present study closely correlates with previous study. This is probably due to type of society in which outdoor activities are predominantly preferred by males which predispose them to traffic accidents.

In the present study, right side was involved more commonly in 29 cases (58%) and left side in 21 cases (42%). Many studies also reported similar incidence of right side involvement e.g. 58.8% right and 41.2% left in the study of Postacchini<sup>(15)</sup> in 2010. It may be due to the force of trauma borne by right side as being the dominant side.

Mechanism of injuries classified mainly as roadside accident, fall and sports injuries. The present study showed mechanism of injuries were roadside accident in 33 cases (66%), fall in 12 cases (24%), assault in 3 cases (6%) and sports injury in 2 case (4%). Reported mechanism of injuries were roadside accident in 46%, fall in 20% and 34% sports injuries in the study of Hartmann<sup>(16)</sup> in 2008 and roadside accident in 62%, fall in 15%, sports injuries in 15% and assault in 8% cases in the study of Chin En Chen<sup>(17)</sup> in 2010.

Diaphysis non-comminuted type B1 were 36%, diaphysis wedge type B2 were 60% and diaphysis segmental type B3 was 4%. These findings were in accordance with earlier reported literature of Chin En Chen<sup>(17)</sup> in 2010 with type B1 23%, B2 73% and type B3 14%.

In the present study, the duration from injury to surgery was less than 1 week in 41 patients (82%). The mean duration of injury to surgery was 3.9 days. The duration from injury to surgery in earlier reported literature were 4 days (Jubel 2003),<sup>(18)</sup> 6 days (Meier 2006),<sup>(19)</sup> 6 days (Hartmann 2008).<sup>(16)</sup>

In the present study closed reduction succeeded in 26 cases (52%) and open reduction needed in 24 cases (48%). In earlier studies e.g. study done by Jubel<sup>18</sup> in 2003, closed and open reduction were 58% and 42% and in the study of Meier<sup>(19)</sup> done in 2006 were 50% and 50%. These data showed that flexible intramedullary nailing is a technically demanding procedure. Reasons to failure of closed reduction were –

1. Fractures situated in lateral part of midshaft.
2. Segmental type B3 fractures.
3. Soft tissue interposition.
4. Failure of maintenance of reduction during engagement of distal fragment of fracture.
5. Excessive time elapse since injury to surgery.
6. Inadequate straightening of tip of the flexible nail.
7. Ill defined medullary cavity of clavicle.

The mean time of surgery was 54.8 minutes ranging minimum 25 minutes to maximum 85 minutes. It is in accordance with data given in the study of Meier<sup>19</sup> in 2006 having mean time of surgery 62 minute with mean time for close reduction group was 39 minutes and for open reduction was 85 minutes.

In the present study mean duration of union was 10.3 weeks ranging from minimum 6 to maximum 20 weeks. The average duration of radiological union after flexible intramedullary nail fixation shown in the study of Yun Feng Chen<sup>(20)</sup> in 2010 were 2.2 month and 7.7 weeks in the study of Meier 2006<sup>(19)</sup> which are in accordance with the present study.

In the present study all 50 cases (100%) had fracture union. An older study of Kettler 2007<sup>(21)</sup> showed union in 98% cases and 2% nonunion. Another study by Hartmann 2008<sup>(16)</sup> showed union in 100% cases and no nonunion. So it shows that clavicular fractures have very good outcome as in case of union.

Soft tissue irritation at entry point in 8 patients. Hypertrophic scar formation over scar of entry point of nail in 2 patients. Proximal migration of nail in 2 patients. There was no complication of infection, nonunion, angulation more than 30% and implant breakage in any case. Overall, it can be stated that in the present study there was no any major complication regarding management and healing leading to reoperation. Minor complications were seen and that were managed on outdoor basis.

The mean time of nail removal was 7.1 months in our study which is in accordance with data given in older literature e.g. mean time was 7.1 months in study of Jubel 2003,<sup>(18)</sup> 7 months in study of Meier 2006<sup>(19)</sup> and 7.2 months in study of Yun Feng Chen 2010.<sup>(20)</sup>

Failure to union is not a major problem now a days, but functional outcome and cosmesis are main concerns.

The Disability of Arm Shoulder and Hand (DASH) score was calculated on scale 0-100, considering score 0 best and 100 worst. In the present study minimum Disability of Arm Shoulder and Hand score was 0.8 (best) and maximum was 44.2 (worst). The mean score was 7.7. In 76% cases score was less than 10 and in 88% cases were having score less than 20. In earlier studies it was 6.8 (0-43) in the study of Kettler 2007,<sup>(21)</sup> 2.5 (0.5-8.0) in the study of Yun Feng Chen 2010<sup>(20)</sup> and 3.4 (+/- \*4.8) in the study of Zhang W 2012<sup>(22)</sup> which was in accordance with present study.

The Constant Self Evaluated Score calculated on scale 0-100 where 0 is worst and 100 best. The minimum self-evaluated constant score was minimum 43(worst) to maximum of 98(best). The mean constant self-evaluated score was 80.2. In 88% cases constant self-evaluated scores were more than 70 and 12% cases were having scores less than 70. In older literatures of flexible intramedullary nail fixation of displaced midshaft clavicular fractures the values calculated were 98.3 in the study of Jubel 2003,<sup>(18)</sup> 98 ranging 93-100 in the study of Meier 2006,<sup>(19)</sup> 81 ranging 46-100 in the study of Kettler

M 2007,<sup>(21)</sup> 95.3+/- 3.9 in the study of Hartmann 2008,<sup>(16)</sup> 95.2 ranging 86.5-97.0 in the study of Yun Feng Chu 2010.<sup>(20)</sup>

## Conclusion

The acute treatment of middle-third clavicle fractures remains a subject of controversy.

Above data demonstrates early pain relief in combination with good shoulder function after acute operative treatment with flexible intramedullary nails resulting in quick return to activities and a high patient satisfaction rate. So flexible intramedullary nails are a promising minimally invasive treatment for displaced mid-clavicular fractures, which may be an alternative to plate fixation or even non-operative treatment.

## References

- Harrington MA, Keller TS, Seiler JGD. Geometric properties and the predicted mechanical behavior of adult human clavicles. *J Biomech* 1993;26:417-26.
- Nordqvist A, Petersson C. The incidence of fractures of the clavicle. *Clin Orthop* 1994;127-32.
- Robinson CM. Fractures of the clavicle in the adult. Epidemiology and classification. *J Bone Joint Surg Br* 1998;80:476-84.
- Epidemiology of clavicle fractures. Postacchini F, Gumina S, De Santis P, *J Shoulder Elbow Surg.* 2002 Sep-Oct;11(5):452-6
- Boehme D, Curtis RJ, DeHaan JT, et al. Nonunion of fractures of the midshaft clavicle. *JBJS (Am)* 1991;73:1219-26.
- Edelson JG. The bony anatomy of clavicular malunions. *J Shoulder Elbow Surg.* 2003 Mar-Apr;12(2):1735.
- Rowe CR. An atlas of anatomy and treatment of midclavicular fractures.
- Canadian Orthopaedic Trauma Society: Nonoperative treatment compared with plate fixation of displaced midshaft clavicular fractures. A multicenter, randomized clinical trial. *J Bone Joint Surg Am* 2007;89(1):1-10.
- McKee MD, Pedersen EM, Jones C, et al. Deficits following non-operative treatment of displaced midshaft clavicular fractures. *J Bone Joint Surg Am.* 2006; 88A:35-40.
- Zlowodzki M, Zelle BA, Cole PA, et al. Treatment of acute midshaft clavicle fractures: systematic review of 2144 fractures: on behalf of the Evidence-Based Orthopaedic Trauma Working Group. *J Orthop Trauma.*2005; 19:504-507.
- Smekal V, Irenberger A, Struve P, Wambacher M, Krappinger D, Kralinger FS. Elastic stable intramedullary nailing versus non-operative treatment of displaced midshaft clavicular fractures-a randomized, controlled, clinical trial. *J Orthop Trauma.* 2009;23:106-12.
- Frigg A, Rillmann P, Perren T, Gerber M, Ryf C. Intramedullary nailing of clavicular midshaft fractures with the titanium elastic nail: Problems and complications. *Am J Sports Med.* 2009;37:352-9.
- Mueller M, Ranger C, Striepens N, Burger C. Minimally invasive intramedullary nailing of midshaft clavicular fractures using titanium elastic nails. *J Trauma.* 2008;64:1528-34.
- Nowak J, Mallmin H, Larson S. The aetiology and epidemiology of clavicular fractures. A prospective study during a two-year period in Uppsala, Sweden. *Injury* 2000;35(5):353-8.
- Postacchini R, Gumina S, Farsetti P, Postacchini F. Long-term results of conservative management of midshaft clavicle fracture. *Int Orthop.* 2010 June;34(5):731-6.
- Hartmann F, Hessmann MH, Gercek E, Rommens PM. Elastic Intramedullary Nailing of Midclavicular Fractures. *Acta Chir Belg.* 2008;108:428-32.
- Chin YF, Zeng BF, Chen YJ, Wang HM, Xue JF, Chai YM, Xie XT Zhang C. Clinical outcomes of midclavicular fractures treated with titanium elastic nails. *Can J Surg* 2010;53(6):379-84.
- Jubel A, Andemahr J, Bergmann H, Prokop A, Rehm KE; Elastic stable intramedullary nailing of midclavicular fractures with titanium nail. *Clin Orthop Relat Res.* 2003 Mar;(408):279-85.
- Meier C, Grueninger P, Platz A. Elastic stable intramedullary nailing for midclavicular fractures in athletes: indications, technical pitfalls and early results. *Acta Orthop Belg.* 2006;72:269-75.
- Yung F, Bing F, Yu C, Hai W. Clinical outcomes of midclavicular fractures treated with titanium elastic nails. *Can J Surg.* 2010 Dec; 53(6): 379-384.
- Kettler M, Schieker M, Braunstein V, König M, Mutschler W. Flexible intramedullary nailing for stabilization of displaced midshaft clavicle fractures: technique and results in 87 patients. *ActaOrthop.* 2007 Jun;78(3):424-9.
- Zhang W, Chen QY, Kou DQ, Cheng SW, Zhao JK, Qi YJ, Peng L. Use of titanium elastic intramedullary nails in the treatment of adult midshaft clavicular fractures: technical skills, precautions and complications. *Zhongguo Gu Shang.* 2012 Apr;25(4):274-7.