

## Etiopathogenesis of posterior segment inflammation in a tertiary referral institute

Gopal S. Pillai<sup>1,\*</sup>, Natasha Radhakrishnan<sup>2</sup>, Sandhya A. Menon<sup>3</sup>

<sup>1</sup>Professor & HOD, <sup>2</sup>Associate Professor, <sup>3</sup>Consultant in Retina, Dept. of Ophthalmology, Amrita Institute of Medical Sciences, Kochi

**\*Corresponding Author:**

Email: gopalspillai@gmail.com

### Abstract

**Aim:** To analyze the causes and characteristics of posterior segment inflammation in the Vitreo-retinal department in a multispecialty hospital.

**Methods:** This is a retrospective study on 97 patients who presented with manifestations of posterior segment inflammation in a multispecialty hospital in the last 2 years were included in the study. They were analysed with respect to aetiology, clinical manifestations, intervention done and response to treatment.

**Results:** Posterior segment inflammation was most commonly seen as a manifestation toxoplasmosis (18.6%) followed by systemic vasculitic disorder like SLE (16.5%). Other common causes included infections like tuberculosis, (9.3%) endogenous (bacterial and fungal endophthalmitis (12.4%) and viral retinitis. Others were VKH, vasculitis with unknown etiology, Behcets disease and sarcoidosis

**Conclusions:** We found toxoplasmosis to be the commonest single etiological agent. There was a significantly higher incidence of posterior segment involvement due to systemic vasculitis in our study population which is hitherto been unreported in other study populations.

**Keywords:** Posterior Uveitis, Vasculitis, Endophthalmitis, Inflammation.

### Introduction

Uveitis is a complex intraocular inflammatory disease resulting from several etiological entities. Causes of uveitis vary in different populations. Infectious uveitis occur in greater frequency in the developing world while noninfectious forms predominate in the developed countries.<sup>(1-9)</sup> Most of the studies describing the patterns of uveitis represent cases in exclusive eye care institutions. Few studies tend to analyze uveitis in association with systemic disease.<sup>(7,8)</sup> Here, we attempt to characterize posterior segment inflammatory disease in our institution, which is a large tertiary care multispecialty hospital. Systemic diseases with posterior segment involvement like the specific vasculitic entities and endogenous endophthalmitis are included in the study.

The purpose of current study is to analyze the causes and characteristics of posterior segment inflammation in the Vitreo Retinal department in a multispecialty hospital.

### Materials and Methods

The clinical records of all patients with posterior segment inflammation seen in the last 2 years at our centre were analyzed retrospectively. Information regarding age, gender, laterality, details of ocular examination, investigations done and final diagnosis were recorded. The data also included systemic associations if any, intervention done and response to treatment. Patients with post cataract surgery endophthalmitis, inflammation secondary to trauma or surgery and patients with less than 6 months of follow up were excluded from the study. Patients presenting with endogenous endophthalmitis were included. It was conducted according to the provisions of the Declaration of Helsinki in 1995.

Ocular examination included detailed slit lamp, intraocular pressure measurements and fundus examination. Routine investigations included complete blood counts, ESR, Mantoux test, serology for toxoplasma

and HIV, ANA titres, serum calcium and serum ACE and X ray chest. A Fundus Fluorescein angiogram, Optical Coherence Tomogram, ultrasound B Scan and additional tailored laboratory investigations were done whenever necessary.

Our study included intermediate, posterior and panuveitis based on the International Uveitis Study Group criteria.<sup>(10)</sup> We also included cases of retinal vasculitis as it involves inflammation of retinal vasculature. Standard diagnostic criteria were employed for specific uveitic entities. An internist was consulted whenever needed. The final etiological diagnosis was based on clinical features, laboratory investigations and systemic evaluation.

### Results

Of the data of 124 cases collected for the study, 27 cases were excluded based on the exclusion criteria. Therefore a total of 97 cases were included in the analysis.

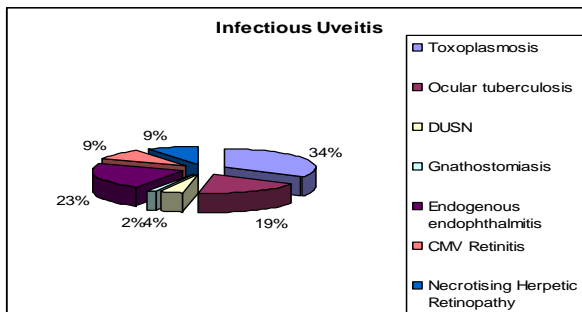
There were 52 cases of infectious uveitis and 45 cases of noninfectious uveitis. The mean age of the infectious uveitis group was 40.02 years (Range-6-68 years) and the noninfectious uveitis group was 35.78 years (Range-12-74 years). The mean age of the whole study group was 38.05 years. Analysis of sex distribution showed 55.7% males and 44.3% females among the total cases. Among the infectious cases there were 61.5% males and 38.5% females. Among the noninfectious cases there was a slight female preponderance (48.9% males and 51.1% females). Of the infectious cases 82.7% was unilateral and 17.3% was bilateral while among noninfectious cases 73.3% was bilateral and 26.7 % unilateral.

We arrived at an etiological diagnosis of all cases based on morphology of the lesions and ancillary tests except two cases of endogenous endophthalmitis and 11 cases of vasculitis. Among the infectious uveitis lab investigations were positive in 57.7% cases and negative in 42.2% cases. The frequency of distribution of each is

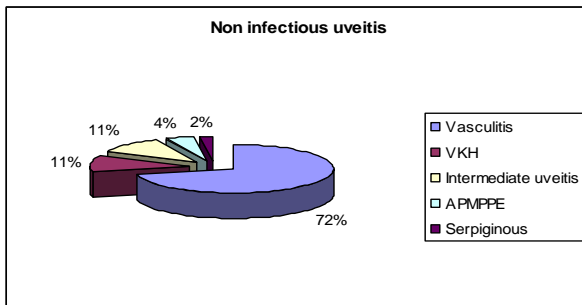
shown in the Table 1. The frequency distribution of different entities is shown in Fig. 1.

**Table 1: The frequency distribution of various etiologies**

	Frequency	Percentage
Necrotising herpetic retinopathy	4	4.1
<b>Toxoplasmosis</b>	18	<b>18.6</b>
Tuberculosis	9	9.3
DUSN/Gnathostomiasis	3	3.1
Endogenous endophthalmitis	12	<b>12.4</b>
CMV retinitis	6	6.2
<b>SLE</b>	16	<b>16.5</b>
Sarcoid Vasculitis/ Serpiginous Choroiditis	2	2.1
Vasculitis of unknown etiology	12	<b>12.4</b>
VKH	5	5.2
Behcet's disease	3	3.1
Intermediate uveitis	5	5.2
AMPPE	2	2.1
Total	97	100.0

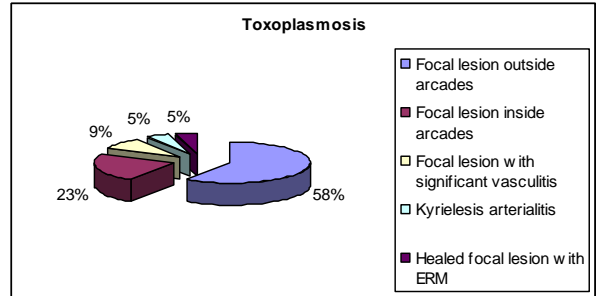


**Fig 1: The frequency distribution of infective uveitis**



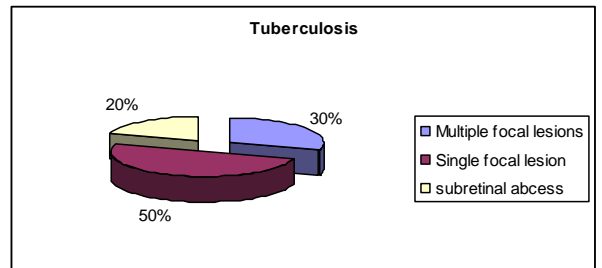
**The frequency distribution of noninfective uveitis**

Toxoplasmosis constituted 18.6% of total and 34% of infectious cases. IgM Positivity was obtained in 8 of the 18 cases and high titres of IgG obtained in one case. The morphology of lesions seen in toxoplasmosis is given in the pie chart below. One case underwent surgical intervention. 72.2% of eyes had a final visual outcome on > 6/12 (Fig. 2).



**Fig. 2: Location and Morphology of toxoplasmosis**

Among the 9 cases diagnosed as ocular tuberculosis, Mantoux positivity and evidence of active systemic tuberculosis were obtained in all the cases. One case had a positive aqueous PCR. The morphology of the lesions are given the pie chart below. Visual outcome was > 6/12 in 6 of the cases, < 6/24 in 2 cases and < 6/60 in one case with subretinal abscess (Fig. 3).



**Fig. 3: Location and Morphology of tuberculosis**

Three cases presented with a worm with active posterior segment inflammation. All the cases underwent laser barrage and had a final visual outcome > 6/12.

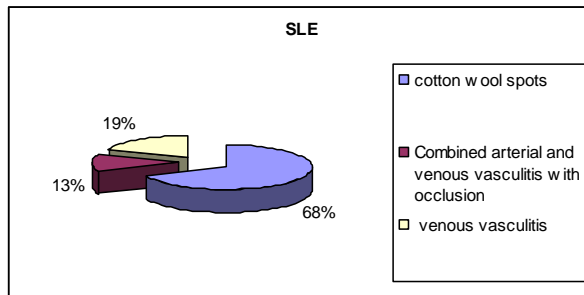
Among the 12 cases diagnosed as endogenous endophthalmitis, all cases underwent a diagnostic vitreous tap and 10 cases underwent vitrectomy. Lab reports revealed bacterial etiology in 3 and fungal etiology in 7 cases. The organism could not be identified in 2 cases. All the cases were systemically immunosuppressed. All the cases had a final visual outcome < 6/24 with the eyes with vitrectomy having a visual outcome < 6/60 except for one eye which had a final visual outcome of 6/18.

Among the 10 viral retinitis cases, 5 cases had IgM positive for cytomegalovirus. The rest of the cases diagnosed as necrotizing herpetic retinopathy, a positive herpes simplex virus PCR was obtained for one case. Two of the eyes underwent surgical intervention. All these 10 cases had underlying immunosuppression.

Among the 45 cases of non-infective inflammation, there were 16 cases of systemic lupus erythematosus, 11 cases of vasculitis with unknown etiology, 1 case of pANCA positive vasculitis, 3 cases of Behcet's disease, 5 cases of VKH, 5 cases of intermediate uveitis, 2 cases of AMPPPE, and 1 case each of Sarcoidosis and serpiginous choroiditis.

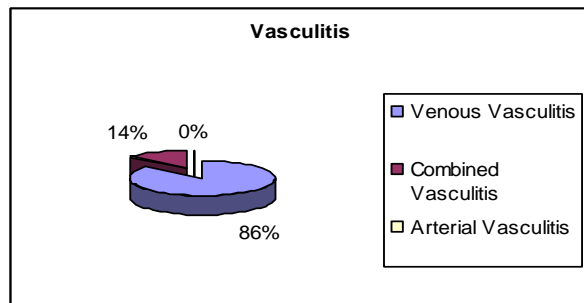
Systemic lupus erythematosus constituted 16 of the total 45 noninfective uveitis and 16.5% of the total uveitis cases. All the cases were bilateral with a final visual visual

outcome > 6/12 except for one case with a visual outcome of 3/60 in one eye (Fig. 4).

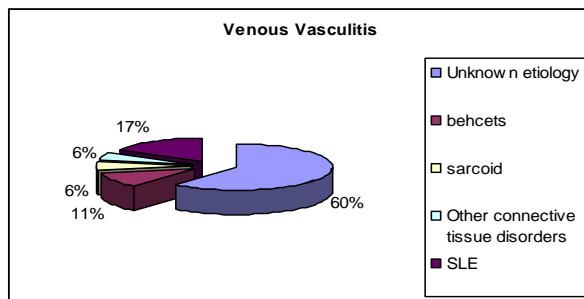


**Fig. 4: Morphology of SLE**

Cases presenting with a predominant picture of vasculitis were further analyzed and the frequency distribution was obtained. The results are shown in Fig. 5 and 6.



**Fig. 5: Break-up of vasculitis**



**Fig. 6: Etiology of venous vasculitis**

Surgical intervention was done in 10 cases of endogenous endophthalmitis, 1 case of healed toxoplasmosis and 2 cases of viral retinitis and 1 case of vasculitis with unknown etiology and 1 case of sarcoid vasculitis and 1 case of gnathostoma. Intravitreal injection was given in 2 cases of intermediate uveitis and 1 case of Behcet's disease with vascular occlusion. Lasers were given in all the 2 cases which had a dead worm and 1 case of SLE which had occlusive vasculitis.

## Discussion

In contrast to other studies describing the patterns of uveitis in eye care setups, we attempt to describe the patterns of posterior segment inflammation in the vitreoretina unit of a large multispeciality hospital in Kerala.

Males outnumbered females in our study. This pattern was similar to other studies from India and abroad.<sup>(1)</sup> Uveitis affects young adults most commonly. In previous clinical based surveys, 60-80% of all patients had mean age of presentation between 35-45 years of age.<sup>(1,3,4)</sup> This goes in accordance to our study results which has a mean age of 38.05 years.

Toxoplasmosis was the commonest cause (18.6%) of uveitis, both infective and non-infective in our study. A similar pattern (27.87%) was described by Biswas J et al in a South Indian study.<sup>(6)</sup> Other studies also describe a similar trend.<sup>(9)</sup> Toxoplasmosis as the commonest etiological agent was described in other studies from North East and Western India.<sup>(1,3,4)</sup> Toxoplasmosis is the single most common cause of infectious uveitis in reports from the developed world.<sup>(1)</sup>

The diagnosis of toxoplasmosis was based on the presence of typical focal necrotizing retinitis associated with or without pigmented scars. 58% of toxoplasmosis presented with focal retinitis outside the arcades. It is important to note that 2 cases presented with severe vasculitis. Kyrielesis arteriopathy was described in one case. IgM Positivity was obtained in 8 of the 18 cases (including the 2 cases with severe vasculitis) and high titers of IgG obtained in one case. The rest of the cases were diagnosed based on the typical clinical appearance. All the cases were treated medically. One case underwent vitrectomy for secondary epiretinal membrane formation. All the cases 72.2% of the eyes had a good visual outcome. The eyes with lesions within the arcades had a poorer outcome.

The diagnosis of ocular tuberculosis was based on the criteria described by Gupta et al.<sup>(11)</sup> Among the 9 cases with an etiological diagnosis of ocular tuberculosis, in 8 cases a presumptive diagnosis based on morphology, Mantoux positivity, and presence of systemic tuberculosis. One case was definitive with a positive aqueous PCR. 8 cases were associated with pulmonary tuberculosis while 1 patient had disseminated military tuberculosis in pregnancy. Most of the eyes had multifocal choroiditis while one case developed a subretinal abscess. Visual outcome was > 6/12 in 7 of the cases, < 6/24 in 2 cases and < 6/60 in one case with subretinal abscess. The frequency of tuberculosis (9.3%) in the current study was higher than in South Indian studies,<sup>(1)</sup> but lesser than a major North Indian Study (29.73%).<sup>(3)</sup>

Infective endogenous endophthalmitis constituted 12.4% of our cases. This may be attributed to the setting of a multispeciality hospital. All the cases were systemically immunosuppressed. 5 cases had end stage liver disease, 1 post liver transplant patient, 4 cases of uncontrolled diabetes, 1 case of malignant insulinoma and 1 case of non Hodgkin's lymphoma on chemotherapy. 4 eyes had bilateral infection. All cases underwent a diagnostic vitreous tap and 10 cases underwent vitrectomy.<sup>(12)</sup> Vitreous aspirate reports revealed bacterial etiology in 3 and fungal etiology in 7 cases. Among the fungal candida was identified in 4 and aspergillus in 3. The bacterial agents were klebsiella in 2 and gram positive cocci in 1 case. The organism could not be identified in 2 cases. These patients generally had a poorer visual outcome.

We noted a high percentage of viral retinitis cases (about 10%). Another major South Indian study reports the frequency of herpetic retinitis to be about 4.6%.<sup>(1)</sup>

The diagnosis of viral retinitis was made based on the criteria given by American Uveitis Society.<sup>(13)</sup> All the cases with CMV positivity were HIV cases with a CD4 count < 50/microL. A vitreous PCR positivity for Herpes Simplex virus was obtained in only one case of necrotizing viral retinitis. The eyes with necrotizing viral retinitis had a poor visual outcome with one eye ending up in no perception of light.

Two cases presented with dead worm with retinitis and vasculitis. A presumed diagnosis of DUSN was made in 2 cases while the migrating worm in the third case was removed from the anterior segment and identified as gnathostoma spinigerum by CDC, Atlanta. Laser therapy was given in the first 2 cases while the worm was removed in the third case. All cases had a favorable visual outcome. There are few cases of gnathostomiasis described in Indian literature.<sup>(14,15)</sup> This study reports a rare case with retinal vasculitis.

It is interesting to note that among our posterior uveitis cases, vasculitis was the commonest morphological picture noted. Venous vasculitis predominated the clinical picture while 3 cases had combined arterial and venous vasculitis with vascular occlusion. SLE constituted the majority of the vasculitis cases followed by 11 cases where there were no systemic association os favoring lab diagnosis. There were 3 cases of proven Behcet's and 1 case of Sarcoidosis. All the cases with proven diagnosis were referred to us from the immunology clinic of the hospital. There was one case of pANCA positive vasculitis. All the cases were treated by an immunologist.

Vasulitis due to SLE is generally not described in studies of posterior uveitis. A western study describes this condition as a miscellaneous cause of posterior uveitis.<sup>(8)</sup> All the cases of SLE were diagnosis and referred from the immunology clinic of the hospital. The diagnosis was based on standard diagnostic criteria. All cases had bilateral manifestations with 68% of the cases having only multiple cotton wool spots. 19% of the eyes had venous vasculitis while 2 eyes had combined arterial and venous vasculitis with vascular occlusion and significant ischemia of which underwent laser therapy to the ischemic areas. The visual outcome as > 6/12 in all the eyes except for the 2 eyes with significant ischemia.

This study had all the described posterior segment manifestations described for SLE ranging from cotton wool spots due to microangiopathy to severe occlusive vasculitis. Though arterial vasculitis is the classically described picture this study had a higher percentage of venous vasculitis.<sup>(13,16)</sup>

There were 5 cases (5.2%) which presented with a predominantly vitreous inflammation. In India, the percentage of intermediate uveitis varies from 9.5-17.4%.<sup>(15)</sup> The IUSG recommended the term intermediate uveitis for any known casue and all idiopathic cases as parsplanitis. A definite snow bank was identified only in 1 case. Since a definite causative agent nor a systemic association could not be established in the rest, we have termed them as idiopathic. 2 cases had significant macular edema and were treated with intravitreal injections. 4 of the cases were managed with oral steroids while one case required systemic immunosuppression to control the inflammation. All the cases showed good response to treatment.

The VKH cases were diagnosed based on standard criteria,<sup>(18)</sup> and all showed good response to treatment. The frequency is 5.2% in our study while the it is 1.4% and 10.4% respectively in South and North Indian studies.<sup>(1,3)</sup>

## Conclusion

We found toxoplasmosis to the commonest single etiological agent. There was a significantly higher incidence of posterior segment involvement due to systemic vasculitis in our study population which is hitherto been unreported in other study populations. Also we had a higher incidence of infective endophthalmitis. We attribute this to the peculiarity of our patient population.

## References

1. Rathinam SR1, Namperumalsamy P. Global variation and pattern changes in epidemiology of uveitis. *Indian J Ophthalmol.* 2007;55(3):173-183.
2. Chen SC1, Chuang CT1, Chu MY1, Sheu SJ. Patterns and Etiologies of Uveitis at a Tertiary Referral Center in Taiwan. *Ocul Immunol Inflamm.* In press.
3. Singh R, Gupta V, Gupta A. Pattern of uveitis in a referral eye clinic in north India. *Indian J Ophthalmol.* 2004;52(2):12-125.
4. Das D, Bhattacharjee H, Bhattacharyya PK, Jain L, Panicker MJ, Das K, Deka AC. Pattern of uveitis in North East India: a tertiary eye care center study. *Indian J Ophthalmol.* 2009;57(2):144-146.
5. Dandona L, Dandona R, John RK, McCarty CA, Rao GN. Population based assessment of uveitis in an urban population in southern India. *Br J Ophthalmol.* 2000;84(7):706-709.
6. Biswas J, Narain S, Das D, Ganesh SK. Pattern of uveitis in a referral uveitis clinic in India. *Int Ophthalmol.* 1996-1997;20(4):223-228.
7. Henderly DE, Genstler AJ, Smith RE, Rao NA. Changing patterns of uveitis. *Am J Ophthalmol.* 1987;103(2):131-136.
8. Rothova A, Buitenhuis HJ, Meenken C, Brinkman CJ, Linssen A, Alberts C, Luyendijk L, Kijlstra A. Uveitis and systemic disease. *Br J Ophthalmol.* 1992;76(3):137-141.
9. Rathinam SR, Cunningham ET Jr. Infectious causes of uveitis in the developing world. *Int Ophthalmol Clin.* 2000;40(2):137-152.
10. Bloch-Michel E, Nussenblatt RB. International Uveitis Study Group recommendations for the evaluation of intraocular inflammatory disease. *Am J Ophthalmol.* 1987;103(2):234-5.
11. Gupta V1, Gupta A, Rao NA. Intraocular tuberculosis--an update. *Surv Ophthalmol.* 2007;52(6):561-587.
12. Turno-Krecicka A, Misiuk-Hojlo M, Grzybowski A, Oficjalska-Mlynczak J, Jakubowska-Kopacz M, Jurowska-Liput J. Early vitrectomy and diagnostic testing in severe infectious posterior uveitis and endophthalmitis. *Med Sci Monit.* 2010;16(6):CR296-300.
13. C.Stophen Foster –Diagnosis and Treatment of Uveitis 2002 edition.
14. Basak SK1, Sinha TK, Bhattacharya D, Hazra TK, Parikh S. Intravitreal live Gnathostoma spinigerum. *Indian J Ophthalmol.* 2004;52(1):57-58.
15. Barua PI, Hazarika NK, Barua N, Barua CK, Choudhury B. Gnathostomiasis of the anterior chamber. *Indian J Med Microbiol.* 2007;25(3):276-8.
16. Abu El-Asrar AM1, Herbert CP, Tabbara KF. Differential diagnosis of retinal vasculitis. *Middle East Afr J Ophthalmol.* 2009;16(4):202-218.
17. Babu BM, Rathinam SR. Intermediate uveitis. *Indian J Ophthalmol.* 2010 Jan-Feb;58(1):21-27.
18. Moorthy RS, Inomata H, Rao NA. Vogt-Koyanagi-Harada syndrome. *Surv Ophthalmol.* 1995;39(4):265-292.