

Evaluation of various chemical peels in facial melanosis

Sanjiv Choudhary¹, Shivani Dhande^{2,*}, AL Singh³

^{1,3}Professor, ²Resident, JNMS, DMIMS, Wardha, Maharashtra

***Corresponding Author:**

Email: shivanidhande1504@gmail.com

Abstract

Introduction: Chemical peeling is a preferred, generally safe and relatively economic day procedure for pigmentary skin disorders and for skin revival.

Aim: Evaluation of various chemical peels (Salicylic acid, Trichloroacetic acid & Glycolic Acid) in facial melanosis (Melasma, Photomelanosis & Post Acne Pigmentation).

Materials and Method: It was a randomized parallel control single blind study consisting of total of 36 cases, 12 cases each of melasma, photomelanosis and post acne pigmentation, enrolled after considering various inclusion and exclusion criteria. Before applying the peel, a written informed consent was obtained and a post auricular test peel was implemented. Patients were divided into three groups, containing 12 patients each of melasma, photomelanosis and post acne pigmentation. Out of 12 patients of each facial melanosis, groups of four were formed and first group was treated with SA peel 20% (done once in 2 weeks), second group with GA peel 50% (done once in 3 weeks) and third group with TCA 15% (done once in 3 weeks) respectively with total six settings. Post peel topical sunscreen application was mandatory. Investigator's Global Improvement Assessment and Patient's satisfaction grading scale was used on basis of clinical photographs taken at baseline and at end of six weeks to assess improvement in all the three facial melanosis.

Results: For the 36 patients enrolled, an marked improvement was seen in 10(27.77%) patients, 13(36.11%) patients showed moderate improvement while it was mild improvement for the remaining 13(36.11%) patients.

Conclusions: In our study GA(50%),TCA(15%) & SA(20%) peels showed excellent response in melasma, photomelanosis and post-acne pigmentation respectively. All the 3 peeling agents were well tolerated without any significant side-effects in the above specified concentrations.

Limitations: Sample size is limited. Further study with large sample size is required to further validate the findings of present study.

Keywords: Facial melanosis, Glycolic acid, Salicylic acid, Trichloroacetic acid

Key Messages: GA(50%), TCA(15%) & SA(20%) peels have excellent response in melasma, photomelanosis and post-acne pigmentation respectively and a good safety profile.

Introduction

Chemical peeling is the application of chemical agent to the skin that causes controlled destruction of a part of the epidermis, leading to exfoliation of epidermis and remodeling of the dermis. It is a preferred, generally safe and relatively economic day procedure for pigmentary skin disorders and for skin revival. By the level of necrosis, they are classified into superficial, medium, and deep peels. Causes of facial melanosis can be multiple like post inflammatory pigmentation due to acne vulgaris, melasma, perioral and periorbital melanosis, amyloidosis, lichen planus pigmentosus, photomelanosis, Reihl's melanosis. Facial melanosis is also one of the cause for psychological stress, necessitating its safe and effective treatment. Quite a variety of peels are available with distinct mechanisms of actions, which can be modulated by changing concentrations. Agents of very superficial peels include glycolic acid (30-50%) and trichloroacetic acid (10%); superficial peels include salicylic aci (20-30%), glycolic acid (50-70%) and trichloroacetic acid (10-30%), medium depth peels include glycolic acid (70%) and trichloroacetic acid (30-50%), deep peels include phenol (88%) and Baker Gordon peel. In this study, we have used only superficial peel to see its effect on different facial melanosis.

Aim

Evaluation of various chemical peels (Salicylic acid, Trichloroacetic acid & Glycolic Acid) in facial melanosis (Melasma, Photomelanosis & Post Acne Pigmentation).

Materials and Method

It was a randomized parallel control single blind study with duration of 1 year from May 2014 – May 2015. Ethical clearance was taken from institutional ethics committee before enrolling patients for the study. Total 36 cases,12 cases each of epidermal melasma, photo melanosis and post acne pigmentation were enrolled after considering various inclusion criterias (age between 20 to 50 years, Fitzpatrick's skin type 3, 4 & 5 and patients with realistic expectations) and exclusion criterias (dermal melasma, pregnant and lactating mothers, patients with keloidal tendency, active herpes simplex infection or past history of the same, patients with hypersensitivity to salicylic acid, trichloroacetic acid and glycolic acid, patients on systemic isotretinoin). Woods lamp examination was done to confirm the epidermal type of melasma.

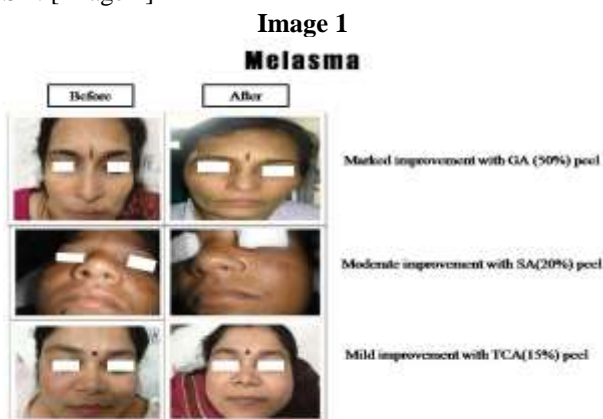
Clinical photographs at the beginning of therapy and then serially, were taken to assess the clinical response.

Before applying the peel, a written informed consent was taken and a post auricular test peel was implemented. Patients were divided in three groups, containing 12 patients each of epidermal melasma, photomelanosis and post acne pigmentation. Out of 12 patients of each facial melanosis, groups of four were formed and first group was treated with SA peel 20% (done once in 2 weeks), second group with GA peel 50% (done once in 3 weeks) and third group with TCA 15% (done once in 3 weeks) respectively with total six settings.

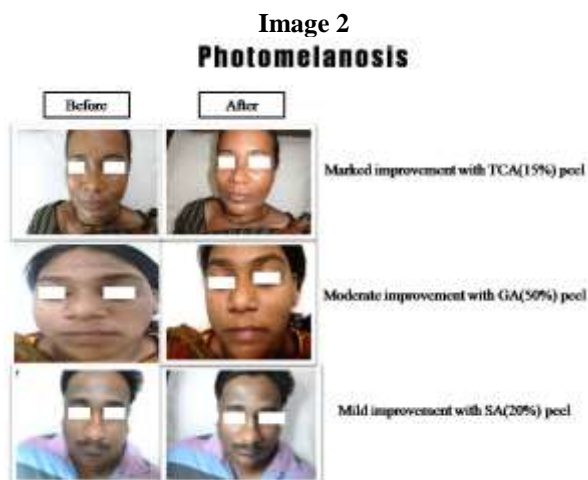
Prior to application of peeling agent patients were asked to clean the face with face-wash and water. After patting the face dry, again spirit and acetone soaked cotton swabs were applied all over face to remove all oil and remaining dirt. White petroleum jelly was applied over sensitive areas (near corner of eyes, nose and mouth) for protection. Peels were applied with cotton buds/gauze with mild strokes. After a contact period off 5 minutes with GA peel and after frosting with TCA peel and pseudofrosting with SA peel, neutralization was done with cold water. Post peel topical sunscreen application was mandatory. Investigator's Global Improvement Assessment: (1=worse, 2=no improvement, 3=mild improvement, 4=moderate improvement, 5=marked improvement) and Patient's satisfaction grading scale (>70% - excellent response, 50-70% - good response, <50% - average response) was used to assess improvement in all the three facial melanosis.

Results

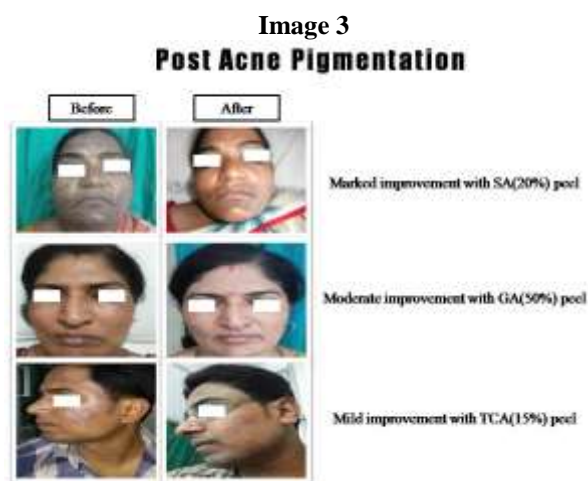
In our study of 12 patients of melasma, 4 (33.33%) patients showed marked improvement; 3 (25%) with GA and 1(8.33%) of TCA. Moderate improvement was seen in 4 (33.33%) patients; 1(8.33%) each for GA & SA and 2(16.66%) for TCA. Mild improvement was seen in 4 (33.33%) patients; 1 (8.33%) for TCA and 3 (25%) for SA. [Image 1]



Of 12 patients of photomelanosis, marked improvement was seen in 3 (25%) patients of TCA. Moderate improvement was seen in 4 (33.33%) patients, 1 (8.33%) each of TCA & SA and 2 (16.66%) of GA. Mild improvement was seen in 5 (41.66%) patients; 3 (25%) for SA and 2 (16.66%) of GA. [Image 2]



Of 12 patients of post acne pigmentation, marked improvement in 3 (25%) patients; 2 (16.66%) of SA and 1 (8.33%) of TCA. Moderate improvement was seen in 5 (41.66%) patients; 2 (16.66%) of SA and GA and 1 (8.33%) of TCA. Mild improvement was seen in 4 (33.33%) patients; 2 (16.66%) for SA and TCA both. [Image 3]



Transient blackening of skin with burning sensation was seen in cases treated with TCA and SA. Post procedural itching and redness was noted with GA peel.² No major side effects in the form of persistent pigmentation was seen.

Discussion

For the 36 patients enrolled, an marked improvement was seen in 10(27.77%) patients, 13(36.11%) patients showed moderate improvement while it was mild improvement for the remaining 13(36.11%) patients. In cases of post-acne pigmentation, SA peel had shown better response as compared to GA and TCA similar to result observed by Handog et al.⁽³⁾ SS Joshi et al. found SA peels are safe and clinically

effective in post-inflammatory hyperpigmentation due to acne in patients with Fitzpatrick skin phototypes IV to VI.⁽⁴⁾ According to Grimes PE, superficial salicylic acid peels are both safe and efficacious for treatment of acne vulgaris, post-inflammatory hyperpigmentation and melasma in patients with skin types V and VI.⁽⁵⁾

In cases of melasma, GA peel showed better response as compared to SA and TCA, which was also noted by Kumari R et al in their study.⁽⁶⁾ Grover C et al. observed a good to fair response was seen in more than 90% of the patients with GA peels.⁽⁷⁾ SM Javaheri et al. established that daily application of topical sunscreen and GA facial peel with a duration of 5 min once every month is effective treatment modality for melasma in Indian patients.⁽⁸⁾

In cases of photomelanosis, TCA peel had shown better response compared to GA and SA peel, similar to findings observed by Bari AU et al.⁽⁹⁾ According to L. Wiest study, Trichloroacetic acid (TCA) with the broadest indication spectrum is the most frequently used peeling substance in various concentrations and the indications for use are actinically damaged skin, skin resurfacing, precancerous lesions, folds and pigment lesions.⁽¹⁰⁾ PS. Collins found TCA peel a time-honored peeling agent that has no known systemic toxicity and effective in reversing the effects of actinic damage.⁽¹¹⁾

Conclusion

In our study GA(50%),TCA(15%) & SA(20%) peels showed excellent response in melasma, photomelanosis and post-acne pigmentation respectively. All the 3 peeling agents were well tolerated without any significant side-effects in the above specified concentrations.

References

1. Herndon J, Makino E, Stephens T, Mehta R. Hydroquinone-free Skin brightener system for the treatment of moderate-to-severe facial hyperpigmentation. *The Journal Of Clinical And Aesthetic Dermatology* 2014;7:27-31.
2. Puri N. Comparative study of 15% TCA peel versus 35% glycolic acid peel for the treatment of melasma. *Indian Dermatology Online Journal* 2012;3:109-113.
3. Handog E, Datuin MS, Singzon I. Chemical peels for acne and acne scars in Asian skin: Evidence based review. *Journal of Cutaneous and Aesthetic Surgery* 2012;5:239-46.
4. Joshi SS, Boone SL, Alam M, Yoo Simon, White L, Rademaker A et al. Effectiveness, Safety, and Effect on Quality of Life of Topical Salicylic Acid Peels for Treatment of Postinflammatory Hyperpigmentation in Dark Skin. *Dermatologic Surgery* 2009;638-644.
5. Grimes PE. The Safety and Efficacy of Salicylic Acid Chemical Peels in Darker Racial-ethnic Groups. *Dermatologic Surgery* 1999;25:18-22.
6. Kumari R, Thappa DM. Comparative study of trichloroacetic acid versus glycolic acid chemical peels in the treatment of melasma. *Indian Journal Of Dermatology, Venereology Leprology* 2010;76:447.
7. Grover C, Reddu BS. The therapeutic value of glycolic acid peels in dermatology. *Indian Journal of Dermatology, Venereology Leprology* 2003;69:148-150.
8. Javaheri SM, Handa S, Kaur I, Kumar B et al. Safety and efficacy of glycolic acid facial peel in Indian women with melasma. *International Journal of Dermatology* 2001;40:354-357.
9. Bari AU, Iqbal Z, Rahman SB. Tolerance and safety of superficial chemical peeling with salicylic acid in various facial dermatoses. *Indian Journal Of Dermatology, Venereology Leprology* 2005;71:87-90.
10. Weist L. Chemical peels in aesthetic dermatology. *The Dermatologist* 2004;55:611-620.
11. Collins PS. Trichloroacetic Acid Peels Revisited. *Dermatologic Surgery* 1989;15:933-940.