

## Coats' Disease of the Retina: A rare entity that merits consideration in diagnosis: A mini review

Amal Abd El hafez

Dept. of Pathology, Faculty of Medicine, Mansoura University, Egypt

Email: amalabdelhafez@gmail.com

### Abstract

Coats' disease is an idiopathic retinal vascular disorder with particular affection of young male patients. Different theories have been proposed to explain the pathophysiology of Coats' disease including genetic mutation, pericyte loss, breakdown of the endothelial blood-retinal barrier and hypercholesterolemia. The disease presents clinically with strabismus and leukocoria that should be differentiated from retinoblastoma and other clinical conditions with the same features. It is crucial for the pathologist to be familiar with the characteristic histopathological features of Coats' disease including telangiectatic retinal vessels, exudative retinal detachment, and disorganization of ocular structure with deposition of lipid material eliciting foreign-body granuloma. Ophthalmoscopy is often sufficient to make the diagnosis of Coats' disease; however, other diagnostic modalities may be necessary. The management of Coats' disease is dependent on its clinical stage.

### Introduction

Coats' disease is an idiopathic retinal vascular disorder with no systemic manifestations also known as exudative retinitis or retinal telangiectasia. The disease was first described in 1908 by George Coats', a Scottish ophthalmologist. He observed a variable range of small aneurysms and dilated capillaries with sub- and intra-retinal fluid and exudate accumulation with particular affection of young male patients.<sup>(1)</sup>

In practice, a general pathologist usually does not have the chance to receive and diagnose specimens from patients with Coats' disease. Even ophthalmic pathologists hardly receive an enucleated eye because of Coats' disease.<sup>(2)</sup>

### Pathogenesis

Mutations in Norrie disease protein gene (NDP gene or X-linked exudative vitreo-retinopathy 2 protein gene), encoding Norrin protein that controls vascular development of vertebrate retina, have been implicated in Coats' disease as well as in other diseases involving retinal vasculogenesis.<sup>(3,4)</sup> Although the disease is non-hereditary and sporadic cases are the rule, "Coats'-like" retinopathy has been observed in genetic syndromes such as autosomal dominant facio-scapulo-humeral muscular dystrophy (Haller-Mann-Streiff syndrome) and familial renal-retinal dystrophy (Senior-Loken syndrome).<sup>(5)</sup>

The pathophysiology of Coats' disease entails "pericyte loss", which permits for the establishment of aneurysms. In a similar mechanism to diabetic retinopathy, breakdown of the endothelial blood-retinal barrier with subsequent leakage into the vessel wall, mural disorganization, aneurysmal dilatations and telangiectasia are observed.<sup>(6)</sup>

Earlier articles hypothesized that both juvenile and adult forms of Coats' disease exist and that hypercholesterolemia and an inflammatory process in the uvea have some role in the pathogenesis of the adult

form of the disease.<sup>(7)</sup> However, others favored the same basic pathogenesis and histopathology for both adult form and the juvenile forms of Coats' disease.<sup>(8)</sup>

### Clinical features

From a clinical aspect, Coats' disease occurs more commonly in children and has a clear male predominance during the first decade of life.<sup>(9)</sup> Most patients present clinically with unilateral decreased vision, strabismus, leukocoria, pain in the eye or angle-closure glaucoma.<sup>(8,10)</sup> In a high percentage of cases the clinical manifestations, strabismus and leukocoria, are thought to be caused by retinoblastoma,<sup>(9)</sup> this poses unilateral retinoblastoma as the most important differential diagnosis of Coats' disease, which occurs in the same age group and has some overlapping clinical manifestations.<sup>(11)</sup> Alternate diagnoses should particularly be considered in female, adult-onset or bilateral cases.

Cases of Coats' disease diagnosed in its earlier stages, enables ophthalmologists to save the globe and even useful vision in most of the cases.<sup>(2)</sup> However, in cases with late diagnosis, the affected eye is enucleated because of total exudative detachment of the retina or because of untreatable secondary glaucoma. In contrast to retinoblastoma, no further treatment is to be given.<sup>(8)</sup>

### Gross and microscopic pathological features

Macroscopically, enucleated eyes with Coats' disease shows bullous retinal detachment that typically adjoins the back surface of the lens and ciliary body. The lens-iris diaphragm is displaced anteriorly, causing secondary closed-angle glaucoma via a pupillary block mechanism. A yellow, gelatinous subretinal fluid is accumulated that contains shining cholesterol crystals.<sup>(12)</sup>

During histopathological examination, the presence of telangiectatic retinal vessels confirms the diagnosis of Coats' disease. These fusiform or saccular venous

dilations tend to involve the temporal parafoveal quadrant of the retina and are especially common superotemporally. Intravenous fluorescein angiography frequently reveals an area of capillary non-perfusion adjacent to the abnormal vessels.<sup>(12)</sup> Other diagnostic findings includes variable degrees of exudative retinal detachment, disorganization of the anterior segment, subretinal fluid appearing as pools of eosinophilic exudate composed of periodic acid-Schiff (PAS)-positive material, rhomboidal cholesterol clefts (that are dissolved by lipid solvents during processing) and lipid-laden macrophages. Lipid deposition in the retina may induce foreign body granulomatous inflammation.<sup>(6,12)</sup> The exudative retinal detachment in Coats' disease is caused by leakage of lipoprotein fluid from telangiectatic retinal vessels. The presence of those vessel abnormalities differentiates Coats' disease from other causes of retinal detachment.<sup>(9)</sup> Immunohistochemical characteristics of the disease include the positive reaction for vimentin, fibronectin and CD68.<sup>(7)</sup> Decreased numbers of endothelial cells in the telangiectatic retinal vessels can be demonstrated using Factor VIII immunostaining.<sup>(6)</sup> This finding supports previous studies using electron microscopy.<sup>(13)</sup>

**Clinical stages of Coats' disease:** The natural history is of Coats' disease highly variable but progression is generally expected. Staging can be helpful in monitoring disease activity and response to treatment. Coats' disease has different stages depending on how it is affecting the retinal capillaries and retina:

**Stage 1:** Telangiectasia only, causing little change to the retina and vision.

**Stage 2:** Telangiectasia and exudation with increased effect on the retina and changes in vision (2A, extrafoveal exudation; 2B, foveal exudation).

**Stage 3:** Retinal detachment caused by large areas of exudation. This is when the vision is likely to be poor.

**Stage 4:** Complete detachment of the retina and the development of other complications, such as secondary glaucoma which can be treated, although sight is still likely to be poor.

**Stage 5:** Usually at this stage an eye has no sight and no treatment is available to improve sight. In most cases the eye is not painful, but if it were treatment may be needed, to prevent the pain or further damage to the eye.<sup>(10)</sup>

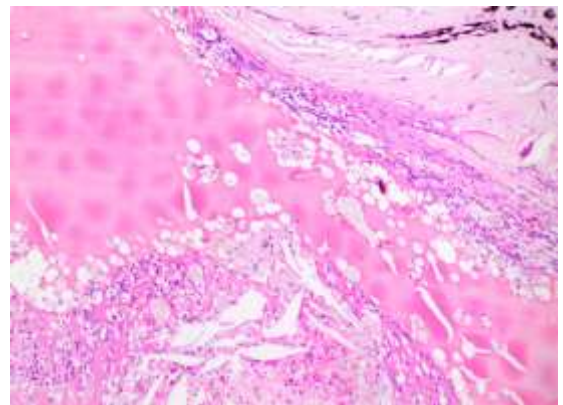
### Diagnosis

Ophthalmoscopy is often sufficient to make the diagnosis of Coats' disease. Examination under anaesthesia may be necessary in younger children. Fundus photography is useful at baseline and follow-up monitoring for progression of the disease. Fluorescein angiography optimally visualizes the vascular abnormalities. Optical coherence tomography, including intraoperative techniques<sup>(14)</sup> has been reported as useful in localizing subtle intraretinal edema or

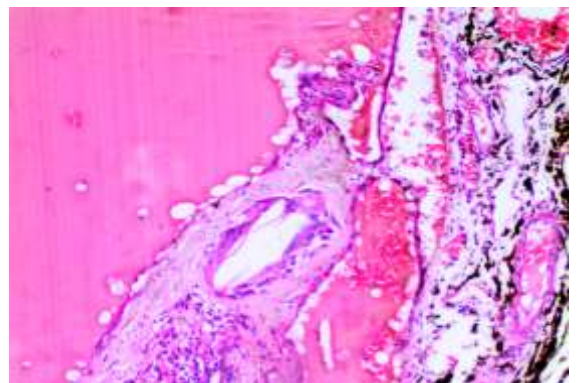
subretinal fluid, as well as monitoring response to therapy.<sup>(15,16)</sup> In advanced disease with extensive subretinal fluid, B scan ultrasound may be useful to rule out mass lesion.<sup>(17)</sup> CT and MRI may be beneficial in atypical cases to exclude calcification or enhancement that may be indicative of retinoblastoma.<sup>(16)</sup>

**Differential diagnosis:** The role of histopathology develops obviously in differentiating Coats' disease from its clinical mimics namely retinoblastoma, persistent hyperplastic primary vitreous (PHPV) and ocular toxocariasis (OT).

Leukocoria is the classic clinical manifestation of retinoblastoma, however histopathology reveals small round blue cell tumor that arises from and destroys the retina. Tumor show extensive necrosis and mitoses. Flexner-Wintersteiner rosettes with a central lumen; Homer Wright rosettes indicative of neuroblastic differentiation and fleurettes indicative of photoreceptor differentiation are characteristic.<sup>(12,18)</sup> In our experience, we encountered a case of a 4-year-old male child who underwent unilateral enucleation for a clinically diagnosed retinoblastoma. After thorough sampling and microscopic examination of sections taken from the enucleated eye, the diagnosis of Coats' disease was confirmed with its typical histopathological features (Fig 1, 2); meanwhile retinoblastoma was excluded with certainty.



**Fig. 1: Coats' disease of the eye showing disorganized ocular structure, pools of eosinophilic exudate, rhomboidal cholesterol clefts and lipid-laden macrophages**



**Fig. 2: The same case showing telangiectatic retinal vessels with pools of eosinophilic exudate material. Foreign body granulomatous inflammation is evident in response to deposited lipid material**

Meanwhile, PHPV derived its name in 1955 as a form of persistent fetal vasculature; however it is described now as a congenital malformation of the primary vitreous associated with a retrolental white plaque of fibrovascular tissue. Typically PHPV presents as unilateral leukocoria and mostly identified among male infants. The disease may be categorized as anterior if a retrolental opacity, elongated ciliary processes or cataract were present. PHPV is described as posterior when elevated vitreous membrane; optic nerve stalk; a retinal fold or retinal dysplasia; retinal detachment or optic nerve hypoplasia are considered.<sup>(19)</sup>

Toxocarasis is an infection by the nematode larvae of *Toxocara canis* that occur at varying ages with male predominance. Most of the cases are unilateral and bilateral cases are less than 40% in the literature. The dominating histopathology is posterior pole or peripheral eye granuloma with nematode endophthalmitis in which the larva can be found within the inflammatory lesion. Diagnosis is confirmed by the identification of serum antibody to the *Toxocara* larvae.<sup>(20,21)</sup>

### Management

Management of Coats' diseases seems to be stage-dependent. Although observation may be appropriate in some very limited peripheral stage 1 Coats' disease, early ablative or combination therapy can limit exudation and, ultimately, prevent vision loss. Laser photocoagulation is the modality of choice for mild to moderate disease with exudation. If there is significant subretinal fluid, as in stage 3 disease, cryotherapy may be required.<sup>(22)</sup> Intravitreal injections pharmacotherapy can be considered as an adjuvant to ablative technique. Combination therapy (e.g., intravitreal triamcinolone or anti-vascular endothelial growth factor agents before or at the time of ablation) offers the potential benefit of immediate stabilization with long-term control. Intravitreal bevacizumab plus thermal ablation was shown to have fewer treatment failures over laser alone. The risks and benefits of intravitreal injections should be carefully considered since cataract, elevations in intraocular pressure and other injection-related complications are all possibilities.<sup>(23)</sup> Surgical intervention is reserved for late stage or refractory disease. Patients with extensive retinal detachment may benefit from vitrectomy. In particular, patients with pre-retinal membranes or contribution from tractional components may require membrane peel. Enucleation is indicated in stage 4 and 5 disease with extensive exudative retinal detachment, secondary neovascular glaucoma where a blind, painful eye may develop.<sup>(24)</sup>

### Conclusion

It is of particular importance for the pathologist to be acquainted with the histopathological features of Coats' disease and to distinguish it from retinoblastoma as the prognosis and management vary substantially between both entities. Though, retinoblastoma is a malignancy with a high mortality rate when not properly diagnosed and treated and a misdiagnosis of retinoblastoma can submit a child to the potential risks and side effects of chemotherapy. On the contrary, early stages of Coats' disease can be managed conservatively and it doesn't require further treatment following proper management.

### Disclosure

No relevant financial affiliations or conflicts of interest to disclose.

### References

1. Coats G. Forms of retinal diseases with massive exudation. *R Lond Ophthalmol Hosp Rep* 1908;440-525.
2. Ridley ME, Shields JA, Brown GC, Tasman W. Coats' disease. Evaluation of management. *Ophthalmology*. 1982;89:1381-1387.
3. Black GC, Perveen R, Bonshek R, Cahill M, Clayton-Smith J, et al. Coats' disease of the retina (unilateral retinal telangiectasia) caused by somatic mutation in the NDP gene: A role for norrin in retinal angiogenesis. *Hum Mol Genet*. 1999;8(11):2031-2035.
4. Payabvash S, Anderson JS, Nascene DR. Bilateral persistent fetal vasculature due to a mutation in the Norrie disease protein gene. *Neuroradiol J*. 2015; 28(6):623-627. doi: 10.1177/1971400915609350.
5. Newell SW, Hall BD, Anderson CW, Lim ES. Hallermann-Streiff syndrome with Coats' disease. *J Pediatr Ophthalmol Strabismus* 1994;31:123-125.
6. Fernandes BF, Odashiro AN, Maloney S, Zajdenweber ME, Lopes AG and Burnier Jr. MN. Clinical-histopathological correlation in a case of Coats' disease. *Diagnostic Pathology*. 2006; 1:24. doi:10.1186/1746-1596-1-24.
7. Weller M, Bresgen M, Heimann K, Wiedemann P. Immunohistology of proliferative vitreoretinopathy following giant tear detachment. *Klin Monatsbl Augenheilkd*. 1989;195:323-325.
8. Tarkkanen A and Laatikainen L. Coats's disease: clinical, angiographic, histopathological findings and clinical management. *British Journal of Ophthalmology*. 1983;67:766-776.
9. Chang MM, McLean IW, Merritt JC. Coats' disease: a study of 62 histologically confirmed cases. *J Pediatr Ophthalmol Strabismus*. 1984;21:163-168.
10. Shields JA, Shields CL, Honavar SG, Demirci H. Clinical variations and complications of Coats' disease in 150 cases: the 2000 Sanford Gifford Memorial Lecture. *Am J Ophthalmol*. 2001;131:561-571.
11. Shields JA, Shields CL. Review: Coats' disease: the 2001 LuEsther T. Mertz Lecture. *Retina*. 2002;22:80-91.
12. Ralph C and Eagle JR. Foundations of Clinical Ophthalmology. Chapter 21, Retinoblastoma and Simulating Lesions. 2006 by Lippincott Williams & Wilkins. <http://www.oculist.net/downat0502/prof/ebook/duanes/pages/v9/v9c021.html>.

13. Tripathi R, Ashton N. Electron microscopical study of Coats' disease. *Br J Ophthalmol*. 1971;55:289-301.
14. Henry CR, Berrocal AM, Hess DJ, Murray TG. Intraoperative spectral-domain optical coherence tomography in Coats' disease. *Ophthalmic Surg Lasers Imaging*. 2012;43:e80-84.
15. Jun JH, Kim YC, Kim KS. Resolution of severe macular edema in adult Coats' disease with intravitreal triamcinolone and bevacizumab injection. *Korean J Ophthalmol*. 2008;22(3):190-193.
16. Kessner R, Barak A, Neudorfer M. Intraretinal exudates in Coats' disease as demonstrated by spectral-domain OCT. *Case Rep Ophthalmol*. 2012;3(1):11-15.
17. Atta HR, Watson NJ. Echographic diagnosis in advanced Coats' disease. *Eye*. 1992;6:80-85.
18. Chang CY, Chiou TJ, Hwang B, Bai LY, Hsu WM, Hsieh YL. Retinoblastoma in Taiwan: survival rate and prognostic factors. *JpnJ Ophthalmol*. 2006;50:242-249.
19. Hunt A, Rowe N, Lam A, Martin F. Outcomes in persistent hyperplastic primary vitreous. *Br J Ophthalmol*. 2005; 89(7): 859-863. doi: 10.1136/bjo.2004.053595.
20. Woodhall D, Starr MC, Montgomery SP, Jones JL, Lum F, Read RW, Moorthy RS. Ocular toxocariasis: epidemiologic, anatomic, and therapeutic variations based on a survey of ophthalmic subspecialists. *Ophthalmology*. 2012;119:1211-1217.
21. Ahn SJ, Ryoo NK, and Woo SJ. Ocular toxocariasis: clinical features, diagnosis, treatment and prevention. *Asia Pac Allergy*. 2014;4(3):134-141.
22. Couvillion SS, Margolis R, Mavroffjides E, Hess D, Murray TG. Laser treatment of Coats' disease. *J Pediatr Ophthalmol Strabismus*. 2005;42:367-368.
23. Othman IS, Moussa M, Bouhaimed M. Management of lipid exudates in Coats disease by adjuvant intravitreal triamcinolone: Effects and complications. *Br J Ophthalmol*. 2010;94:606-610.
24. Pitcher J and Regillo C. How to Diagnose and Manage Coats' Disease. *Review of ophthalmology*. Philadelphia. 2013.  
<https://www.reviewofophthalmology.com/article/how-to-diagnose-and-manage-coatsand8217-disease-42782>.