

Cytomorphological Evaluation of Gouty Tophi- A case report

Dhiraj B. Nikumbh^{1,*}, Nikhil U. Ningurkar², Shirish R. Gondane³

¹Professor, ^{2,3}Assistant Professor, Dept. of Pathology, ACPM Medical College, Dhule, Maharashtra

***Corresponding Author:**

Email: drdhirajnikumbh@rediffmail.com

Abstract

Soft tissue nodules around joints can pose a diagnostic challenge to clinicians as well as pathologist and radiologist. The periarticular nodules have many differentials from inflammatory to neoplastic ones. Gouty tophi is one of differential of these conditions. Fine needle aspiration cytology (FNAC) of these periarticular nodules is important and valuable diagnostic tool for diagnosing gouty tophi in view of its characteristic cytomorphology. We highlight the role of FNAC in diagnosing gouty tophi in 65-year-old female presented with deformed swelling of 2nd toe of right foot.

Keywords: Tophi, Gout, Periarticular, FNAC, Cytomorphology

Introduction

Gout constitutes about 2 to 5% of chronic joint diseases. The metatarsopharyngeal joint are often the first to be involved; but other joint of the hand and feet are also frequently involved. The various differentials of periarticular nodules could be ganglion cysts, gouty tophi, rheumatic nodules and synovial chondromatosis to synovial sarcoma.⁽¹⁾ Fine needle aspiration cytology (FNAC) is OPD, cost effective, safe and popular clinical practice in diagnosing periarticular nodules.⁽²⁾ We highlight the cytomorphological and differential diagnosis of gouty tophi diagnosed on FNAC in a 65year old female presented with deformed nodular mass in 2nd toe of right foot.

Case Report

A 65-year-old female presented to orthopedics OPD of our hospital with chief complaints of irregular nodular deformed swelling of 2nd toe of right foot. The swelling is accompanied with dislocation of joint along with pus discharging through tip of 2nd toe. Past history of trauma was obtained. Personal and family history was not contributory. Local examination revealed firm mild tender swelling measuring 4x3 cms in 2nd toe of right foot (Fig. 1). The overlying skin shows discharging pus. X-ray right foot showed pathological fracture, eroded bone and soft tissue swelling of 2nd metatarsophalangeal joint (Fig. 2). Clinically suspected as osteolytic lesion? bone tumor and FNAC was advised. FNAC was performed by 23 gauge needle under all aseptic precautions. On FNAC granular whitish material was aspirated. On light microscopy pap stain revealed numerous needle shaped crystals of uric acid (Fig. 3, 4). Many uninucleated and multinucleated histiocytes are noted along with stacks of needle shaped crystals on a hemorrhagic background. Unstained smears also revealed negative stained needle shaped crystals. On basis of these cytomorphological features, diagnosis of gouty tophi was rendered. Post FNAC for confirmation of gout, patient was

investigated biochemically and shows slight elevated serum uric acid as 8 mg/dl confirms the diagnosis at gouty tophi.

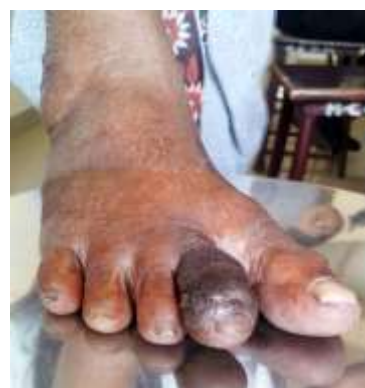

Fig. 1: Photograph showing nodular deformed soft tissue swelling of 2nd toe of right foot

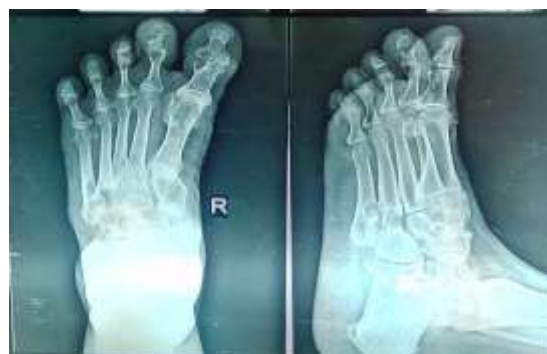

Fig. 2: Radiograph showing eroded bone, fracture and soft tissue mass of 2nd toe of right foot

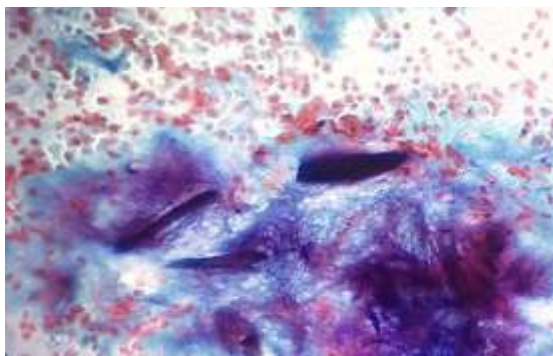


Fig. 3: Photomicrograph showing numerous needle shaped crystals of uric acid with any uninucleated and multinucleated histiocytes on calcified bluish background (Pap,x400)

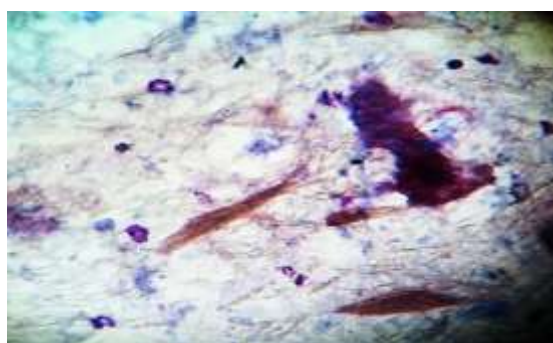


Fig. 4: Negative stained needle shaped monosodium urate crystals of varying sizes on hemorrhagic background (Pap,x400)

Discussion

Gout is characterized by repeated, relapsing attacks of joint pain in a chronic hyperuricemic crystal induced arthropathy. Pathologically, demonstration of monosodium urate crystals in the synovial fluid or by FNAC is must for definitive diagnosis.⁽³⁾ The presentation of gouty tophi as periarticular nodule is not common and can be mistaken for malignancy. Gout is caused by persistent chronic hyperuricemias due to result of inborn error of purine metabolism, diminished renal excretion of uric acid or secondary due to acquired kidney disease or in tumorous conditions due to excess cell turnover. Gout manifest as asymptomatic mass to acute arthritis, chronic tophaceous gout or nephrolithiasis.⁽⁴⁾

Diagnosis of gout is straight forward in typical cases as by presence of arthritis and hyperuricemia. However in diabetics and alcoholics both the criteria are absent.⁽⁴⁾ In such cases, radiological feature also atypical and misleading. X-ray of gouty tophi showed soft tissue swelling, bone erosion and solid masses (tophi) as in our case. These were not seen in diabetics and alcoholics so diagnosis is difficult in seen scenario. FNAC has a popular role now a day in diagnosis of gouty tophi and only handful of case reports are published in the literature.⁽²⁾

Grossly chalky white material on aspiration and demonstration of monosodium urate needle shaped crystals are diagnostic of gouty tophi. Granular myxoid amorphous material admixed with foamy histiocytes, multinucleated giant cells and chronic inflammatory cells.⁽⁵⁾ The material get washed off while staining, so dry slide (unstained) and wet mount preparation from needle aspirates can demonstrate crystals.⁽⁵⁾ Role of polarizing microscope is also important to demonstrate negatively birefringent crystals.⁽²⁾ Due to unavailability of polarizing microscope we couldn't demonstrate negative birefringence. Cytologically obtained main differential for gout is pseudogout. In pseudogout the crystals are smaller, rhomboid and weakly birefringent, whereas gouty tophi crystals are needle shaped and strongly birefringent.⁽²⁾ Radiologically calcification is absent in gout and present in pseudogout. The second differential- tumoral calcinosis, calcification is seen but crystals are absent. Tophaceous pseudogout is rare clinical forms of calcium pyrophosphate dihydrate crystal deposition (CPPD) disease with sites are temporomandibular joint, finger, toes and cervical spine etc.^(2,5)

Conclusion

Demonstration of birefringence, needle shaped crystals on synovial fluid/ FNAC is effective diagnostic tool for diagnosing gouty tophi. Cytomorphological features differs the crystals from other conditions like pseudogout. FNAC is single, rapid, OPD, noninvasive alternative procedure to biopsy procedure for accurate diagnosis of gouty tophi. In this article, we highlight the role of FNAs in periarticular gouty tophi.

References

1. Dodd LG, Major nm. Fine-needle aspiration cytology of articular and periarticular lesions. *Cancer*.2002;96(3):157-65.
2. Agarwal K, Pahuja S, Agarwal C, Harbhanjanka A. Fine needle aspiration cytology of gouty tophi with review of literature. *JOC*.2007;24(3):142-145.
3. Kalpana B, Mahore S. Cytodiagnosis of gouty arthritis. *J Clin Cas Rep*.2012;2(10):1-2.
4. Nicol KK, Ward WG, Pike EJ, Geisinger KR, Capperllari JO, Scott EK. Fine needle aspiration biopsy of gouty tophi; lesions in cost effective patient management. *Dign Cytopathol*.1997;17:30-5.
5. Rege J, Shet T, Naik L. Fine needle aspiration of tophi for crystal identification in problematic cases of gout. A report of two cases. *Acta Cytol*.2000;44:433-6.