

Management of accidental ingestion of an endodontic file by a 3 year old child patient -A case report

Amina Sultan^{1,*}, Akanksha Juneja²

¹Associate Professor, ²Assistant Professor, Dept. of Pediatric Dentistry, Faculty of Dentistry, Jamia Millia Islamia, New Delhi

***Corresponding Author:**

Email: aminasultan.jmi@gmail.com, amina255@yahoo.com

Abstract

Accidental aspiration and ingestion is a potential clinical complication commonly seen in all the field of dentistry where the manipulation of instruments and materials in the oral cavity creates an environment of risk. Incidence of accidental ingestion and aspiration have been reported in various articles and reviews in dental literature and it is observed that ingestion is the most prevalent emergency during dental procedures and is more common in pediatric population with 80% of cases occurring in children and peak incidents in the age group of 6 months to 3years of ages. 80-90% of ingested foreign items will pass through the gastrointestinal tract uneventfully while 10%-20% may require endoscopic removal but only 1% or less may necessitate surgical intervention. While these events occur infrequently in dentistry but the potential morbidity with a single episode is too high to ignore. Hence general practitioners and pedodontist should be aware of the associated risks of such mishaps and the importance of timely and appropriate intervention.

Keywords: Ingestion, Aspiration, Endodontic, Gastrointestinal tract, Endoscopy, Emergency

Introduction

Accidental aspiration and ingestion is a potential clinical complication commonly seen in all the fields of dentistry where the manipulation of instruments and materials in the oral cavity creates an environment of risk.^(1,2,3,4) While undergoing dental treatment patient can swallow or aspirate any foreign object of a varied shape or size ranging from small burs, endodontic files, crowns, copper bands, orthodontic bands to a large dental prosthesis or components of restorative or impression materials.^(4,3,5) However ingestion of foreign bodies during a routine intraoral examination is very rare.⁽⁴⁾

Incidence of accidental ingestion and aspiration have been reported in various articles and reviews in dental literature and it is observed that iatrogenic ingestion is the most prevalent emergency during dental procedures.^(1,7,8) and is more frequent in pediatric population^(2,5,6,7) with 80% of cases occurring in children and peak incidents in the age group of 6 months to 3years of ages.^(5,6,7) In adults ingestion occurs in certain vulnerable groups such as elderly, mentally impaired, in patients with altered consciousness or during sedation or in alcoholics.^(1,2,3,5,6,7,8,9,10) Tamura et al(1996) in a survey reported 3.6-27.7% of the ingested foreign bodies were dental in origin.⁽⁵⁾ In the data provided by G Susini et al, endodontic instruments represent 18% of ingested items with a frequency of 0.12 per100, 000 root canal treatments.^(1,7) Although rare, ingestion or inhalation of endodontic instrument during dental treatment can result in adverse reactions leading to anxiety and sometimes legal problems.^(11, 12) The use of rubber dam is of paramount importance in practicing endodontic but as reported by various researchers of different countries, treatments are carried out routinely without the application of rubber dam

especially in pediatric patients.^(10,12,13) The delivery of the oral care in supine position to gain a better access also increases the risk of objects entering the oropharynx.^(5,7,10,14) At present there are no strict and specific guidelines whether the ingested foreign object should be managed conservatively or endoscopically or surgically,⁽⁷⁾ as 80-90% of ingested foreign items will pass through the gastrointestinal tract uneventfully while 10%-20% may require endoscopic removal but only 1% or less may necessitate surgical intervention.^(1,2,5,6,11,12)

When an accidental ingestion occurs during the dental treatment, the dental practitioner should have the basic knowledge about the diagnostic procedure, complications involved, methods of retrieval as well as the ability to reassure and immediately escort to medical facilities for appropriate management regardless of how well the patient appears.^(3,5,7,12)

This article presents the management of ingestion of an endodontic K-file by a 3year old child while undergoing treatment by a general practitioner without the application of a rubber dam.

Case Report

A 3 year old, male patient was referred to the department of Pediatric & Preventive dentistry, following an accidental ingestion of an endodontic instrument, by a general dental practitioner under whom the child was undergoing RCT in relation to 54. The parents of the child were acutely anxious as accidental slippage of an instrument had occurred due to patient's uncontrolled movement during the treatment. The dentist was performing the root canal therapy without the rubber dam isolation and had made attempt to retrieve the K-file that had accidentally fallen in child's oropharynx, but was unsuccessful. As the instrument

was either swallowed or aspirated; hence the patient was escorted to the faculty of Dentistry for the management. When presented in the department, the child appeared to be fine and playful with normal breathing and no signs of abdominal pain and did not complain of any discomfort or uneasiness in the throat during the swallowing of food. The patient was immediately referred to an ENT and a chest X-ray PA-view was done to rule out aspiration of file. (Fig. 1) ENT assessment was found to be normal suggesting the passage of the endodontic file into GI tract and therefore ruling out the suspicion of aspiration of the instrument in the airway. Once ingestion of instrument was confirmed, a anteroposterior radiograph of abdominal cavity was taken (in supine position), which demonstrated the presence of a sharp radio-opaque, endodontic file like instrument located in the abdominal cavity.(Fig. 2) Since the patient was asymptomatic, so the 'wait and watch' approach was preferred by the general surgeon rather than endoscopic retrieval. The parents were assured and instructed to give normal and fibre rich diet to the child and examine the stools for the excretion of the instrument. The child was recalled after 2-3 days for evaluation. Parents reported on 2nd day with an unbroken and intact 25 no. endodontic K-file of 21 mm length, finally retrieved from the stool. (Fig. 3) A confirmatory repeat X-ray of abdominal area was taken which did not reveal any foreign body in the GI tract suggesting the complete passage of the ingested dental instrument with no clinical evidence of intestinal obstruction or perforation. (Fig. 4)

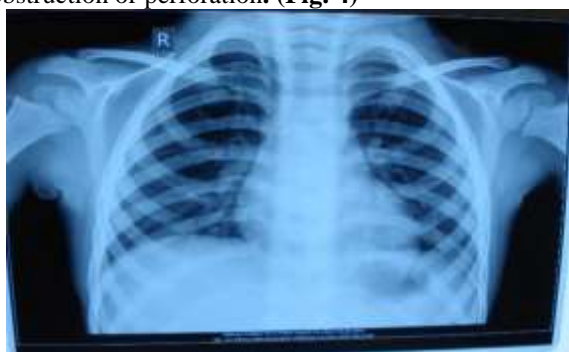

Fig. 1: Posterior-anterior Radiograph of the Chest Region Showing Clear Field

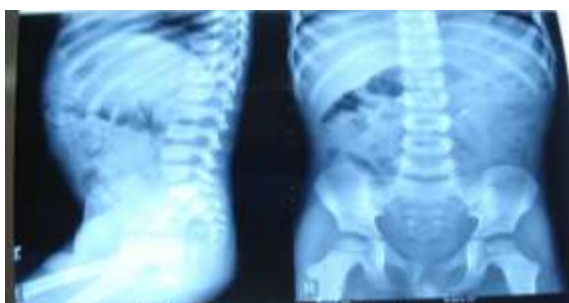


Fig. 2: Anteroposterior and Lateral Views of Abdomen Showing the Endodontic File in Intestinal Loop of the GI Tract

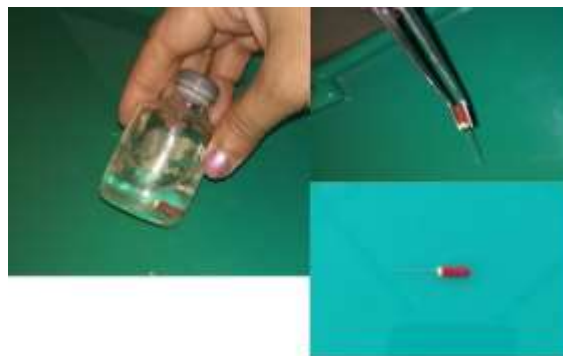

Fig. 3: Retrieved 25 no. Endodontic K-file of 21mm length, intact and unbroken

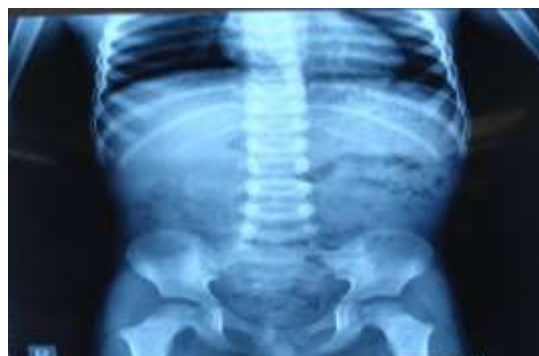

Fig. 4: Anteroposterior X-Ray of Abdomen Showing Clear View; No Evidence of the Endodontic File

Discussion

Any patient can swallow or aspirate a foreign objects and the frequency is higher in children especially below 3 years.^(2,5,6,7,10) The ingestion and aspiration of dental based foreign bodies during the dental procedures account for the second most cause of accidental ingestion/inhalation in United States, as most of the dentistry is practiced in supine position coupled with not using or incorrectly applying rubber dam in routine practice.⁽¹⁴⁾ But there is no consensus regarding the ideal position of treating a patient to minimise the risks of ingestion or aspiration, as accidents are possible in any positions.^(5,10) The incidence of unintentional swallowing of endodontic instruments is 0.12 per 100,000 of root canal treatments and represents 18% percentage of all ingested dental items.^(7,13) Although rare, ingestion of endodontic instruments during treatment without using rubber dam can result in clinical complication and such mishaps usually occur when treating posterior mandibular teeth.⁽¹¹⁾ The most important feature of managing the ingestion of a foreign body depends upon the patient's characteristics, and type and location of the object ingested,^(3,15) as sharp pointed elongated objects may fail to pass the curves of intestine and may cause perforations or impaction.⁽³⁾ There are evidences in literature which supports that majority of the foreign bodies that enters the gastro intestinal tract will pass spontaneously within 3-4 days

while 10-20% of cases will require non-surgical intervention and 1% may require surgery.^(2,4,5,6,7,9,11,12,15,16,17) The most important criterion in choosing the best approach is that it should be less invasive and the safest for the patient.⁽¹⁵⁾ In cases of sharp objects like endodontic files which pass through the abdominal cavity, careful radiographic monitoring is followed till 72 hours for spontaneous passage; if it fails or patient develops symptoms of systemic sepsis, or perforations then laparotomy or open surgery should be carried out.^(7,9,11,12,16,17) A post-operative radiograph should be taken to confirm the complete removal of the ingested or aspirated foreign body.⁽¹⁾ Fortunately in this case the passage of endodontic instrument was asymptomatic and atraumatic and very rapid as patient reported with intact expelled instrument on 2nd day of ingestion and the post-operative X ray of the abdomen showed no evidence of the ingested K-file.

If an accidental slippage of a dental instrument occurs into the patient's mouth, the clinician should remain calm and make the patient's head tilted in the reverse Trendelenburg position or if in supine position, turned to one side to prevent the falling of the instrument into the oropharynx and at the same time ask the patient to cough.^(1,3,10) In case of unsuccessful retrieval, the patient should be reassured and clinically examined and immediately referred to the appropriate medical professional for the necessary management.^(1,7,10) Early detection of an aspirated and ingested foreign body facilitates timely management⁽¹⁾ Majority of the ingested dental instruments are radiopaque in nature and can be identified with plain radiographs, ultrasound scanning, computerised tomography and magnetic resonance imaging.^(2,9,11,17) While radiolucent ingested foreign bodies can be detected radiographically if the patient is made to eat cotton wool pellets mixed with small amount of barium sulphate suspension which forms a radiopaque bolus around the ingested object.⁽¹⁰⁾ Additionally a chest PA radiograph is taken to rule out aspiration into the trachea bronchial tree.⁽²⁾ In this case the patient had ingested the K-file and was asymptomatic. The instrument was visible with plain radiographs and found to be located in the gastrointestinal tract. Out of all the considerable treatment modalities available, the option of non-operative follow up was the reasonable decision made by the surgeon in our case. The patient was thus treated conservatively and strictly monitored. The child was put on high bulk and fibre rich diet, laxatives were avoided and advised periodic stool inspection. There are no scientific evidences available in medical literature to prove the benefits of any special diet and purgatives are usually not prescribed as these increases the peristaltic contractions which will enhance the risks of intestinal perforations.⁽³⁾

The attending specialist should not rush to any surgical procedures urgently during the ingestion of foreign body because in some cases "wait and close

observation" may solve the problem without any complication even for a sharp foreign body like endodontic file^(1,6,15) like in our case.

Ingestion of dental instruments during root canal treatment can be easily prevented by the universal use of rubber dam isolation, proper positioning of the patient and the operator, and adequate lighting during the procedure. Use of gauze throat screens distal to the working area while doing treatment can also prevent ingestion or aspiration of accidentally slipped instruments. Dentist should prefer rotary files that are secured in the hand piece over hand files especially in pediatric patients, and maintain a dry field with a help of high speed evacuation. Tying of hand endodontic files, crowns, band, with a ligature or 18 inches long floss can improve the gripping and reduce the slippage and help in easy retrieval in case of accidental ingestion or aspiration.^(1,7,8,11,12,13,14,16,17) The dental instruments like burs or files should be examined periodically and carefully for signs of wear and replaced regularly. Dental burs and mouth mirrors should be properly seated and screwed while in use. The retrieved instruments and their fragments should be matched with fresh and intact ones to ensure that all pieces have been recovered.⁽¹⁾

Conclusion

Sometimes it is difficult to avoid accidental ingestion and aspiration of dental instruments during dental procedures, especially in children. While these events occur infrequently in dentistry but the potential morbidity with a single incident is too high to ignore. Hence general practitioners and Pedodontists should be aware of the associated risks of such endodontic mishaps and the importance of timely and appropriate management.

References

1. Rui Hou et al. Thorough documentation of the accidental aspiration and ingestion of foreign objects during dental procedure is necessary: Review and Analysis of 617 cases; *Head & Face Medicine* (2016) 12:23.
2. Chin-lung Kuo. Management Strategies for Ingestion of Foreign Objects in the Laryngopharynx. *Jour Oto and Rec Surg*; 2015, Vol 1 (2).
3. Zitzmann NU, Elsasser S, Fried R, Marinello CP. Foreign body ingestion and aspiration. *Oral Surg Oral Med Oral Pathol Oral Radiol Endod* 1999;88(6):657-60.
4. Yuh Baba, Yasumasa Kato. Concomitant Crown and Piece of Tray Ingestion: A Case Report *J Med Cases*. 2016;7(11):478-479.
5. Amey Panse, Prasad Jathar, Deepak Mehta. Accidental Ingestion of Instruments in Pediatric Dental Patients: Report of Three Cases *Journal of Dental & Allied Sciences* 2012;1(2):79-81.
6. Pavlidis TE, Marakis GN, Triantafyllou A, Psarras K, Kontoulis TM, AK. Management of ingested foreign bodies: How justifiable is a waiting policy? *Surg Laparosc Endosc Percutan Tech* 2008;18:286-7.
7. Venkataraghavan K. et al. Accidental Ingestion of Foreign Object: Systematic Review, Recommendations

- and Report of a Case. The Saudi Dental Journal,2011,23,177-181.
8. Tiwana KK, Morton T, Tiwana PS. Aspiration and ingestion in dental practice: a 10-year institutional review. J Am Dent Assoc. 2004;135(9):1287-1291.
 9. Dhandapani RG, Kumar S, O'Donnell ME, McNaboe T, Cranley B, Blake G. Dental root canal treatment complicated by foreign body ingestion: A case report. Cases J 2009;2:117.
 10. Tulika Tripathi, Priyank Rai, Harpreet Singh. Foreign body ingestion of orthodontic origin; Am J Orthod Dentofacial Orthop 2011;139:279-83.
 11. Kuo S., C., Chen Y.-L. Accidental swallowing of an endodontic file. International Endodontic Journal, 41, 617-622, 2008.
 12. Bondarde P, Naik A, Patil S, Shah PH. Accidental Ingestion and uneventful retrieval of an endodontic file in a 4 year old child: A case report. J Int Oral Health 2015;7(Suppl 2):74-76.
 13. Susini G, Pommel L, Camps J. Accidental ingestion and aspiration of root canal instruments and other dental foreign bodies in a French population. Int Endod J 2007;40:585-9.
 14. S Thusu, S Panesar, R Bedi. Patient Safety In Dentistry-state of play as revealed by national database of errors. British Dental Journal;213;E3:2012.
 15. A. Kamali Polat, A.V. Polat, Z. Erzurumlu, P. Celenk. An Accidentally Ingested Mandibular Prosthesis was Exempt from Surgery; Chirurgia (2012) 107: No. 6, November – December; 805-808.
 16. Roopa KB, Poornima P, Pathak S, Balehosur DV. Foreign body ingestion in a pediatric patient: Report of case and review of ingestion\aspiration incident management. Int Dent Med J Adv Res 2015;1:1-3.
 17. Bhatnagar, *et al.*: Foreign Body Ingestion in dental practice; JISPPD;Oct - Dec 2011; Vol 29(4):336-38.